

# **Varicous Veins and Venous Thrombosis**

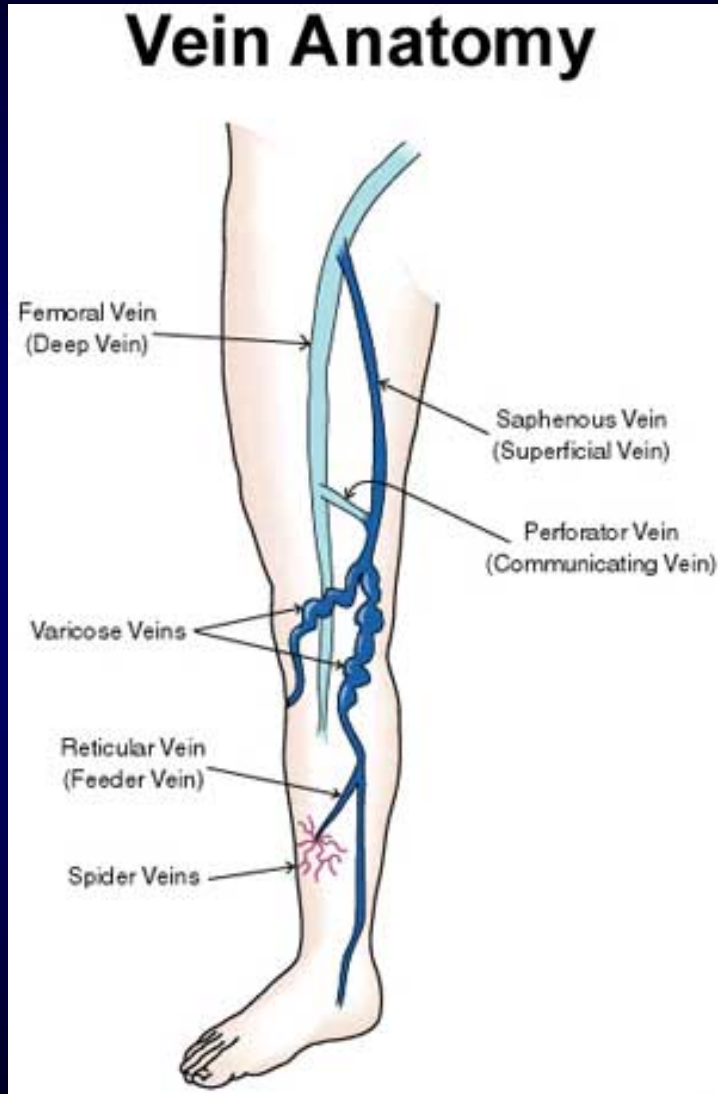
**Catedra de Chirurgie nr.1 „Nicolae Anestiadi”**

**Varicose veins affect between 10% and 25% of the UK adult population.**

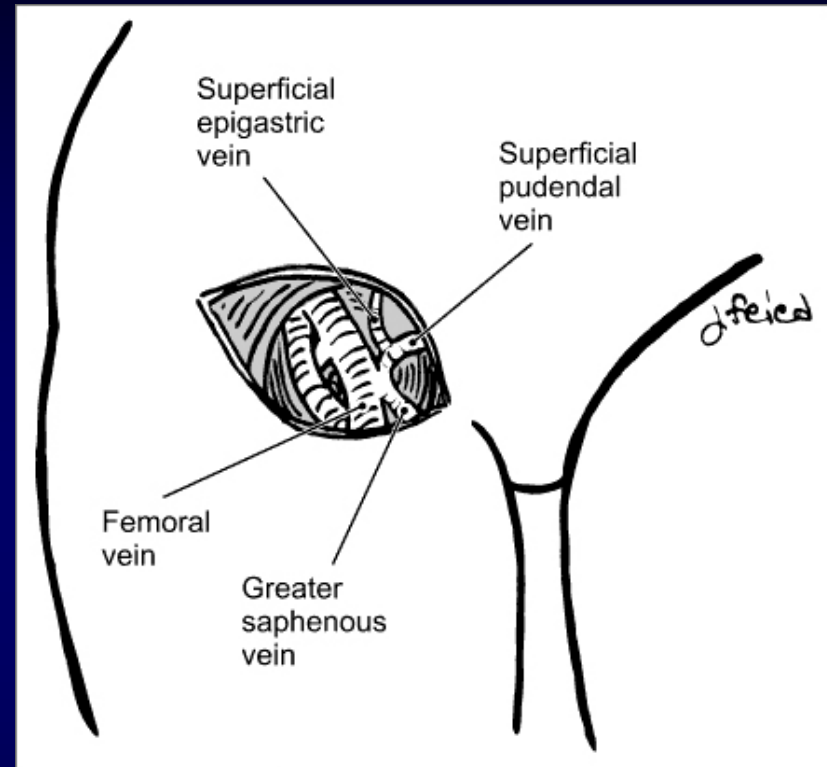
**Callam M. Epidemiology of varicose veins. Br J Surg 1994; 81: 167-73.**

**Varicose veins are simply dilated, tortuous veins of the subcutaneous/superficial venous system.**

# Anatomy

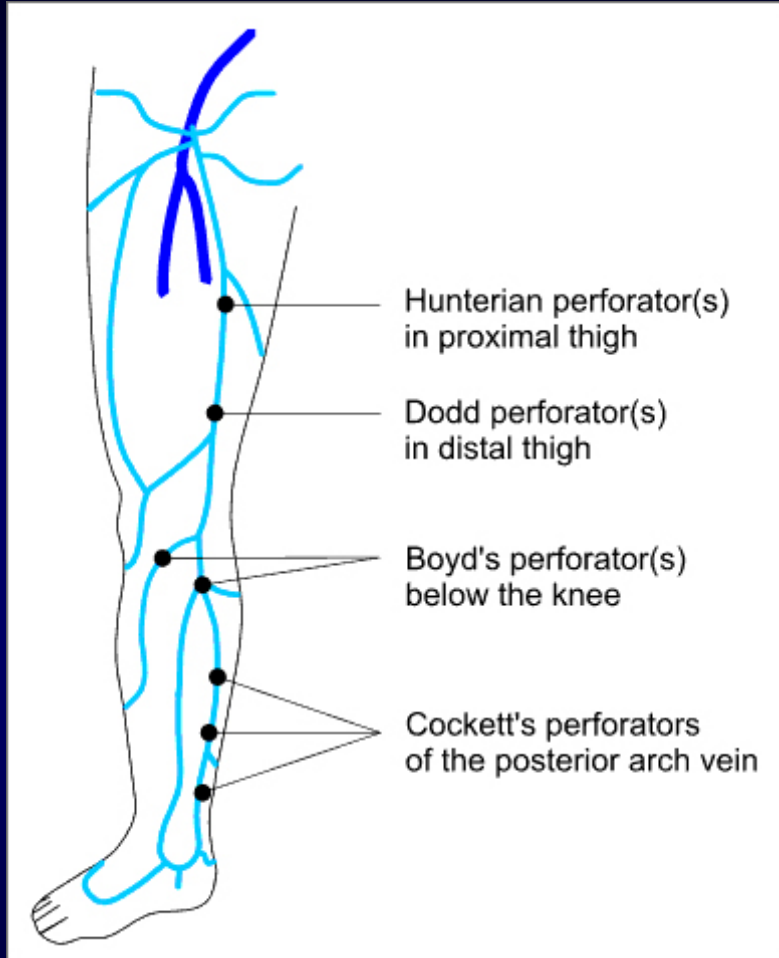


Superficial venous system



The superficial system is found above the deep fascia of the lower extremity, within the subcutaneous tissue. Many superficial veins exist, but they all drain into the 2 largest, the greater saphenous vein (GSV) and the short saphenous vein (SSV), formerly called the lesser saphenous vein.

# Anatomy



The superficial venous system is connected to the deep system at a number of the following locations:

## Perforator veins

These veins transverse the deep fascia of the lower extremity. A number of named perforators are found at the thigh, knee, and leg.

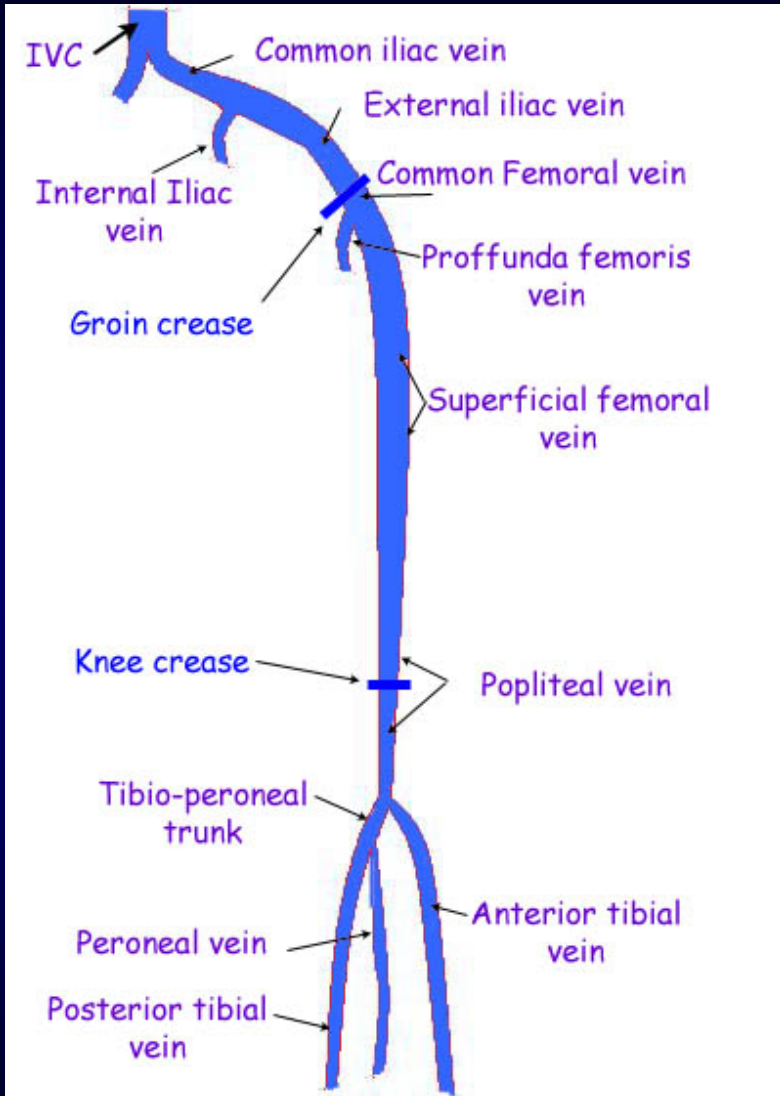
## Saphenofemoral junction (SFJ)

This is located proximally at the groin where the GSV meets the femoral vein, as depicted in the images below.

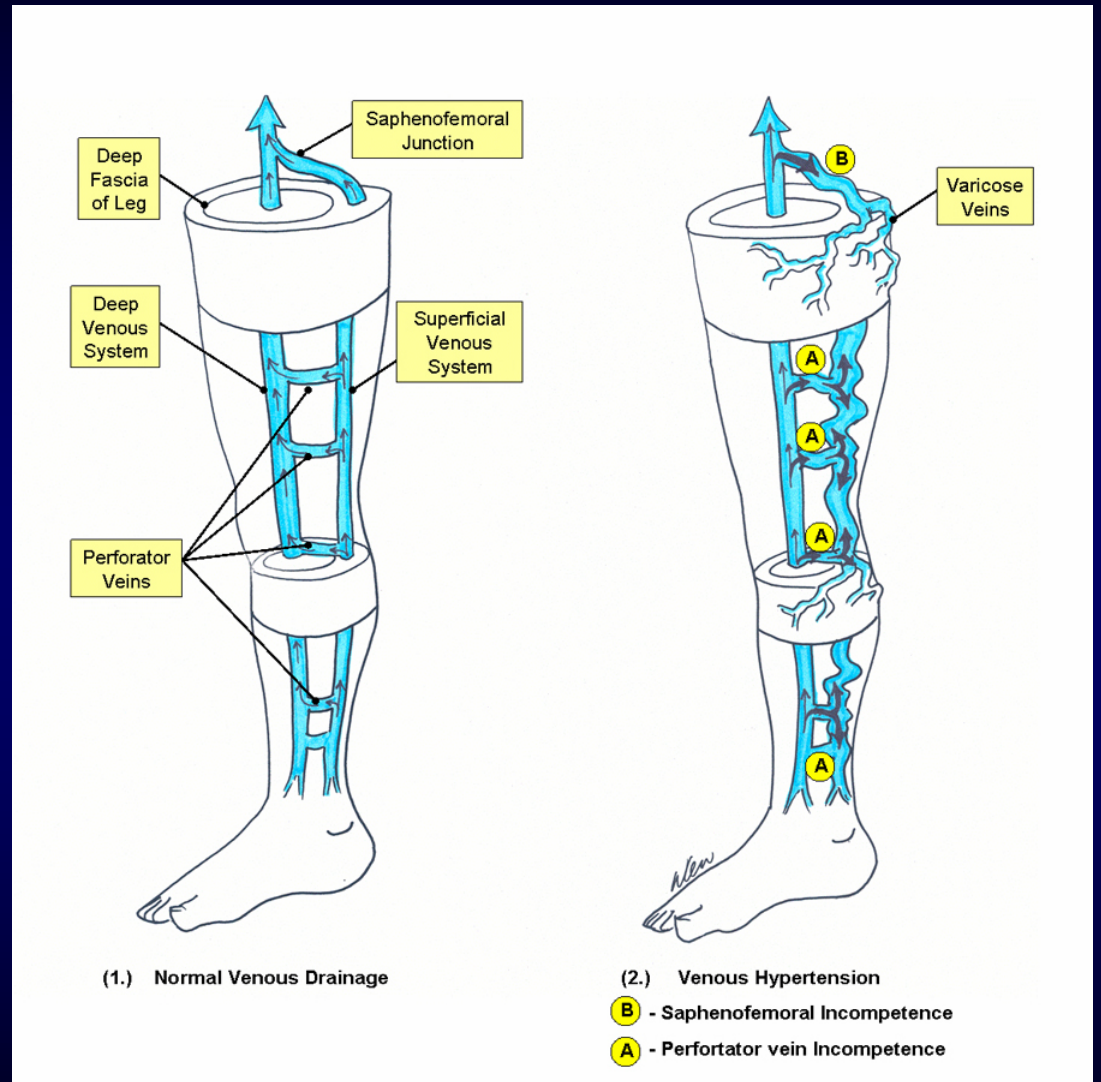
## Saphenopopliteal junction (SPJ)

This is located behind the knee where the SSV joins with the popliteal vein.

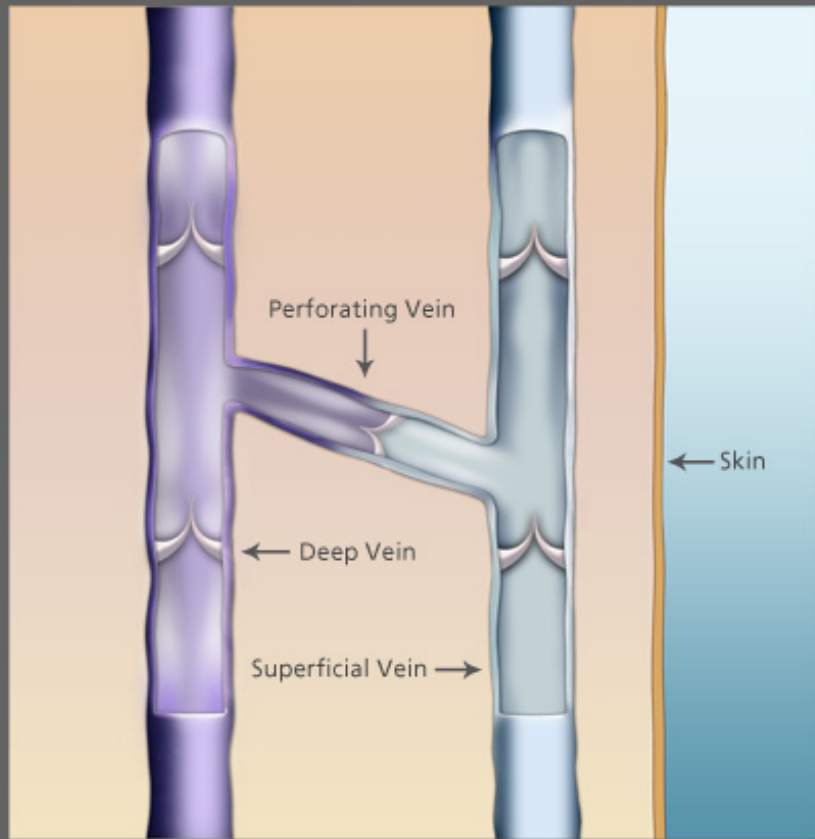
# Anatomy



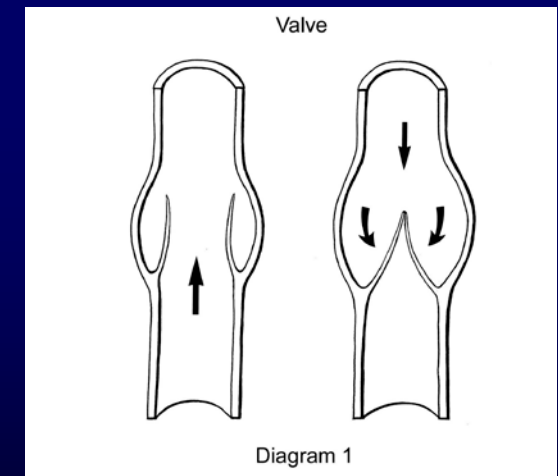
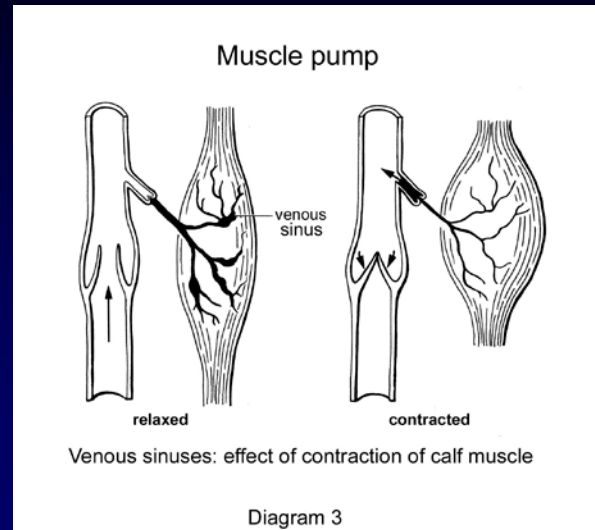
Deep venous system



# Pathophysiology

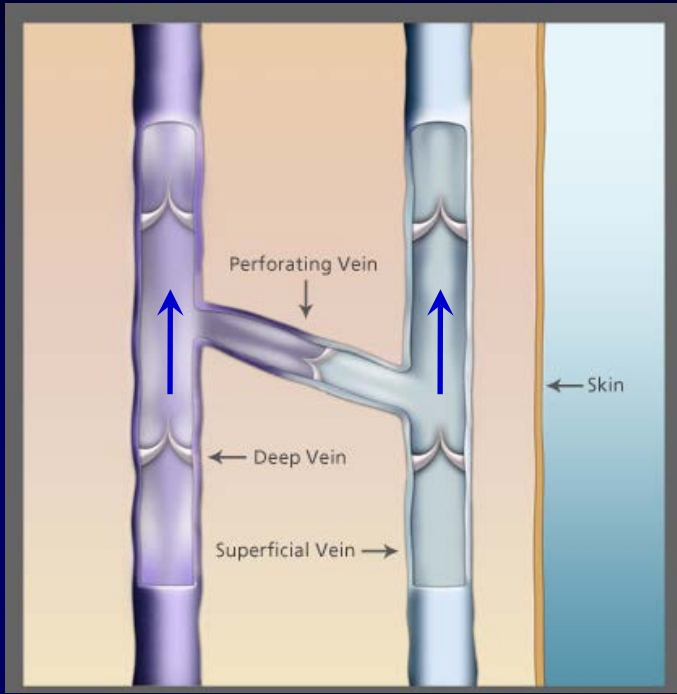


Perforating veins connect the deep system with the superficial system

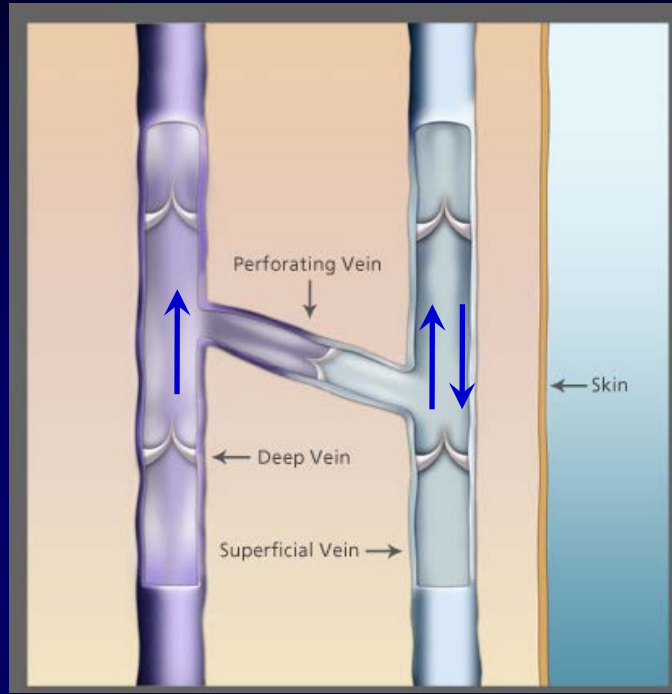


Many superficial veins exist, but they all drain into the 2 largest, the greater saphenous vein (GSV) and the short saphenous vein (SSV), formerly called the lesser saphenous vein.

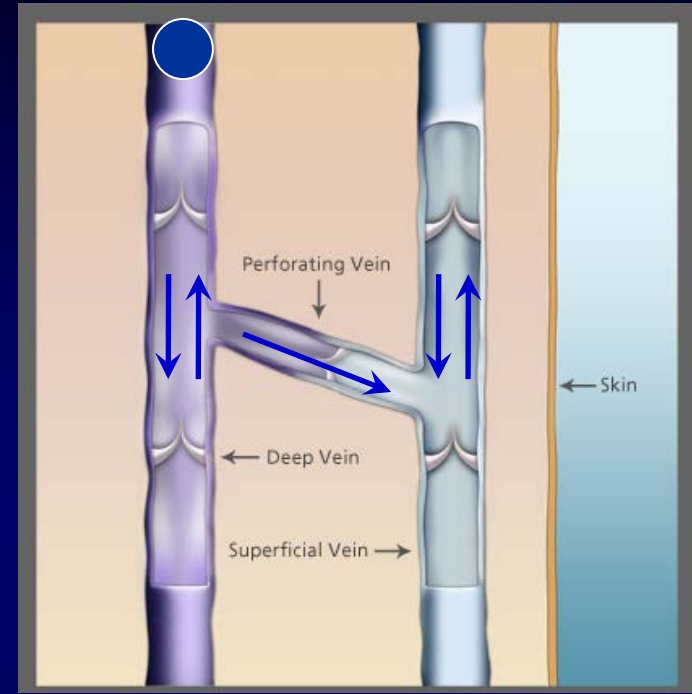
# Pathophysiology



**Norma**



**Primary varicose veins**



**Secondary varicose veins**

# Classification

## Primary

Valvular insufficiency of the superficial veins, most commonly at the saphenofemoral junction.

## Secondary

Mainly caused by deep vein thrombosis (DVT) that leads to chronic deep venous obstruction or valvular insufficiency. Long-term clinical sequelae from this have been called the *postthrombotic syndrome*.

*Catheter*-associated DVTs are also included.

*Pregnancy*-induced and progesterone-induced venous wall and valve weakness worsened by expanded circulating blood volume and enlarged uterus compresses the inferior vena cava and venous return from the lower extremities.

## *Trauma*

## Congenital

This includes any venous malformations.

Klippel-Trenaunay variants

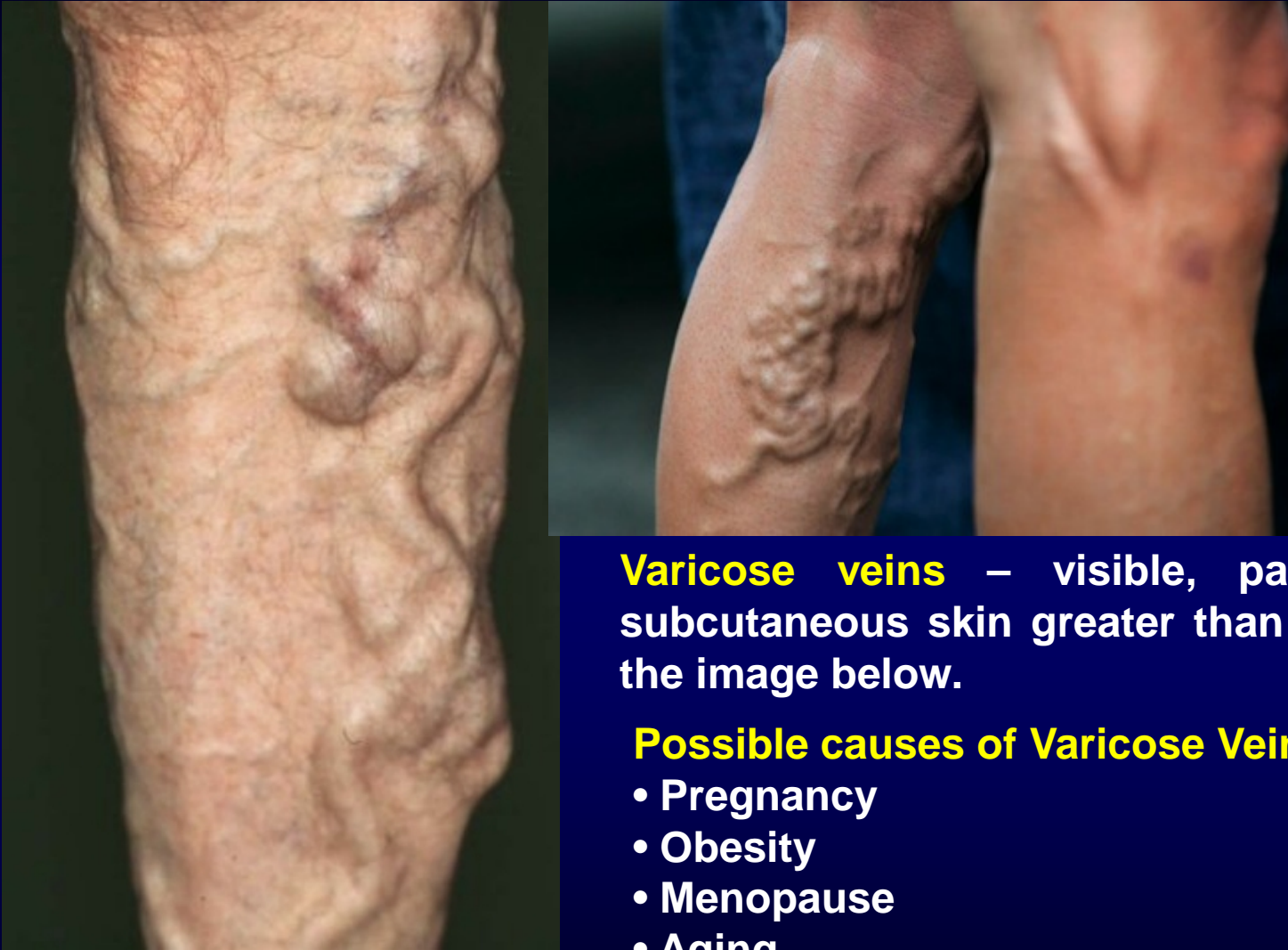Avalvulia



## **Venous history**

- 1) History of venous insufficiency (eg, date of onset of visible abnormal vessels, date of onset of any symptoms, any known prior venous diagnoses, any history of pregnancy-related varices)**
- 2) Presence or absence of predisposing factors (eg, heredity, trauma to the legs, occupational prolonged standing, sports participation)**
- 3) History of edema (eg, date of onset, predisposing factors, site, intensity, hardness, modification after a night's rest)**
- 4) History of any prior evaluation of or treatment for venous disease (eg, medications, injections, surgery, compression)**
- 5) History of superficial or deep thrombophlebitis (eg, date of onset, site, predisposing factors, sequelae)**
- 6) History of any other vascular disease (eg, peripheral arterial disease, coronary artery disease, lymphedema, lymphangitis)**
- 7) Family history of vascular disease of any type**

## Definition

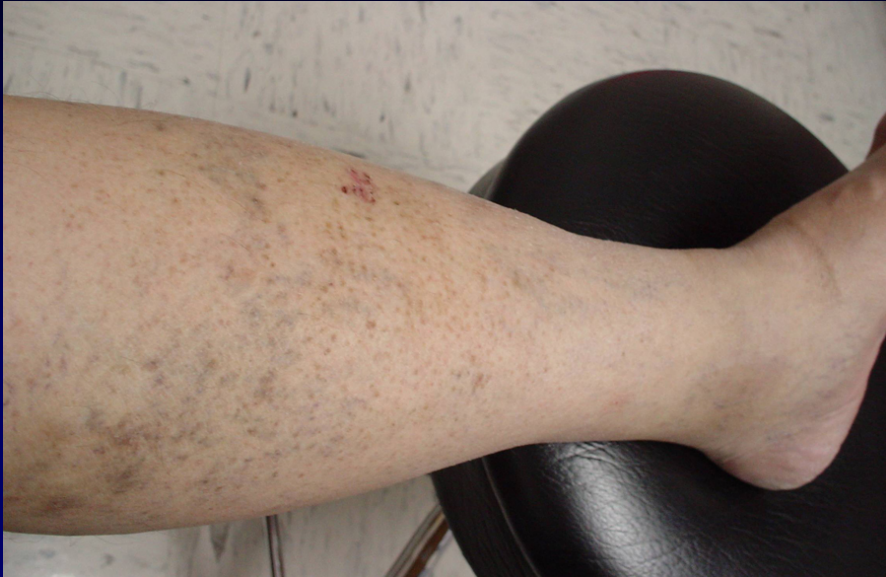

**Varicose veins** – visible, palpable veins in the subcutaneous skin greater than 3 mm, as depicted in the image below.

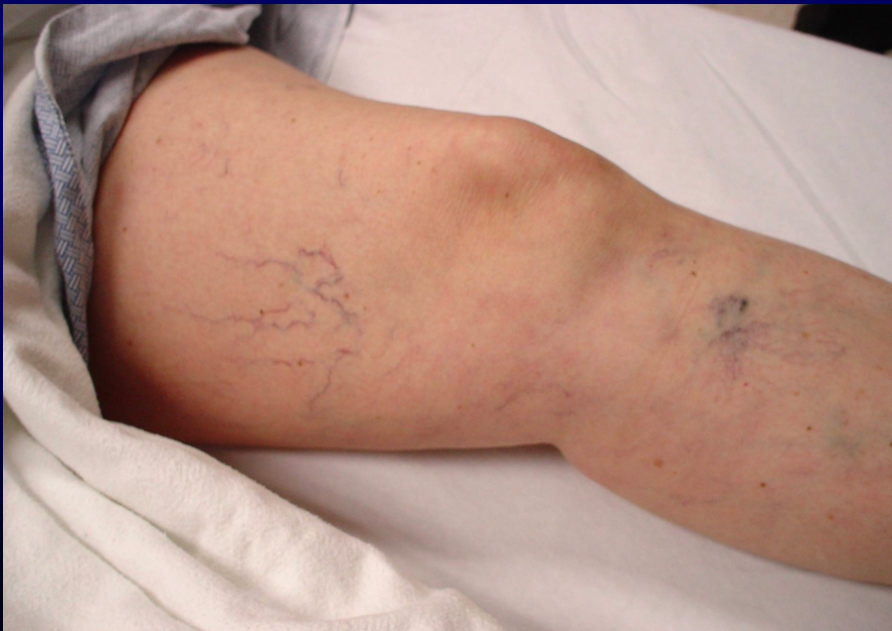### **Possible causes of Varicose Veins**

- Pregnancy
- Obesity
- Menopause
- Aging
- Prolonged standing
- Leg injury

## Definition



**Reticular veins** (also called blue veins, subdermal varices, and venulectasias) – Visible, dilated bluish subdermal, nonpalpable veins 1-3 mm.



**Telangiectases** (also called spider veins, hyphen webs, and thread veins) – Dilated intradermal venules greater than 1 mm in diameter.

# **The Clinical Etiologic Anatomic Pathophysiological (CEAP) classification of chronic venous disease**

<b>CEAP clinical stage</b>	<b>Description</b>
<b>C0</b>	<b>Absence of any signs of venous disease</b>
<b>C1</b>	<b>Reticular veins</b>
<b>C2</b>	<b>Truncal varicose veins</b>
<b>C3</b>	<b>Oedema</b>
<b>C4</b>	<b>Skin changes (pigmentation, lipodermatosclerosis)</b>
<b>C5</b>	<b>Healed ulceration</b>
<b>C6</b>	<b>Open ulceration</b>

**Trendelenburg Test** - Used to distinguish superficial venous reflux from incompetent deep venous valves. The patient's leg is elevated, collapsing the congested superficial veins. The examiner's hand is used to occlude the varicose vein below the point of suspected reflux from the deep system. The patient stands with the occlusion in place. If the distal varicosity remains empty, the entry point into the system has been identified. If rapid filling occurs, some other reflux pathway must be involved.

**Doppler Auscultation** - Can distinguish antegrade from retrograde flow (important as antegrade flow denotes a bypass pathway and therefore is a contraindication for removing the varicosity). The transducer is positioned along the axis of the vein and an augmentation maneuver is performed by compressing and releasing the veins and muscles below the level of the probe. Compression causes forward flow and release causes backward flow. If the valves are competent, blood cannot flow backwards and no Doppler signal is noted.

**The Perthes test** is a clinical test for assessing the patency of the deep femoral vein prior to varicose vein surgery. It is named after German surgeon Georg Perthes.

The limb is elevated and an elastic bandage is applied firmly from the toes to the upper 1/3 of the thigh to obliterate the superficial veins only. With the bandage applied the patient is asked to walk for 5 minutes. If deep system is competent, the blood will go through and back to the heart. If the deep system is incompetent, the patient will feel pain in the leg.

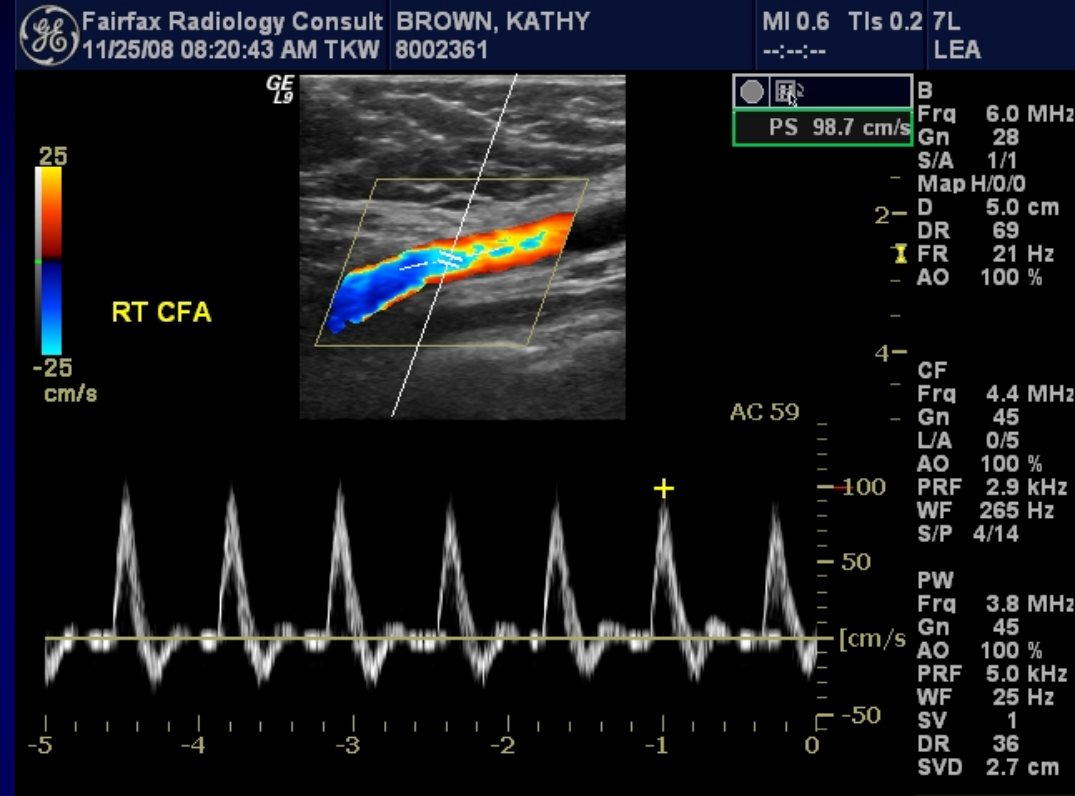
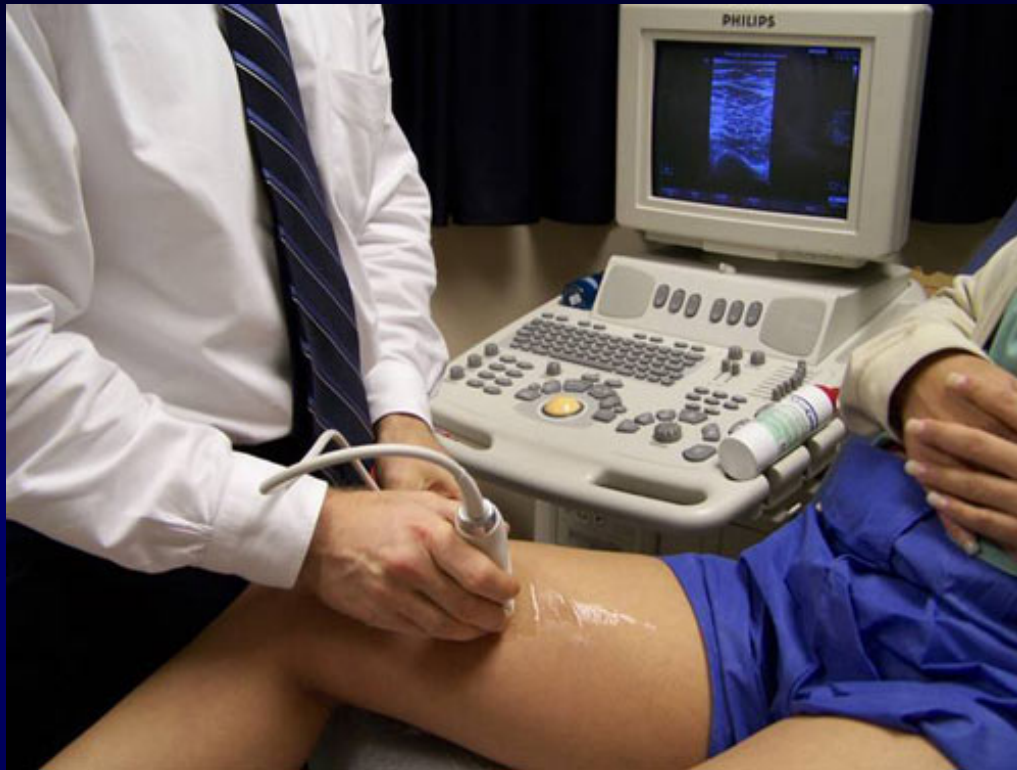This test is sometimes referred to as the Delbet-Mocquot test, named after French physicians Pierre Delbet and Pierre Mocquot.

## **Modified Perthes test**

The test is done by applying a tourniquet at the level of the sapheno-femoral junction to occlude the superficial pathway, and then the patient is asked to move *in situ*. If the deep veins are occluded, the dilated veins increase in prominence and pain occurs.

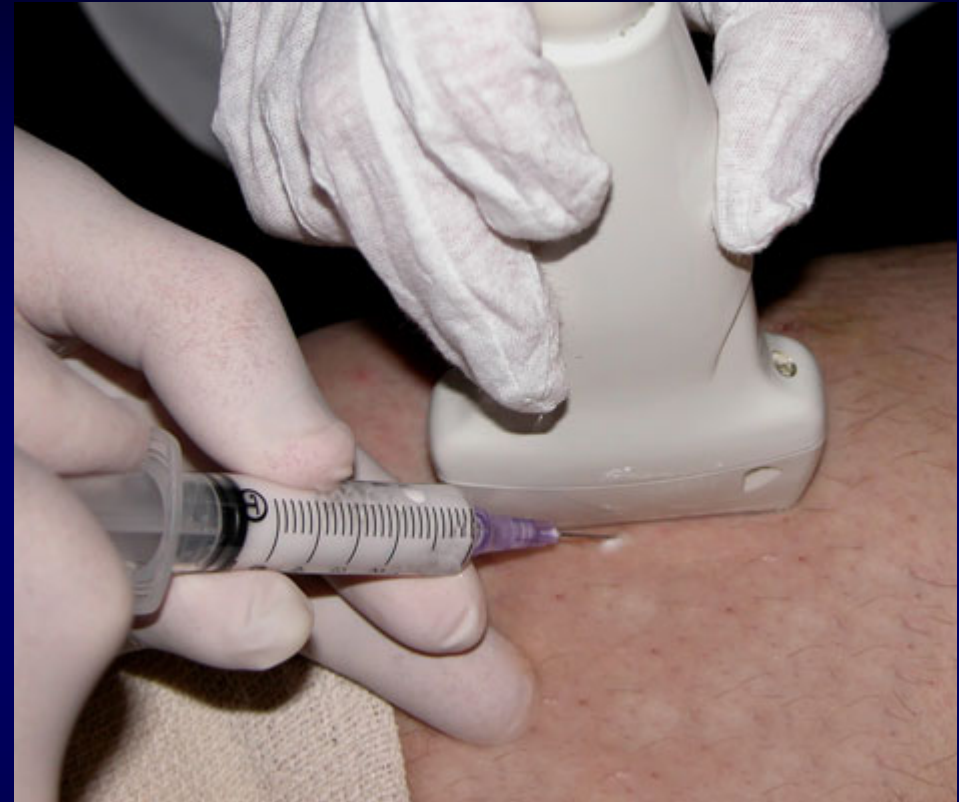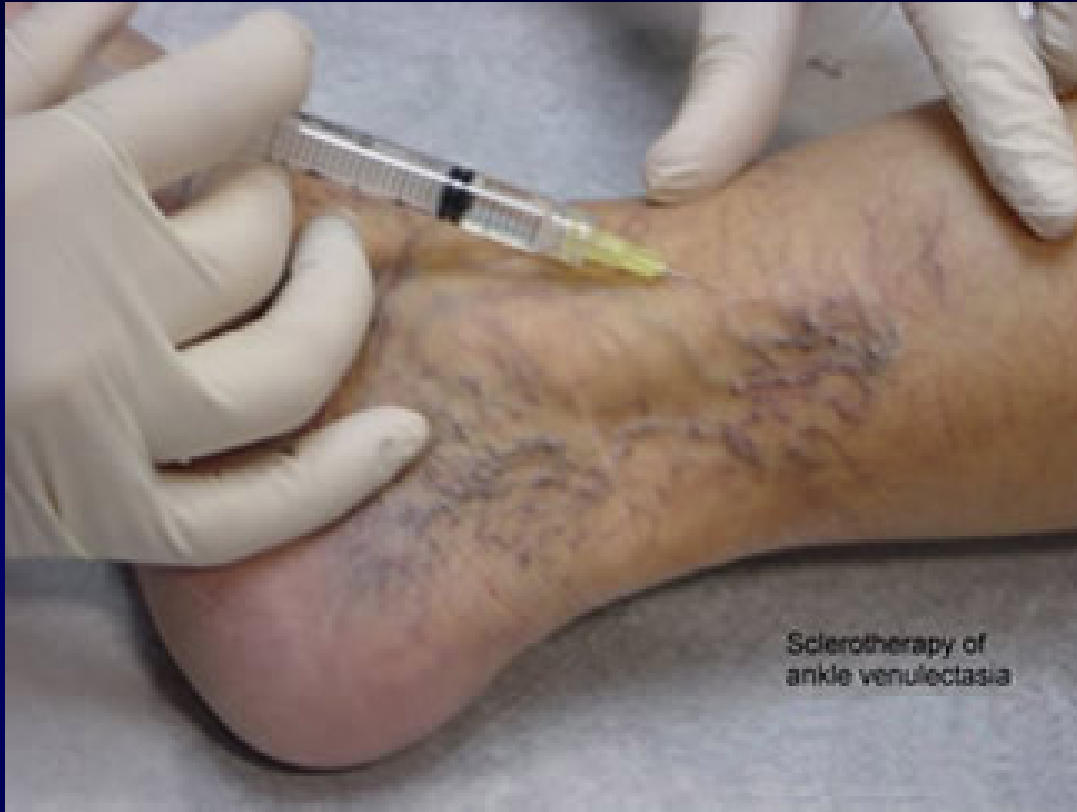This is a better test as it does not depend on patient's pain threshold.

# High-resolution color duplex scanners





## Sclerotherapy

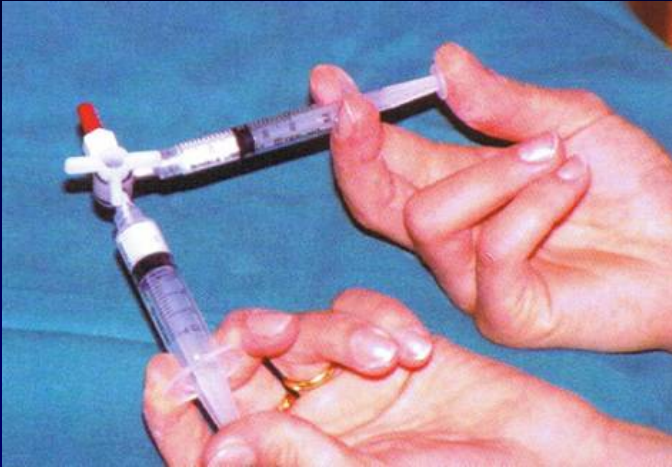

### Sclerosants

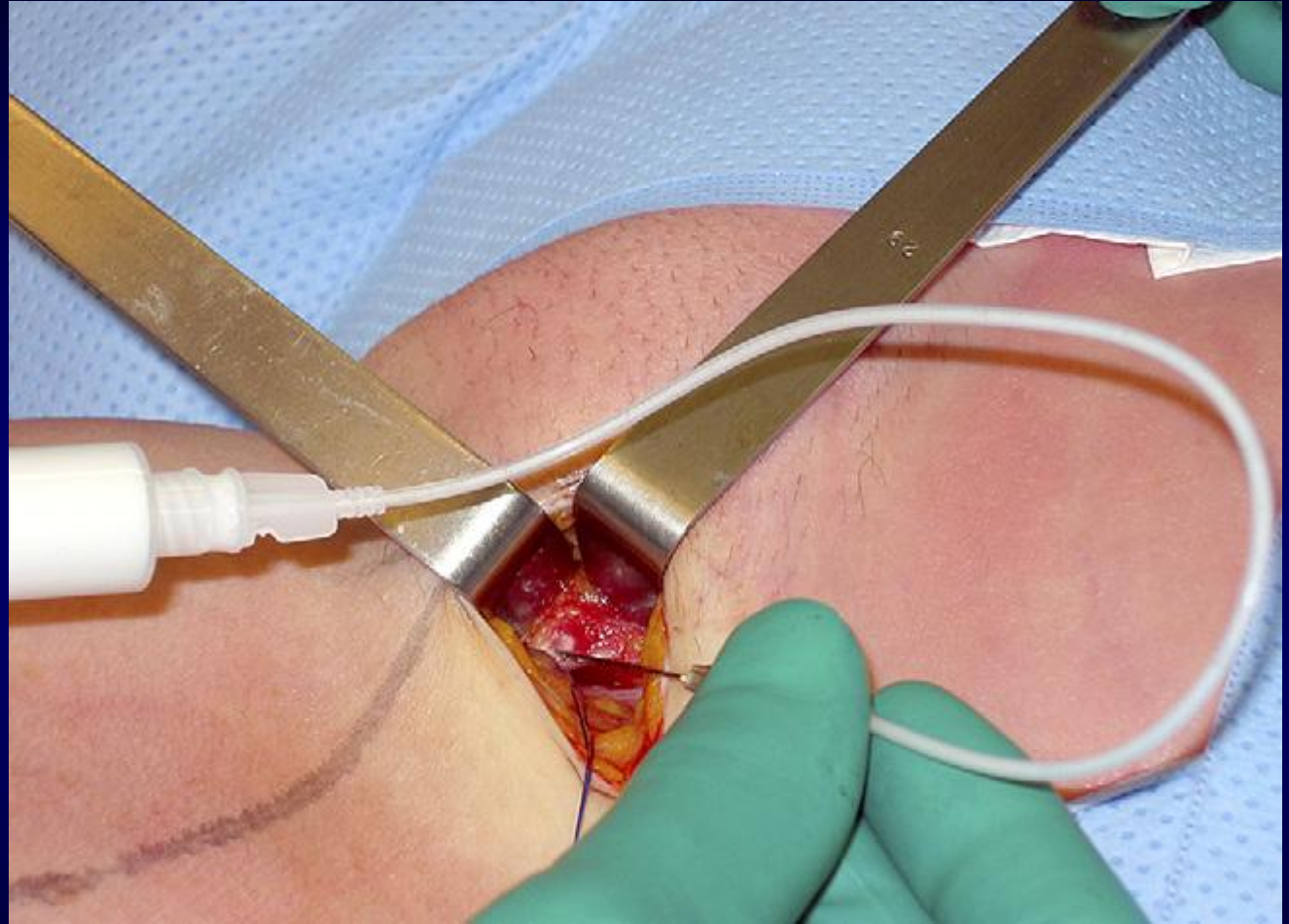
- polidocanol 0.5-3%
- sodium tetradecyl sulphate 1-3%

ultrasound-guided foam sclerotherapy

## Foam Sclerosant

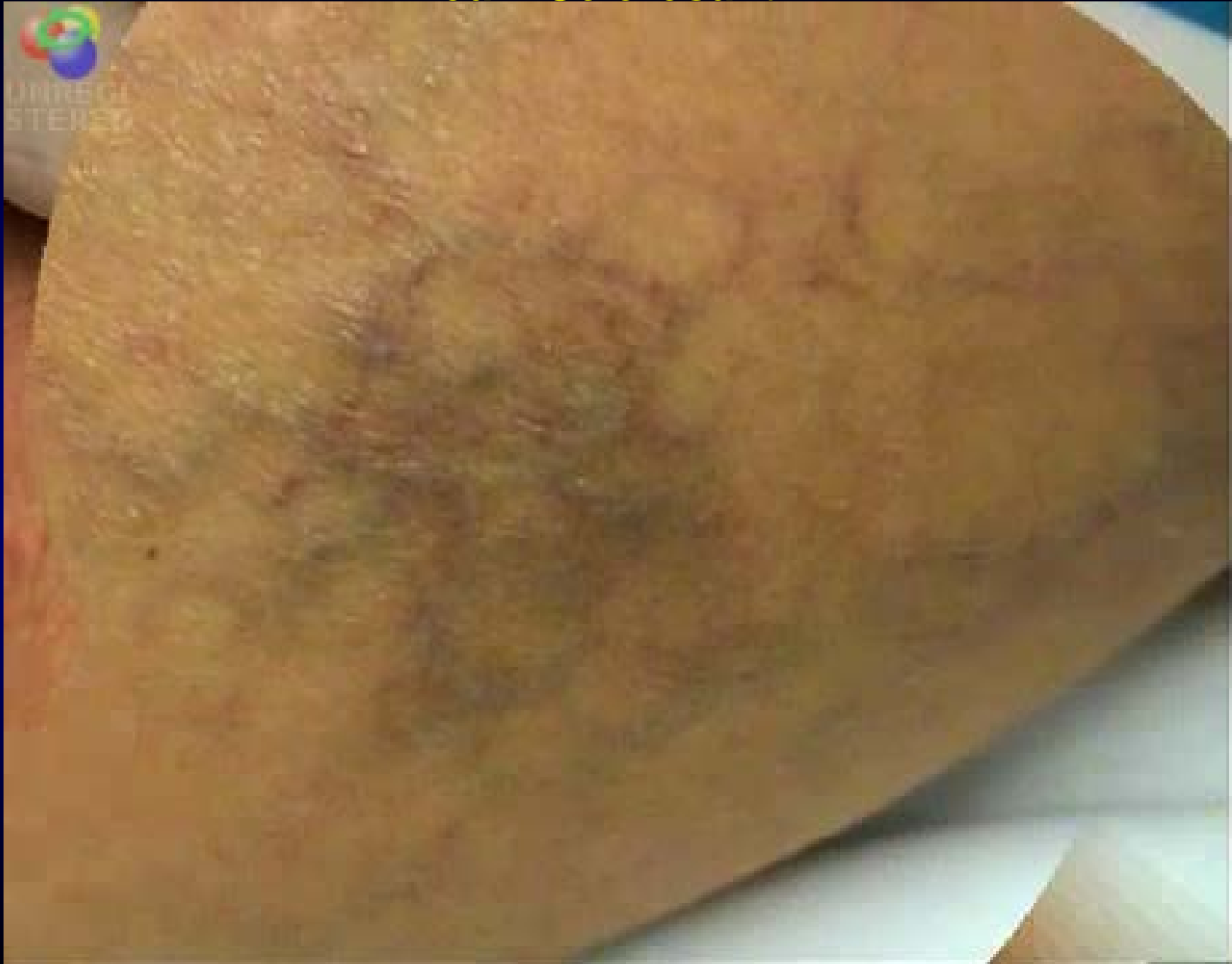

One syringe contains 1 ml of liquid sclerosant and the second syringe contains 4 ml of the gas.



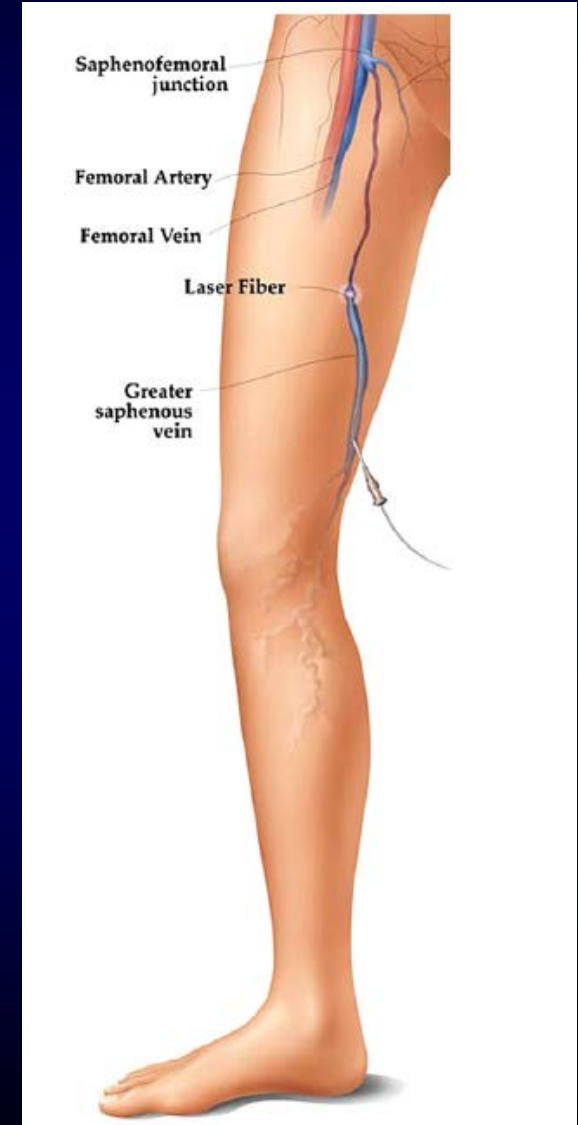
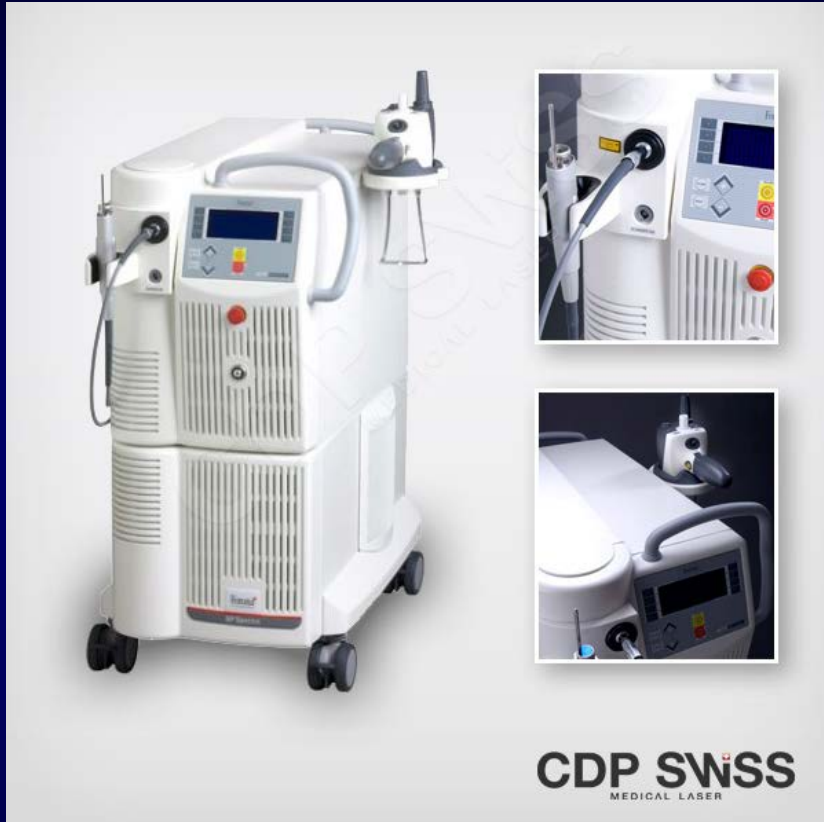Some practitioners apply Class I or II compression stockings over the treated leg. Compression should be applied to the leg for 1-2 weeks.

# Foam Sclerosant



# Endovenous Laser Ablation

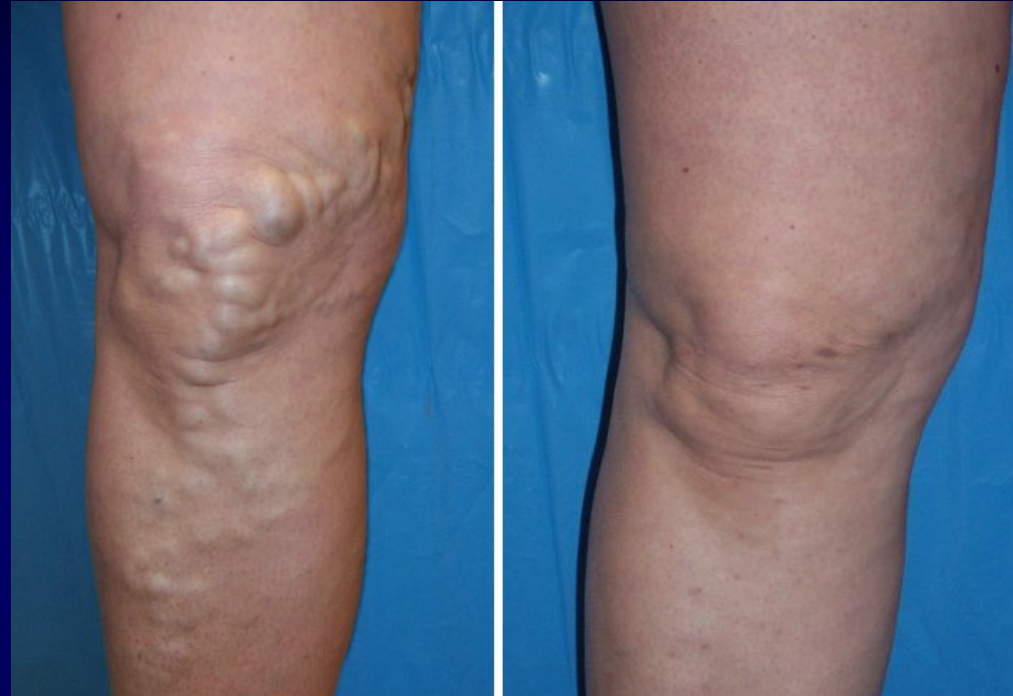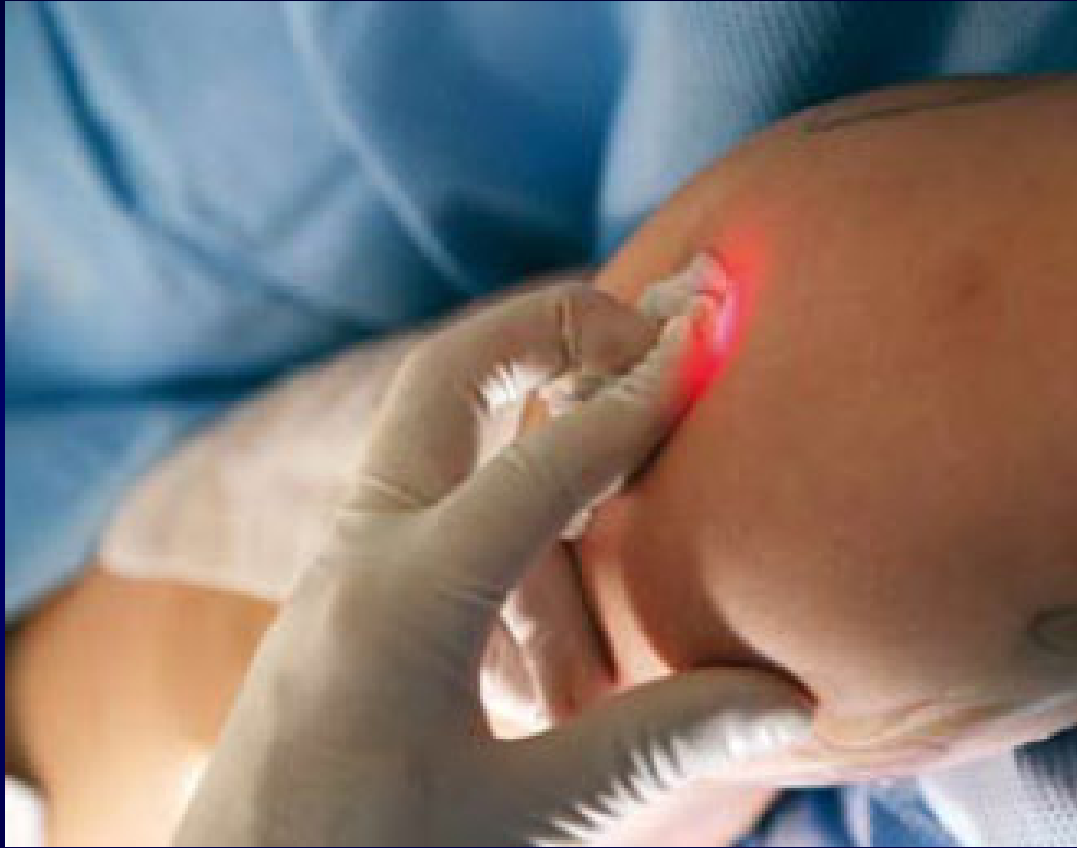Laser (Light Amplification by Stimulated Emission of Radiation)



## Surgical QCW Nd:YAG laser

Haemoglobin maximally absorbs light of the **940 nm** wavelength and this wavelength is theoretically the optimal for EVLA.

# Endovenous Laser Ablation

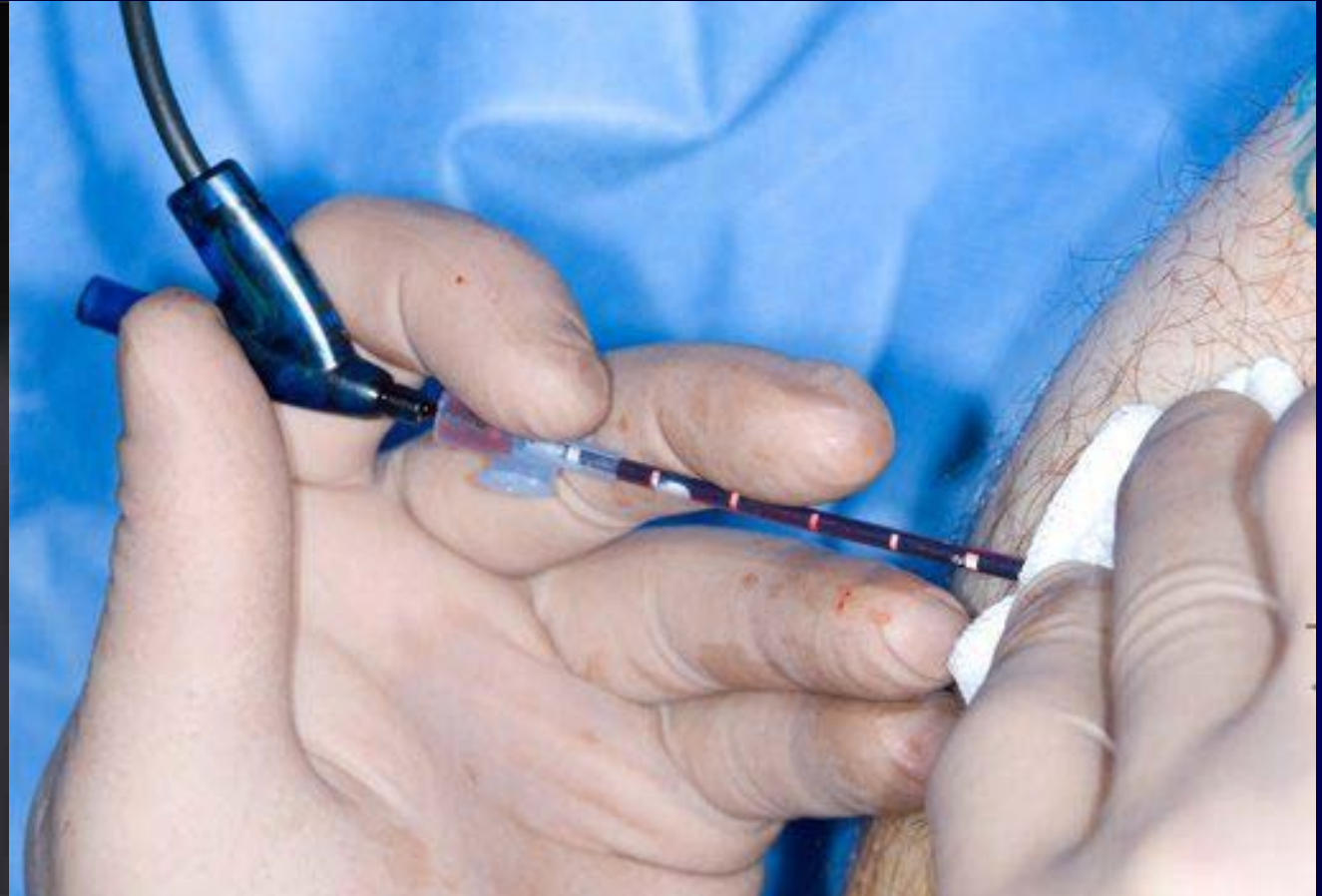
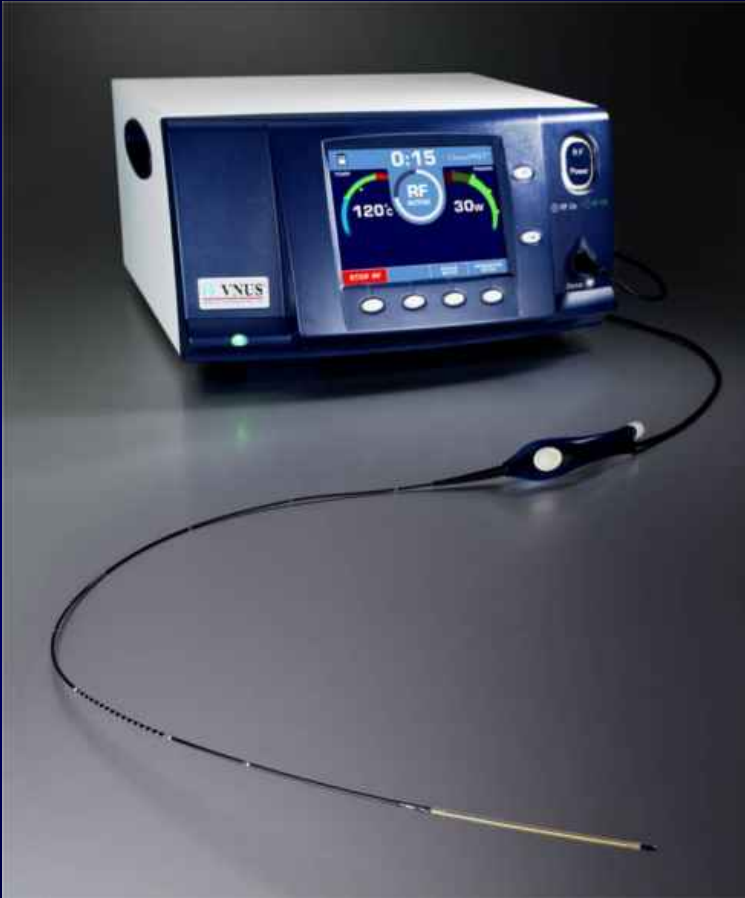

The catheter is then positioned 0.5-1 cm from the saphenofemoral or saphenopopliteal junction under ultrasound guidance; the patient is placed into the Trendelenberg position to empty the veins. Pull-back rates of 1 cm every 5 seconds using 14W power allows for energy delivery of 70 J/cm.

# Endovenous Laser Ablation

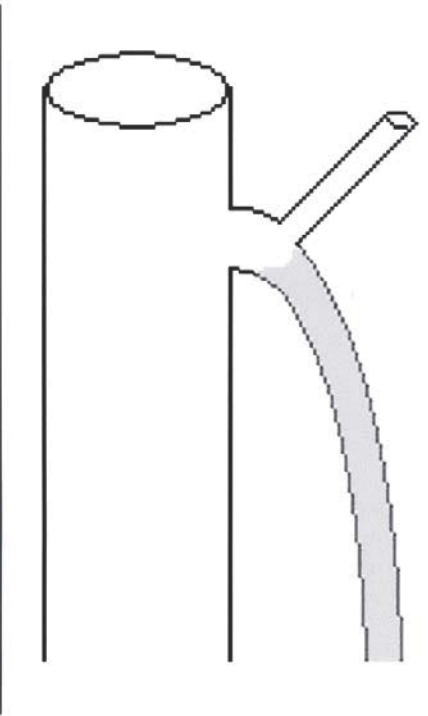
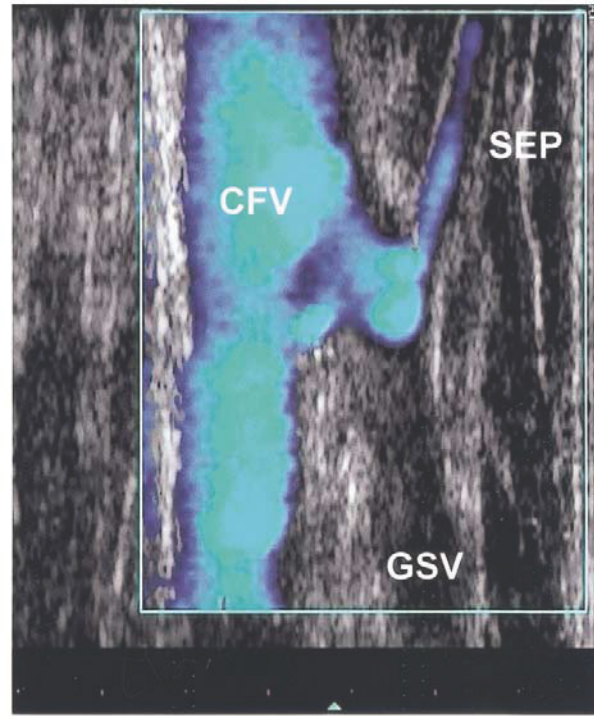
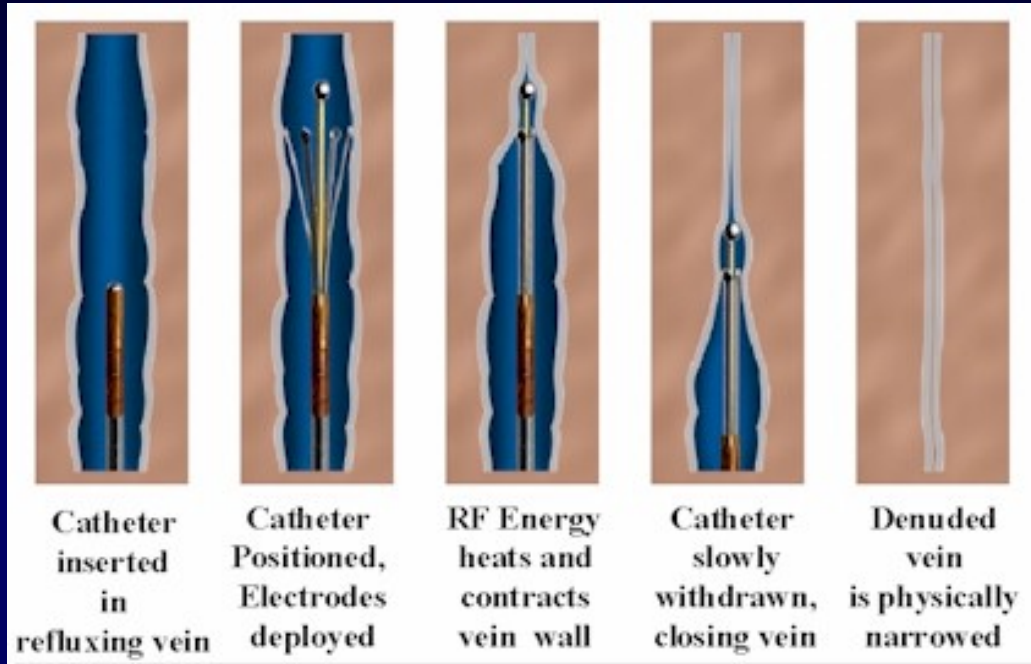


# Radiofrequency ablation (RFA) of the great saphenous vein



Radiofrequency ablation (RFA) of the GSV was introduced as a minimally invasive alternative to stripping, with the aim of interrupting venous flow through the incompetent GSV.

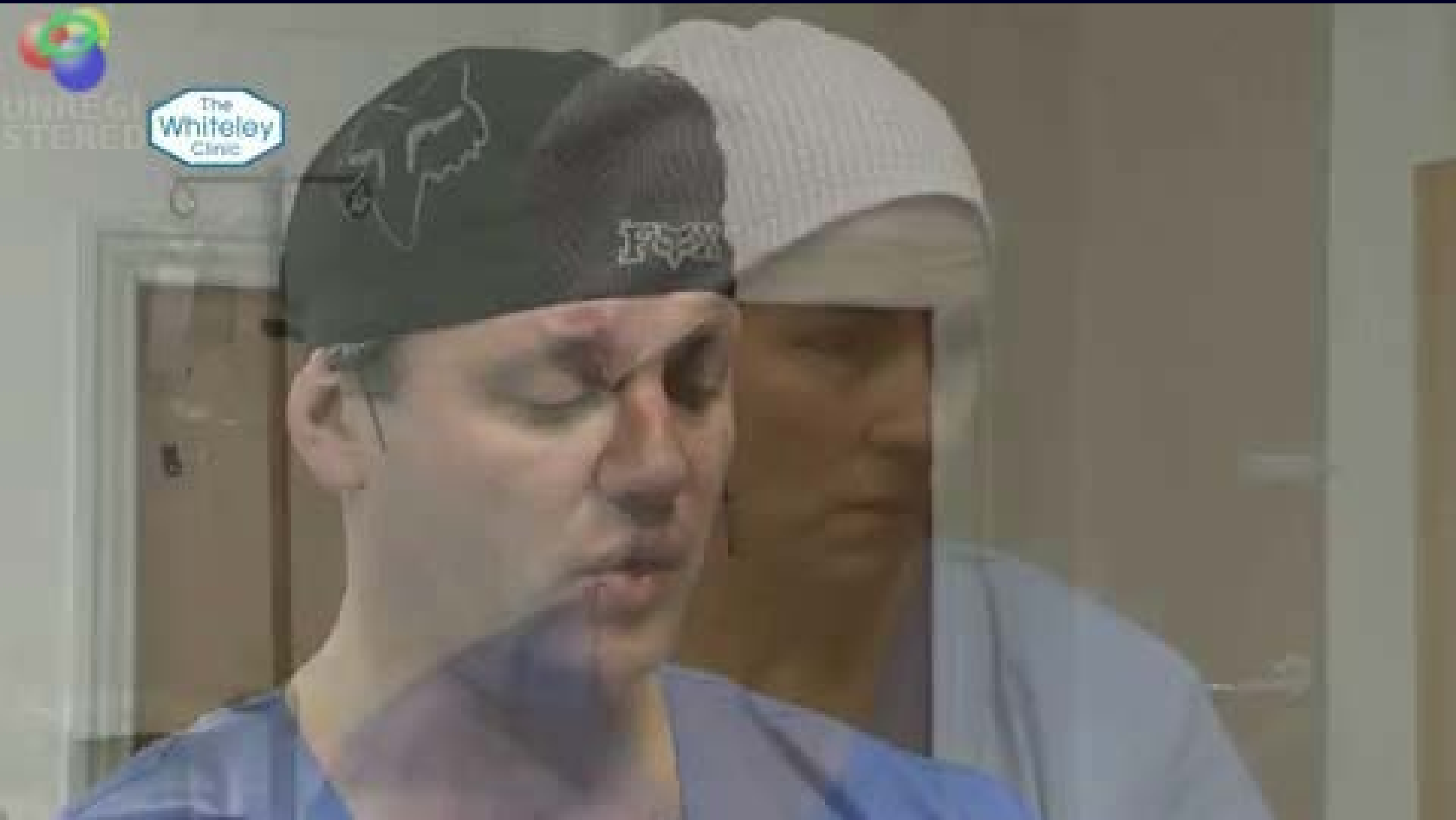# Radiofrequency ablation of the great saphenous vein



Sonogram and cartoon showing an open saphenofemoral junction with a short patent segment above an otherwise occluded great saphenous vein (GSV). The superficial external pudendal (SEP) vein is patent with normal, prograde flow through the SFJ. CFV, Common femoral vein.

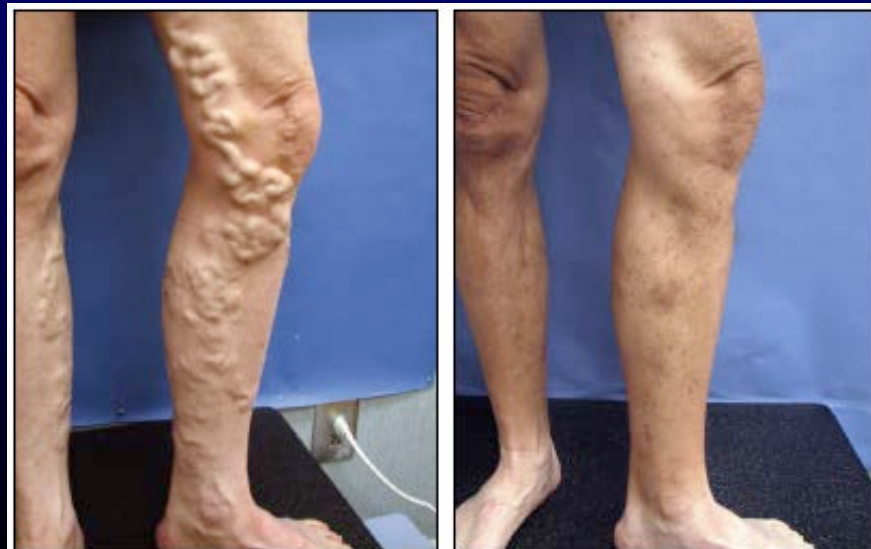

# Radiofrequency ablation of the great saphenous vein

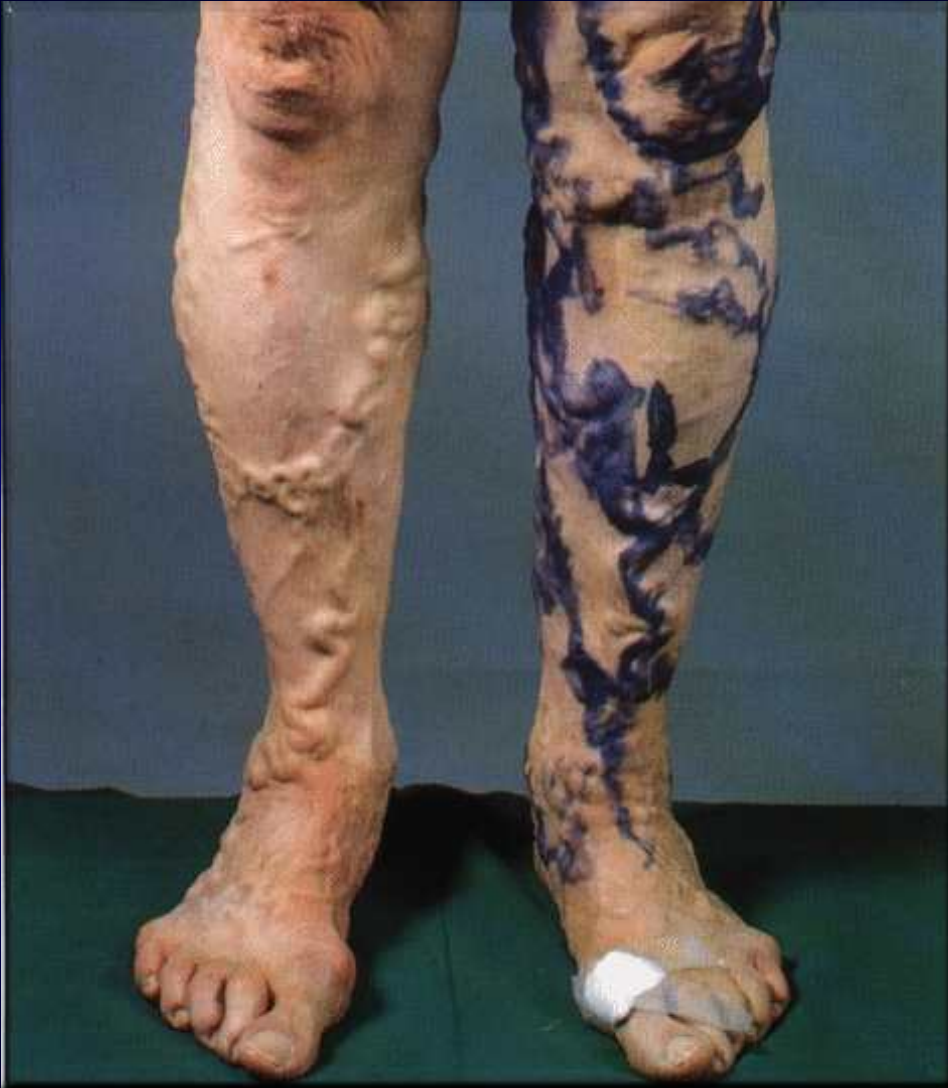

## Benefits of Vein Ablation Treatment

- The treatment takes less than an hour and provides immediate relief of symptoms.
- Immediate return to normal activity with little or no pain. There may be minor soreness or bruising, which can be treated with over-the-counter pain relievers.
- No scars or stitches - because the procedure does not require a surgical incision, just a nick in the skin, about the size of a pencil tip.
- High success rate and low recurrence rate compared to surgery.
- The success rate ranges for vein ablation ranges from 93 - 95 percent.



# Phlebectomy



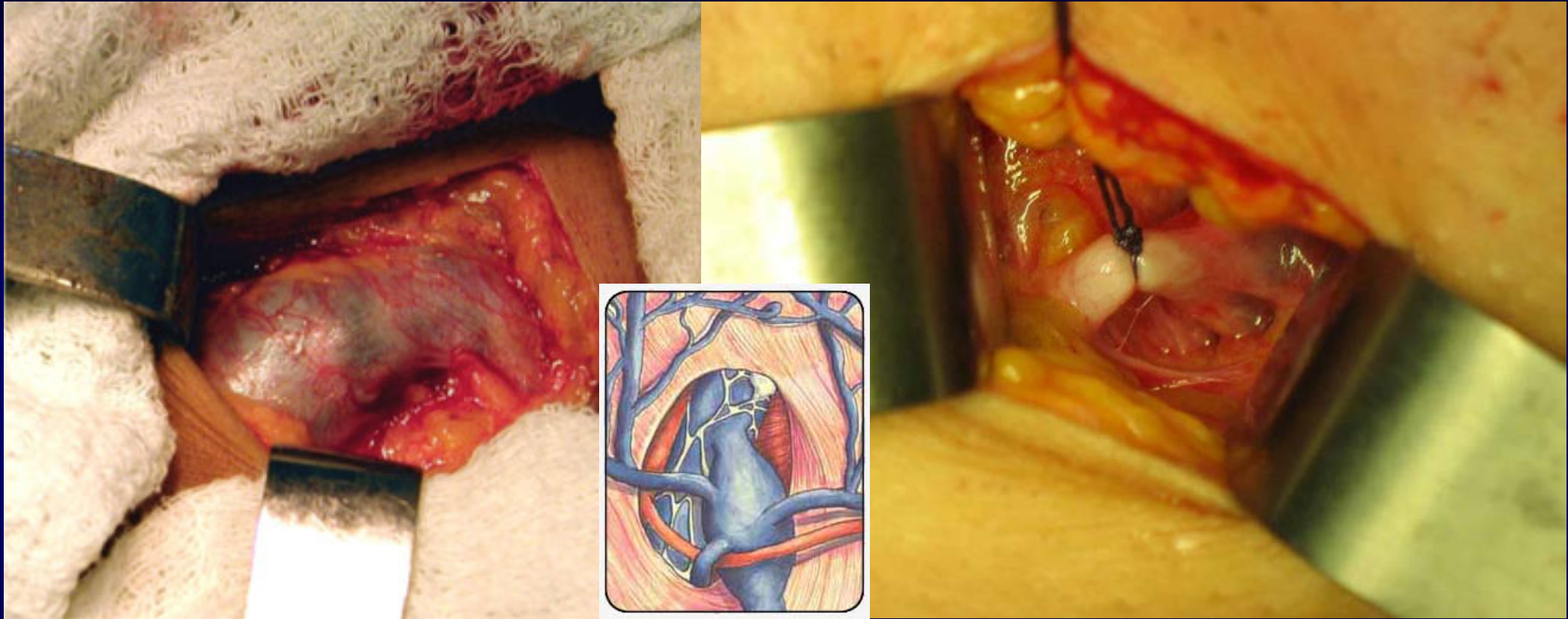
Phlebectomy is one of the oldest forms of treatment for varicose veins; the earliest description of it was written by *Aulus Cornelius Celsus*, a Roman historian of medicine, in A . D . 45.

The first description of a phlebectomy hook comes from a textbook on surgery published in 1545.

The modern technique of ambulatory (outpatient) phlebectomy was developed around 1956 by a Swiss dermatologist named *Robert Muller*.

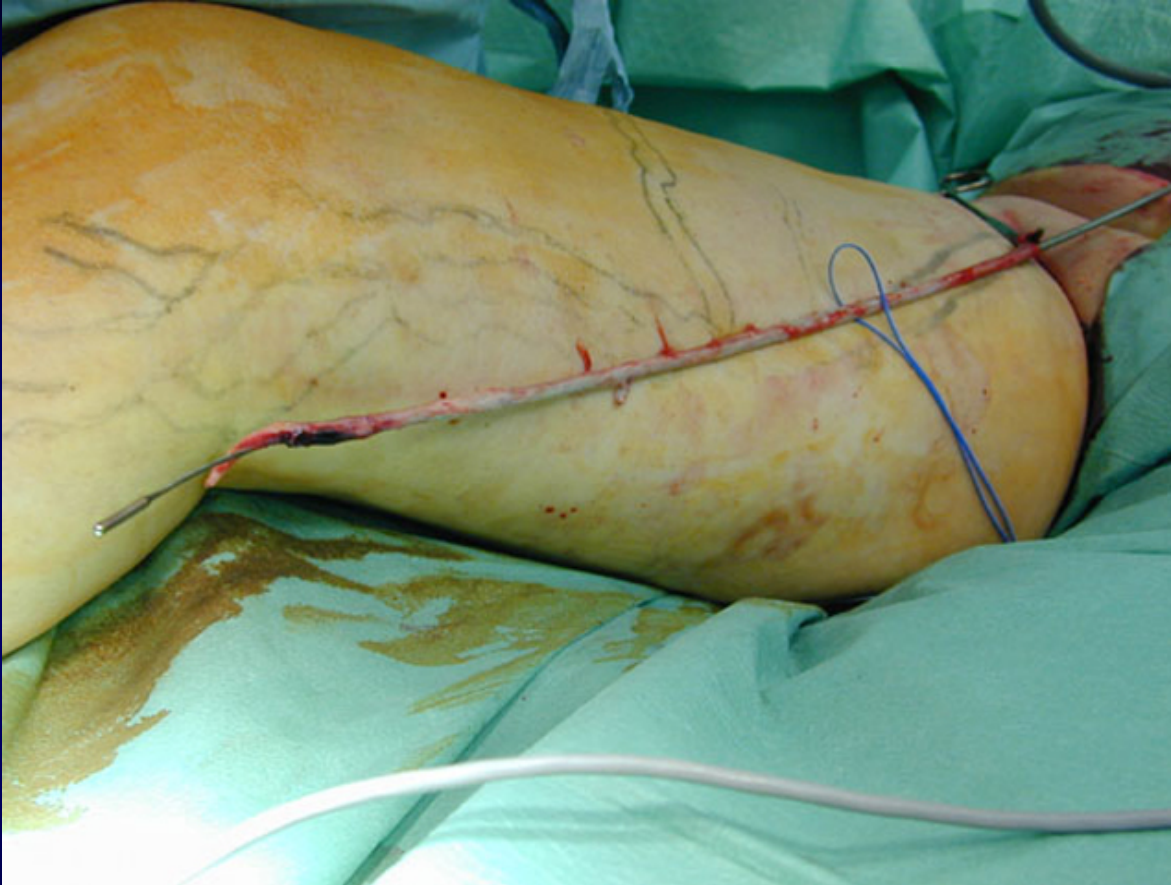
As of 2003, surgical ligation and stripping of the saphenous vein is performed less frequently because of the introduction of less invasive forms of treatment.

# Phlebectomy

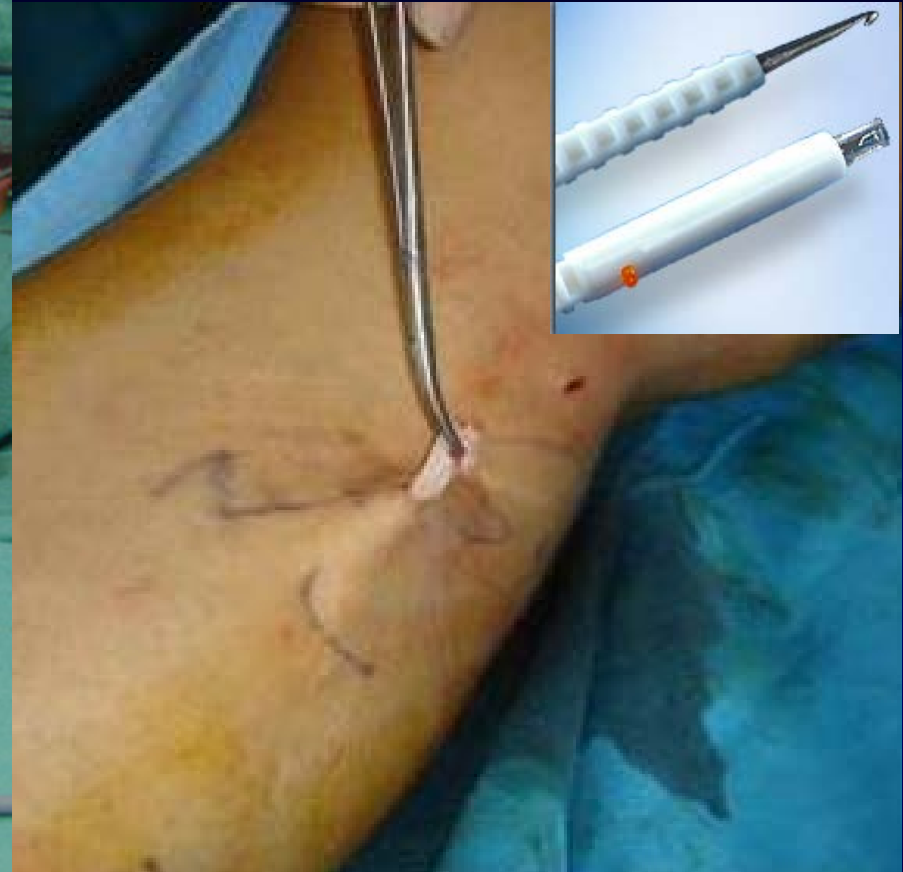

**Ligation refers to the surgical tying off of a large vein in the leg called the greater saphenous vein (Troianov-Trendelenburg procedure)**

# Phlebectomy



**Babcock procedure**



**Narat procedure**

**Stripping refers to the removal of this vein through incisions in the groin area or behind the knee.**

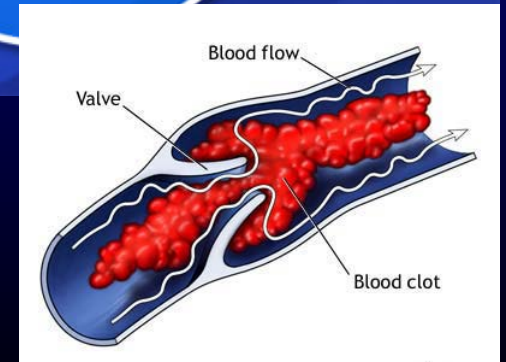
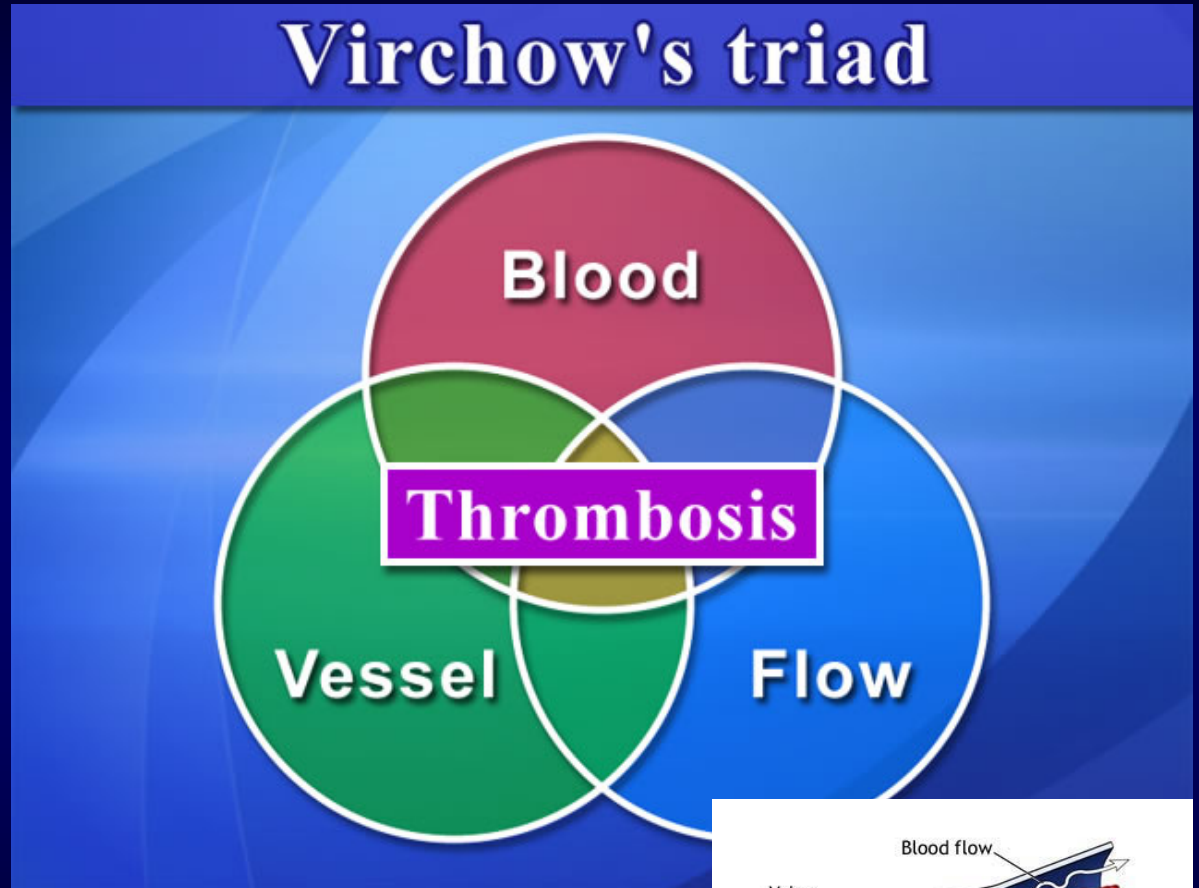
# Phlebectomy



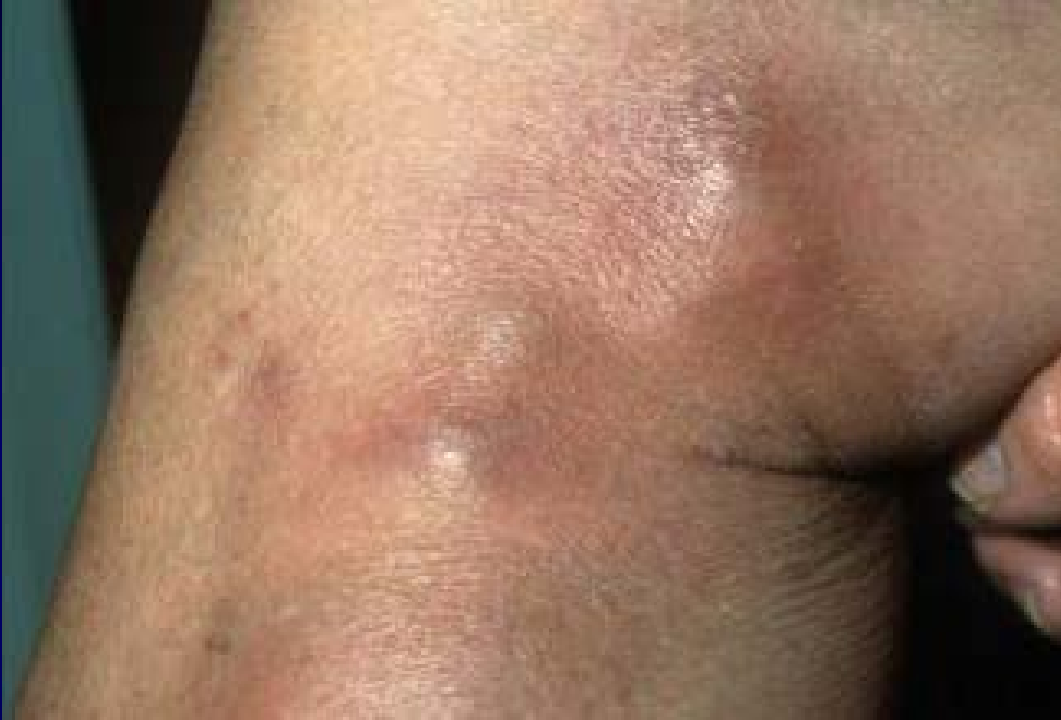# Venous Thrombosis



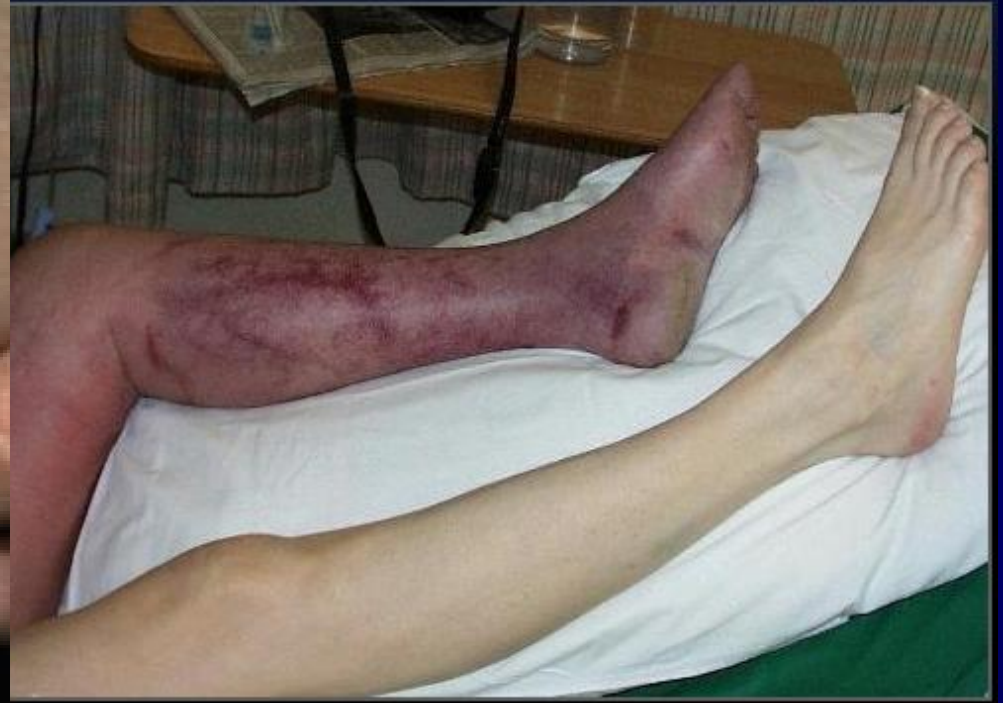Rudolf Ludwig Karl Virchow  
1821-1902



# Venous Thrombosis



Superficial thrombophlebitis



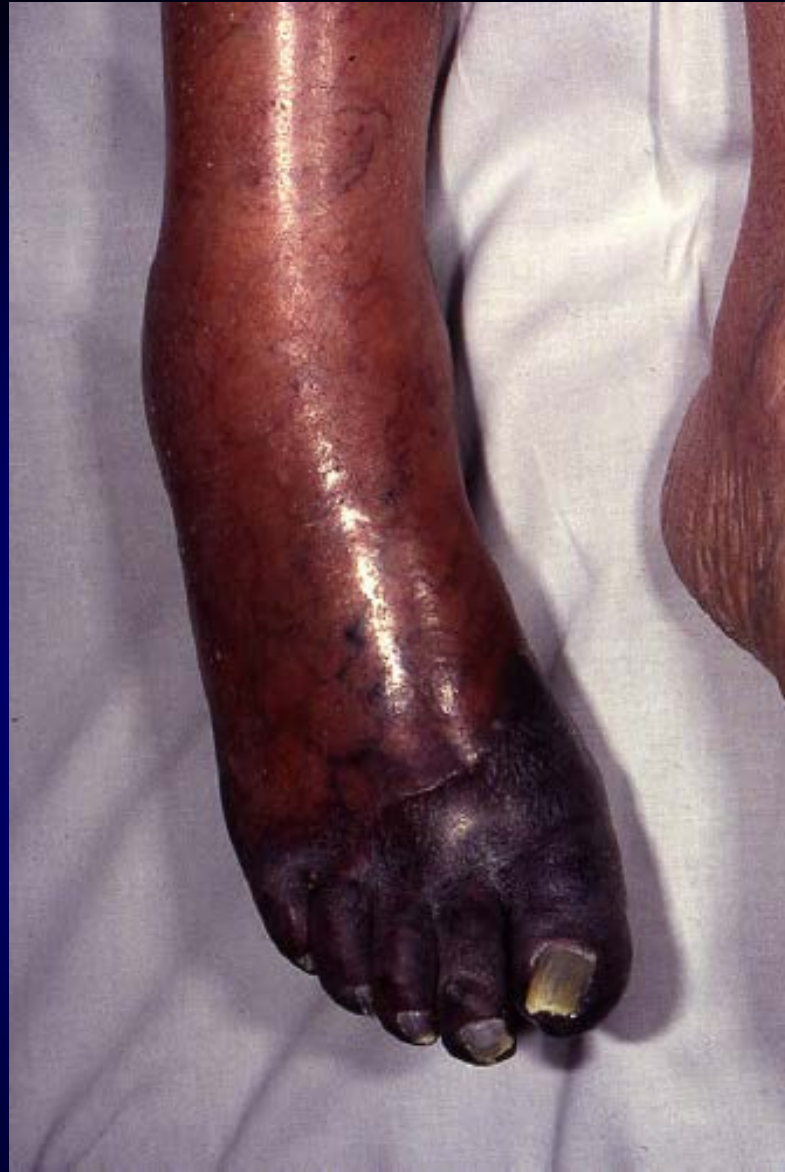*Phlegmasia caerulea dolens*

Deep venous thrombosis



phlegmasia alba dolens · phlegmasia cerulea dolens · venous gangrene





**Venous gangrene affecting the foot of a patient with extensive ilio-femoral deep venous thrombosis.**

**Reduced or stagnant blood flow:** in the supine position, blood flow in the soleal veins is extremely sluggish and thrombus formation in the vein valve pockets is triggered in patients who have other risk factors for thrombosis. Thrombus formation occurs when the natural antithrombotic mechanisms are overcome.

These mechanisms include the local production of:

- prostacyclin, nitric oxide and tissue plasminogen activator
- cell-surface glycosaminoglycans (e.g. heparin sulphate)
- the physiological inhibitors of clotting (e.g. antithrombin, protein C, protein S).

**Injury to the vessel wall:** endothelial damage (due to direct trauma and/or damage to endothelial cells by hypoxia caused by stasis) in the presence of activated clotting factors initiates thrombosis. Local fibrinolysis (a protective mechanism that limits the propagation of thrombosis) is a function of the balance between plasma concentrations of tissue plasminogen activator and plasminogen activator inhibitor-1; both are produced by endothelial cells

**Hypercoagulability:** there are four main anticoagulant mechanisms in the coagulation cascade:

- antithrombin
- protein C and protein S
- tissue factor pathway inhibitor
- the fibrinolytic system.

***The prothrombotic tendency may be:***

- inherited (e.g. thrombophilias)
- due to deficiency of protein C, protein S and antithrombin
- due to genetic mutations (e.g. factor V Leiden, prothrombin 20210A variant).

***Hypercoagulability may be acquired due to:***

- malignancy
- immobilization
- the antiphospholipid syndrome
- heparin-induced thrombocytopenia
- taking oral contraceptive pills or hormone replacement therapy.

***Secondary risk factors for thrombosis in surgical patients***

include:

- obesity
- congestive cardiac failure
- surgery of the pelvis, knee or hip
- inflammatory bowel disease
- sepsis.

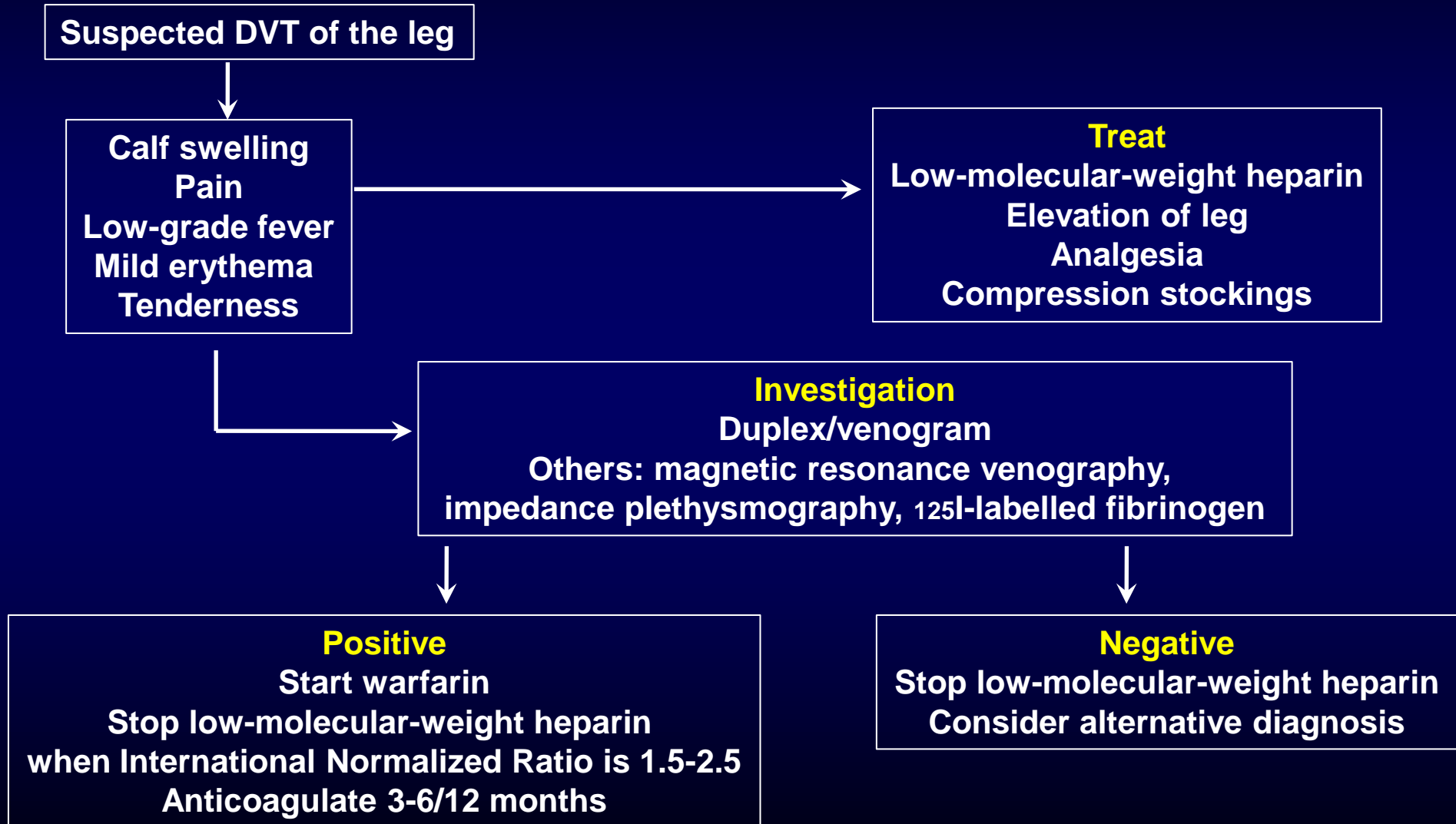
# Predicting the probability of DVT before investigation

Clinical feature	Score
Paralysis, paresis or recent plaster immobilization of extremity	1
Recent major surgery within 4 weeks/bedridden for > 3 days	1
Active cancer (current or within previous 6 months)	1
Localized tenderness along the distribution of the deep venous system	1
Entire leg is swollen	1
Calf swelling by >3cm compared with asymptomatic leg	
Pitting oedema	1
Collateral non-varicose veins	1
Alternative diagnosis as likely or more probable	-2

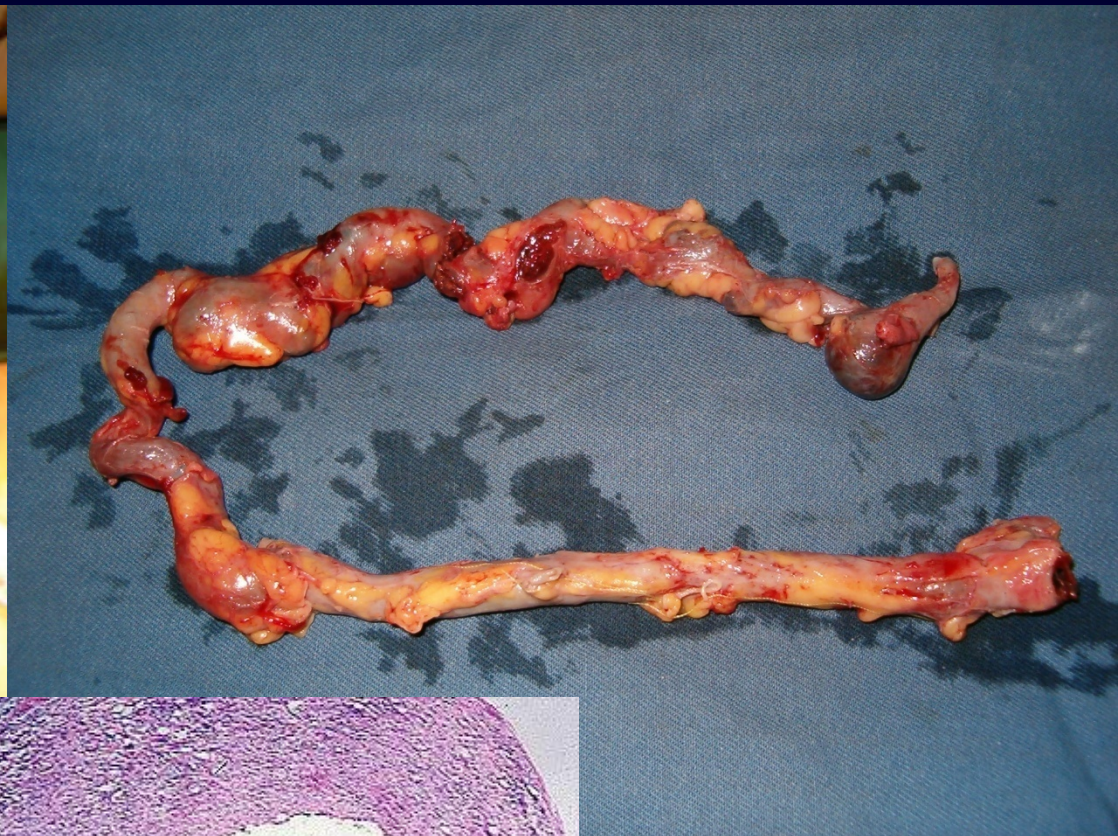
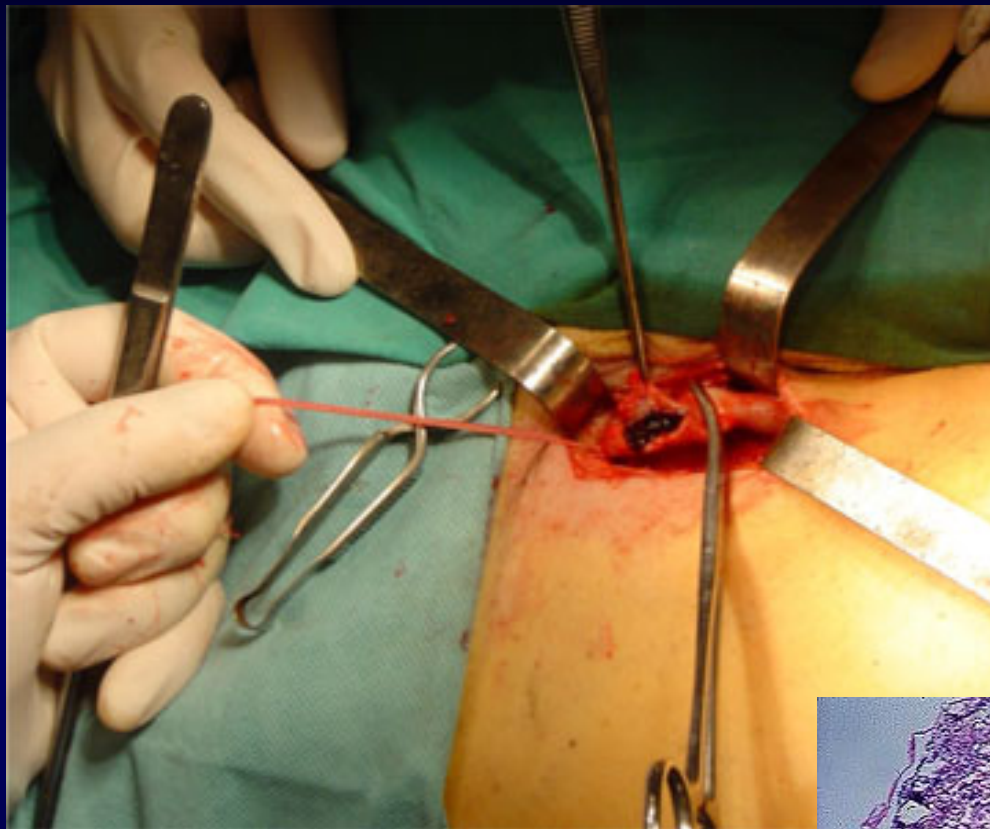
---

0 or less: low probability  
1-2: moderate probability  
3 or more: high probability

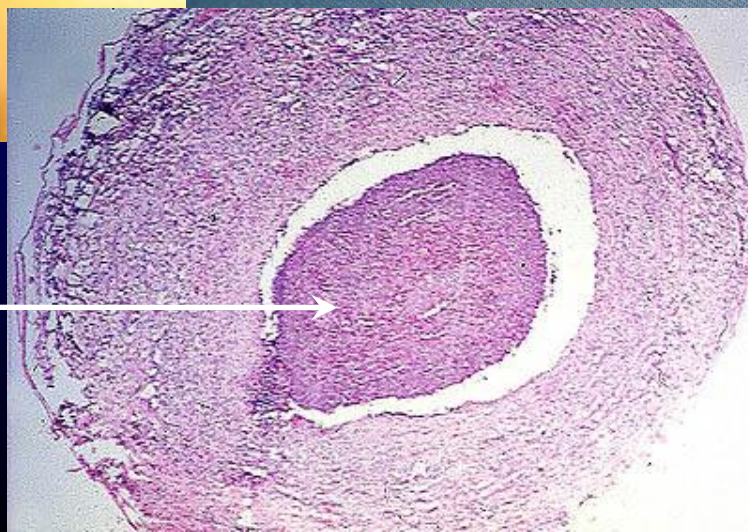
# Management of deep venous thrombosis of the leg



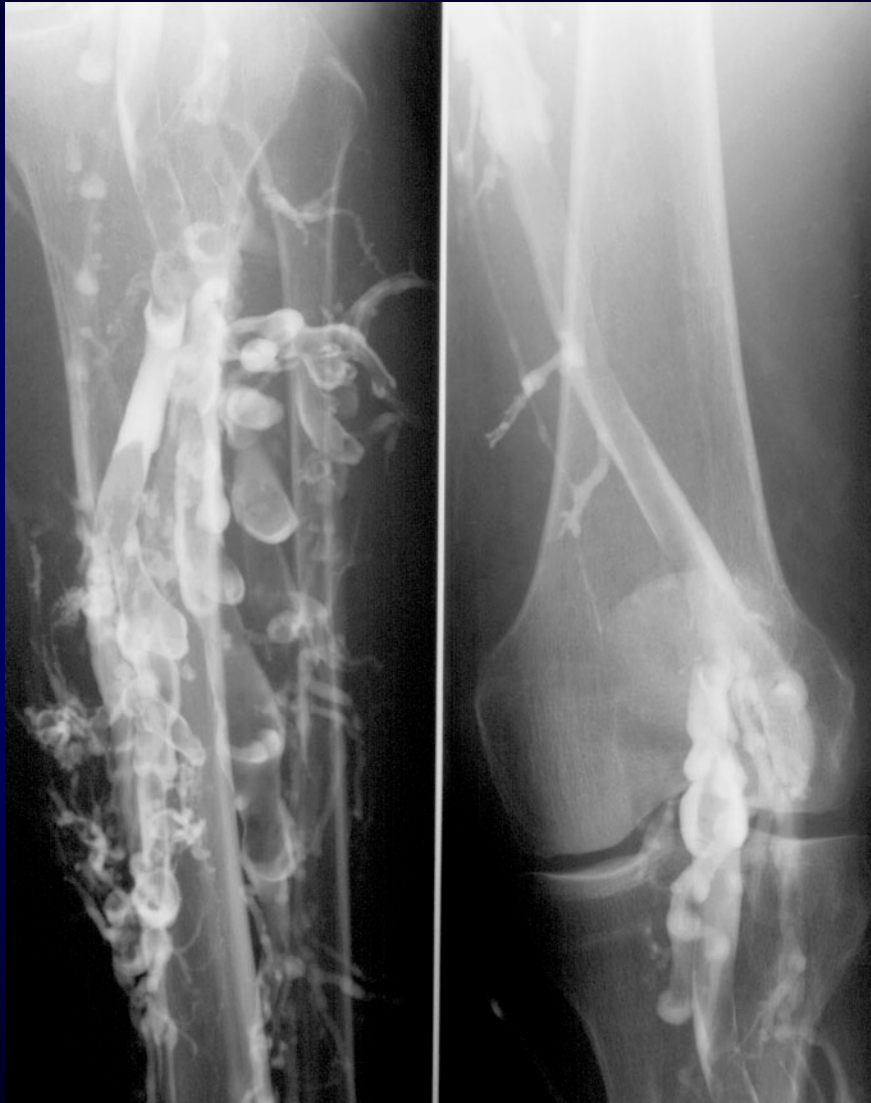# Acute superficial thrombophlebitis



Thrombus



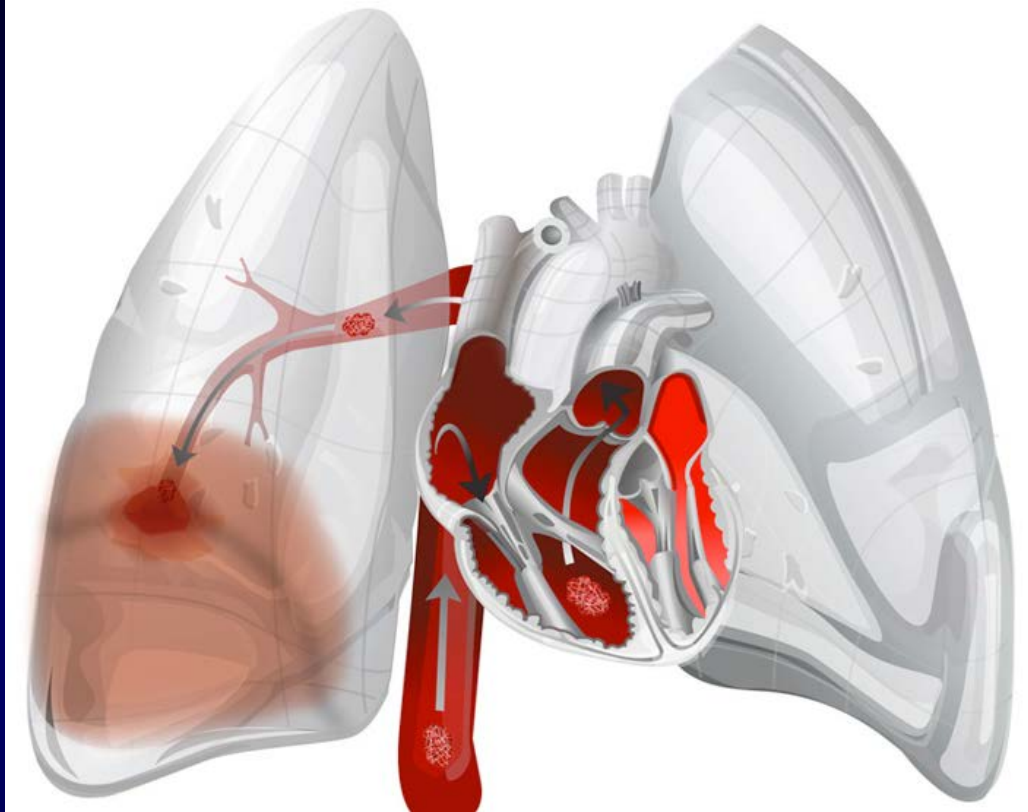
# Phlebography



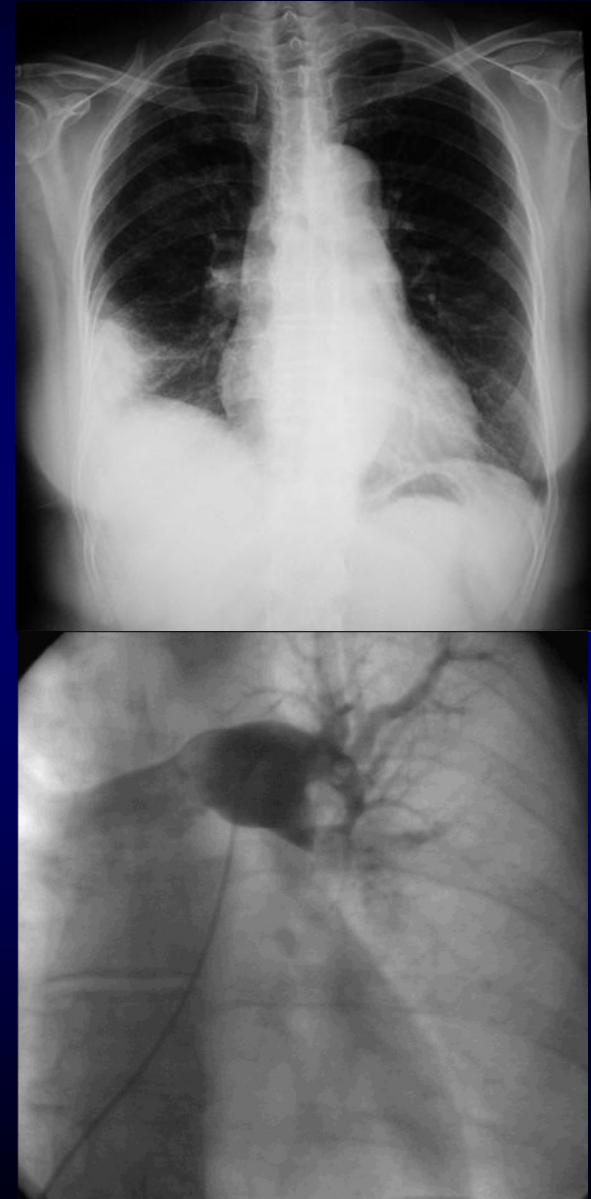
**Venography** (also called **phlebography**) is a procedure in which an x-ray of the veins, a venogram, is taken after a special dye is injected into the bone marrow or veins. The dye has to be injected constantly via a catheter, making it an invasive procedure. Normally the catheter is inserted by the groin and moved to the appropriate site by navigating through the vascular system.

It is the Gold standard for diagnosing acute deep venous thrombosis although its use has been largely supplanted by the less invasive duplex ultrasonography.

# Acute Pulmonary Thromboembolism

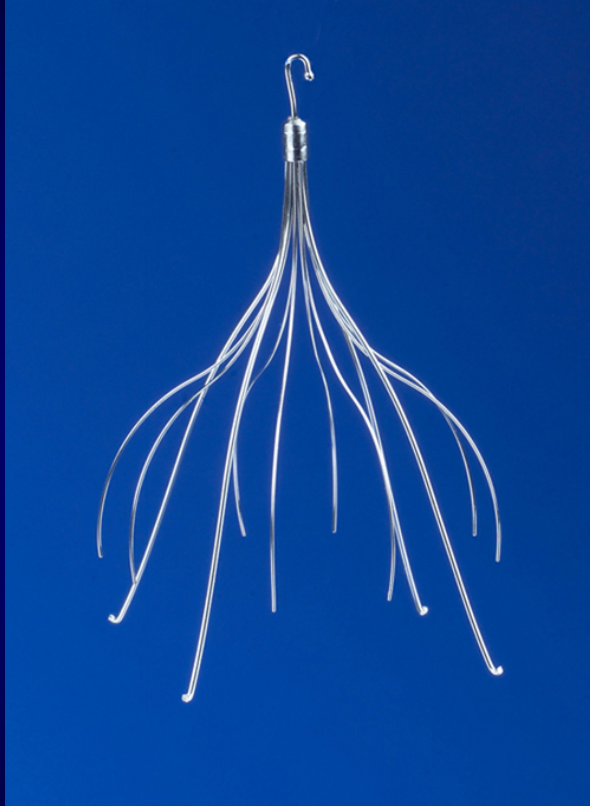


**Pulmonary embolism implicates approximately 50% of cases of untreated proximal deep venous thrombosis (DVT) and contributes to 10-15% of all hospital deaths.**

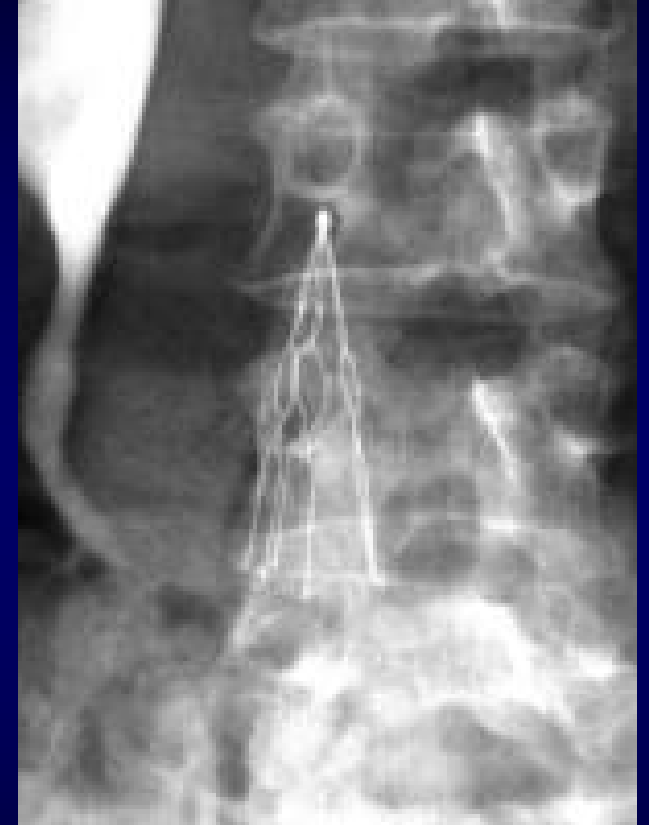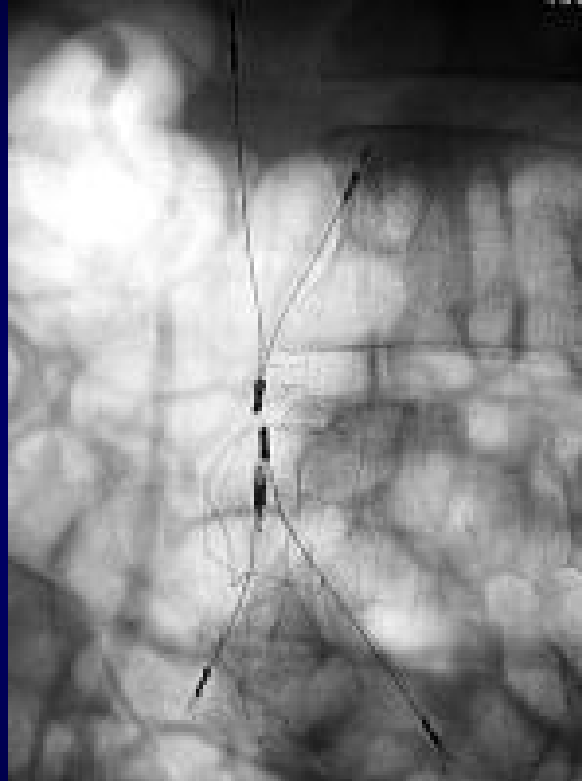




# Inferior Vena Cava Filters

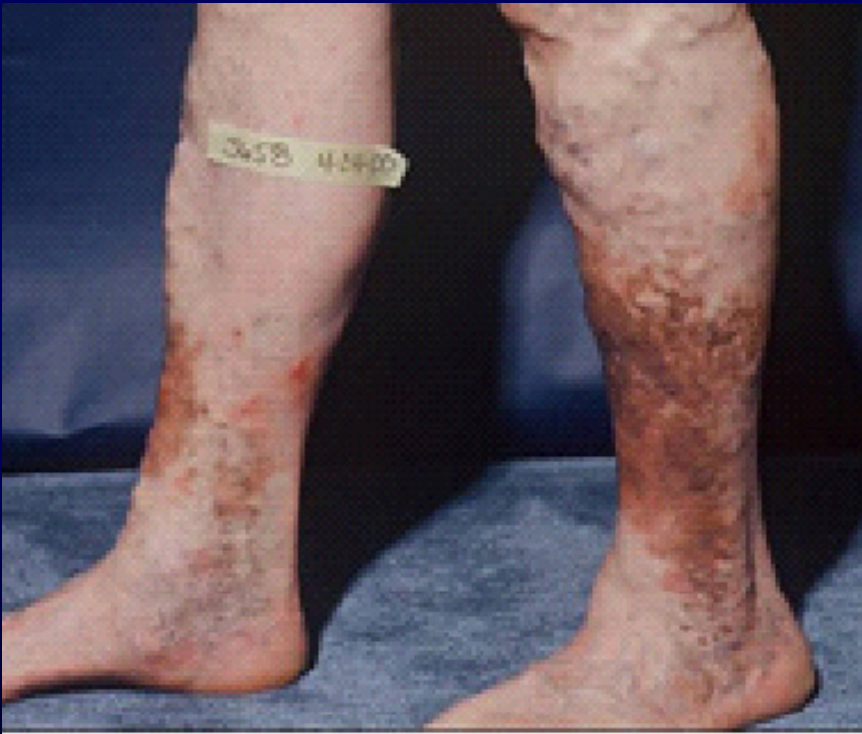

Greenfield filter

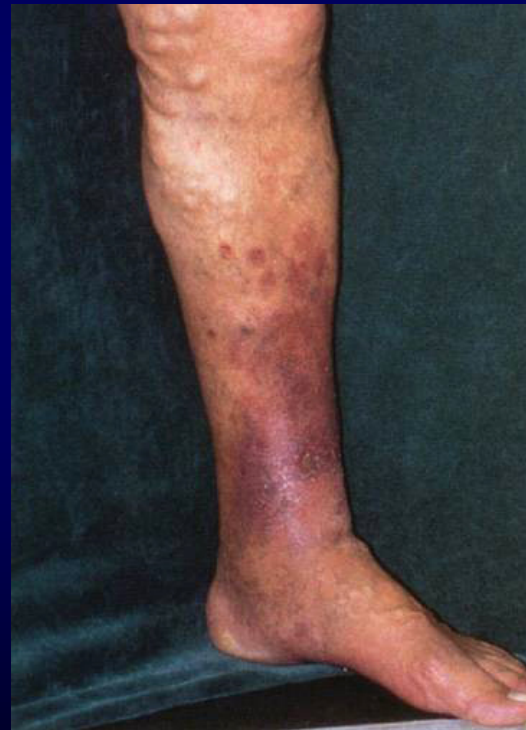

# Chronic Venous Insufficiency

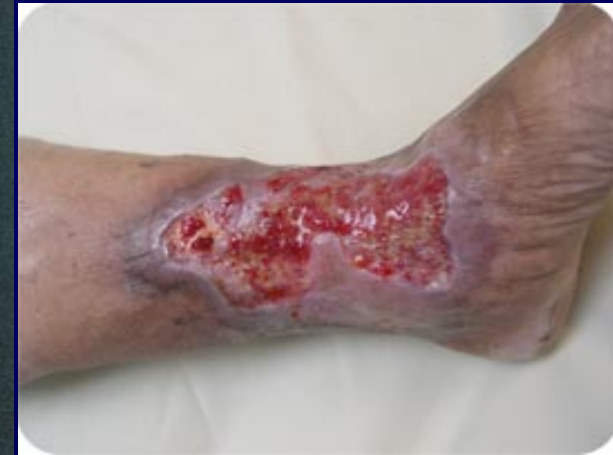When venous disease is long standing, it can become chronic venous insufficiency (CVI). CVI occurs from chronic pooling and congestion caused by leaky varicose veins, from chronic obstruction in veins due to repeated clots (thrombosis), or from repeated inflammation of the veins (phlebitis). As this condition worsens and become severe, skin changes and leg ulcerations can occur.



**Leg Skin Changes**

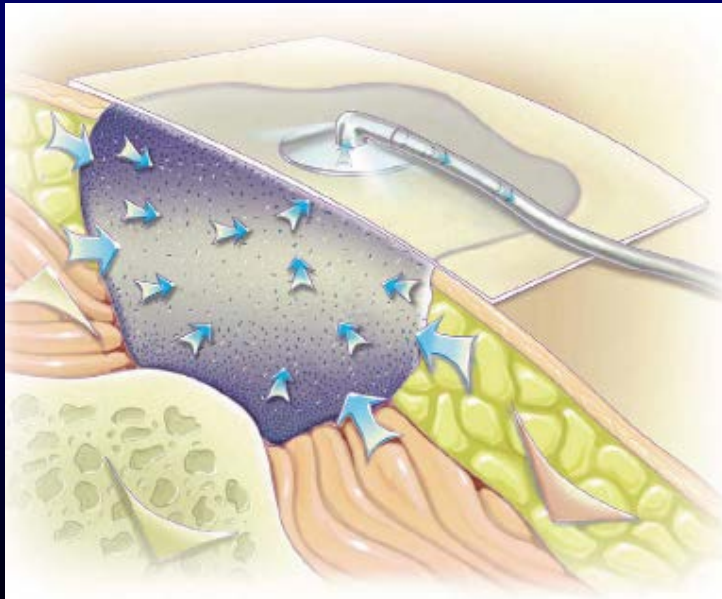
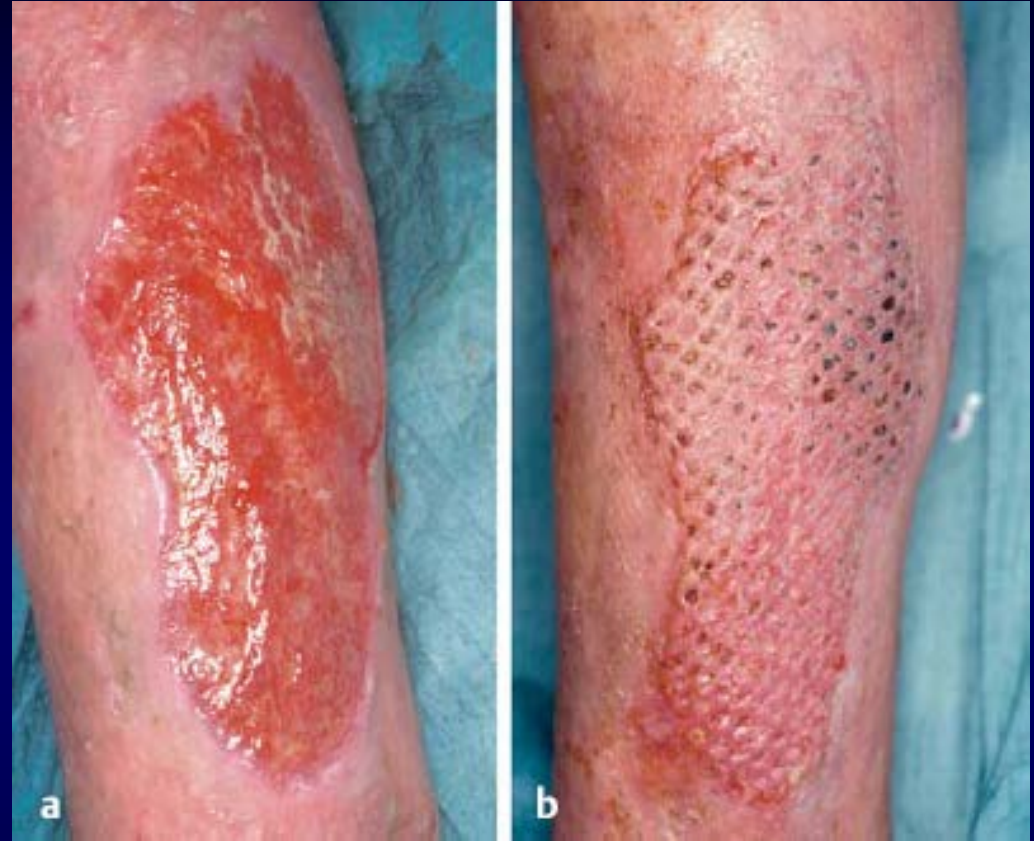
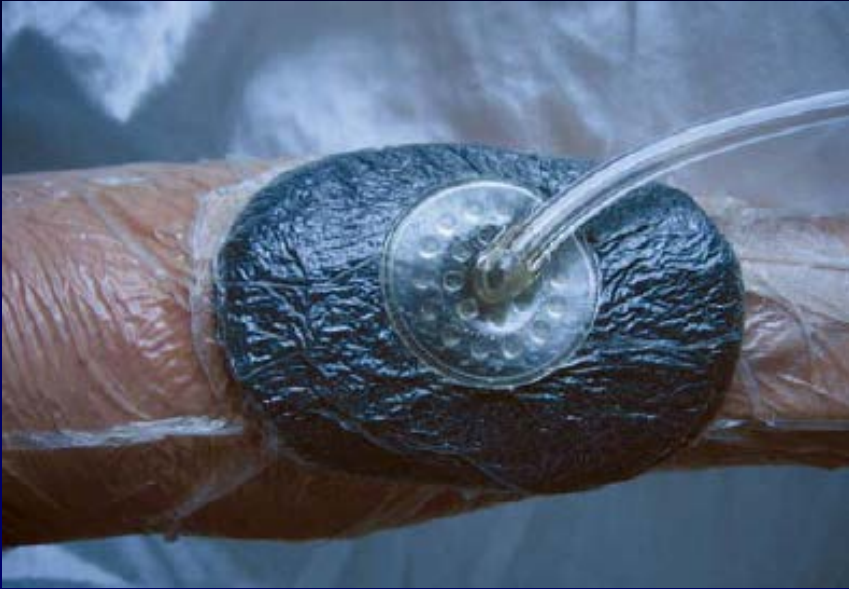
**Lipodermatosclerosis**



**Venous stasis ulcer**

# Chronic Venous Insufficiency



- VAC system
- Dermoplasty

## Subfascial endoscopic perforator vein surgery (SEPS)

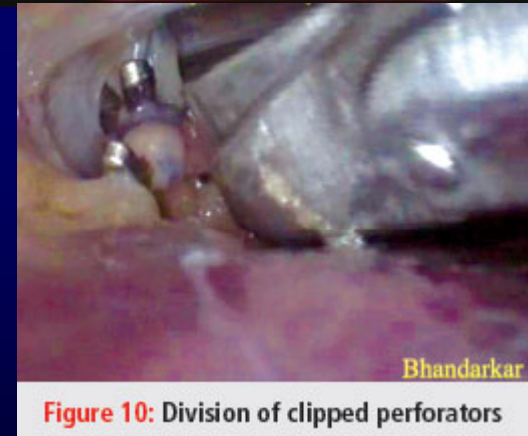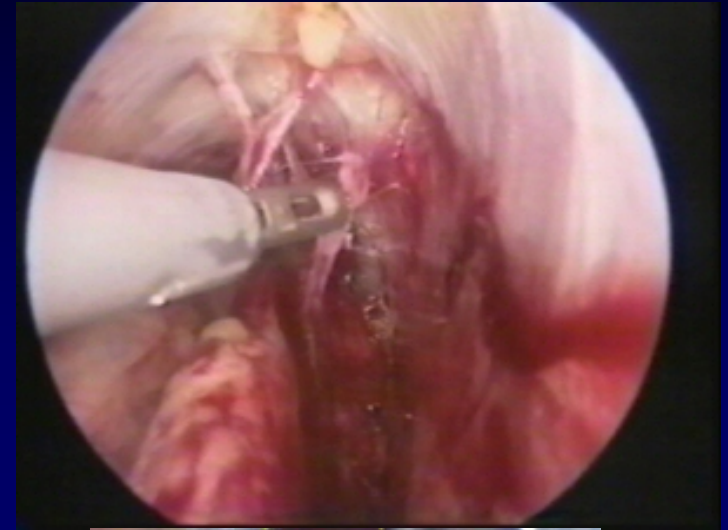

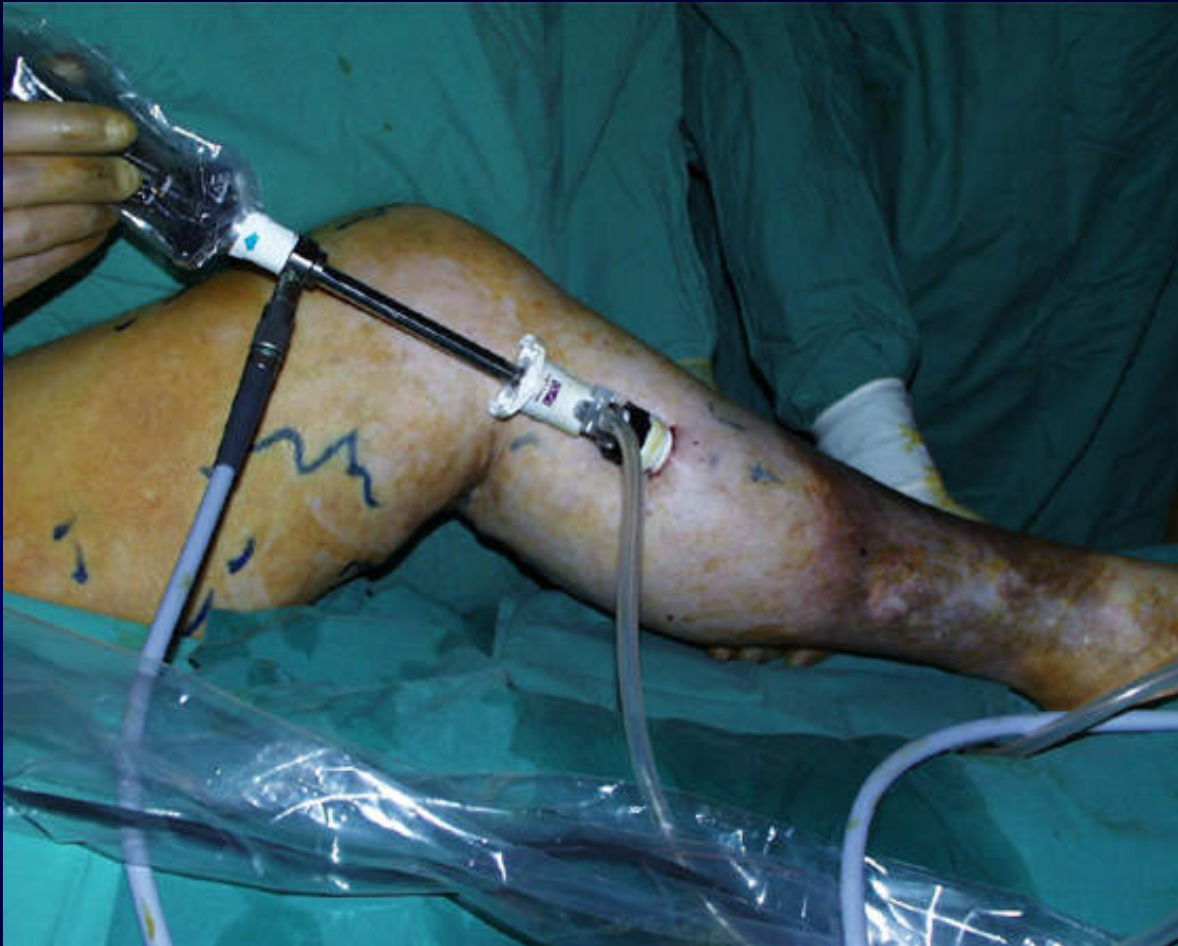
Figure 10: Division of clipped perforators

The complication rate in patients treated with the Linton procedure was unacceptably high. SEPS is minimal invasive treatment modality for chronic venous insufficiency and venous ulcers.