

Peptic Ulcer Disease

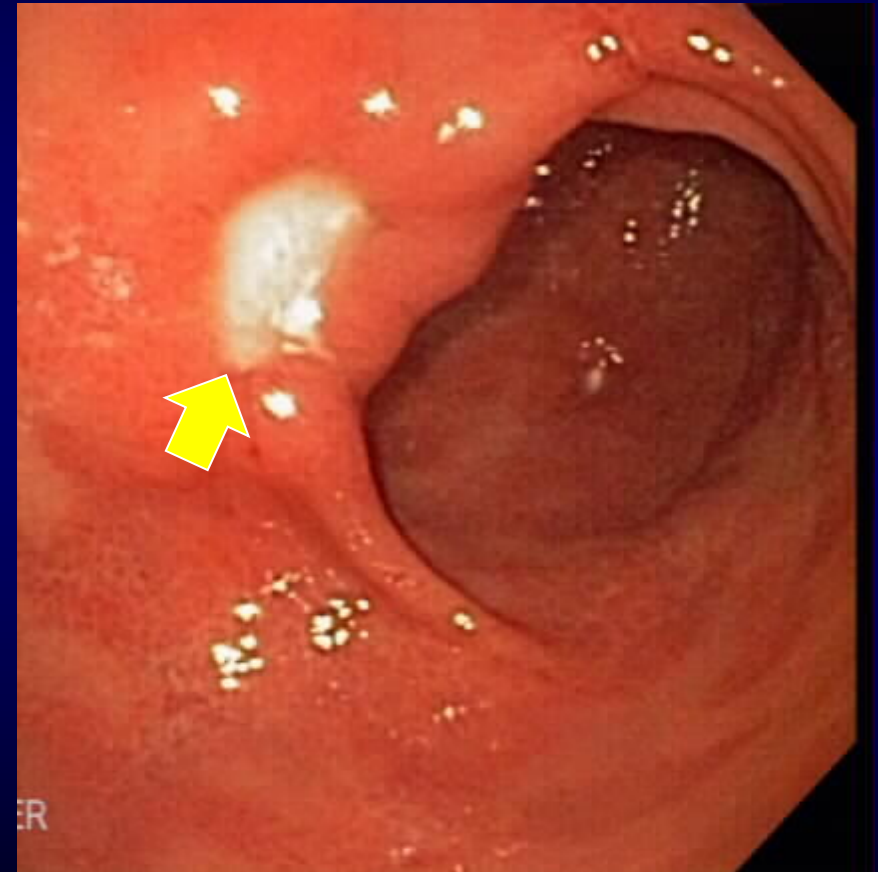
Ghidirim Gh., Mishin I., Zastavnitsky Gh., Vozian M.

A peptic ulcer (PU) is a defect (hole) in the gut lining of the stomach, or duodenum.

Peptic ulcers are defects in the gastric or duodenal mucosa that extend through the muscularis mucosa.

A peptic ulcer of the stomach is called a gastric ulcer; of the duodenum, a duodenal ulcer.

An ulcer occurs when the lining of these organs is corroded by the acidic digestive juices which are secreted by the stomach cells.



Gastric ulcer (lesser curvature) with punched-out ulcer base with whitish exudate.

In the United States, PUD affects approximately 4.5 million people annually. Approximately 10% of the US population has evidence of a duodenal ulcer at some time.

Of those infected with *H pylori*, the lifetime prevalence is approximately 20%. Only about 10% of young persons have *H pylori* infection; the proportion of people with the infection increases steadily with age.

Overall, the incidence of duodenal ulcers has been decreasing over the past 3-4 decades.

Although the rate of simple gastric ulcer is in decline, the incidence of complicated gastric ulcer and hospitalization has remained stable, partly due to the concomitant use of aspirin in an aging population.

The hospitalization rate for PUD is approximately 30 patients per 100,000 cases.

Sung JJ., et al.: *Am J Gastroenterol.* Jan 2010;105(1):84-9.

The prevalence of PUD has shifted from predominance in males to similar occurrences in males and females. Lifetime prevalence is approximately **11-14% in men** and **8-11% in women**.

Age trends for ulcer occurrence reveal declining rates in younger men, particularly for duodenal ulcer, and increasing rates in older women. Trends reflect complex changes in risk factors for PUD, including age-cohort phenomena with the prevalence of *H pylori* infection and the use of **NSAIDs** in older populations.

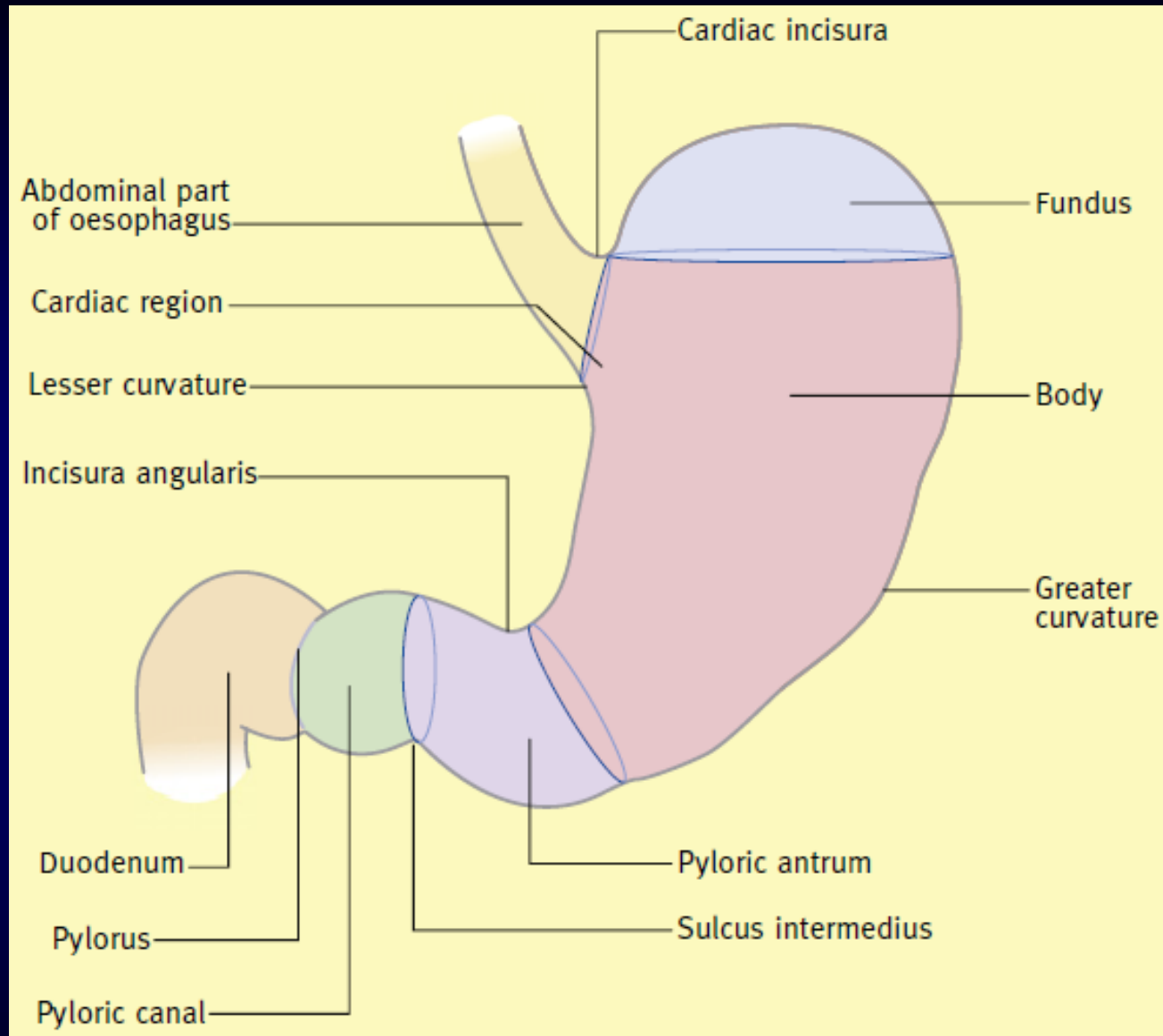
Pietrojusti A., et al.: *Aliment Pharmacol Ther.* 2005;21(7):909-15.

Laine L., et al.: *Aliment Pharmacol Ther.* 2010;32(10):1240-8.

The parts of the stomach. (From Gray's Anatomy 40th edition).

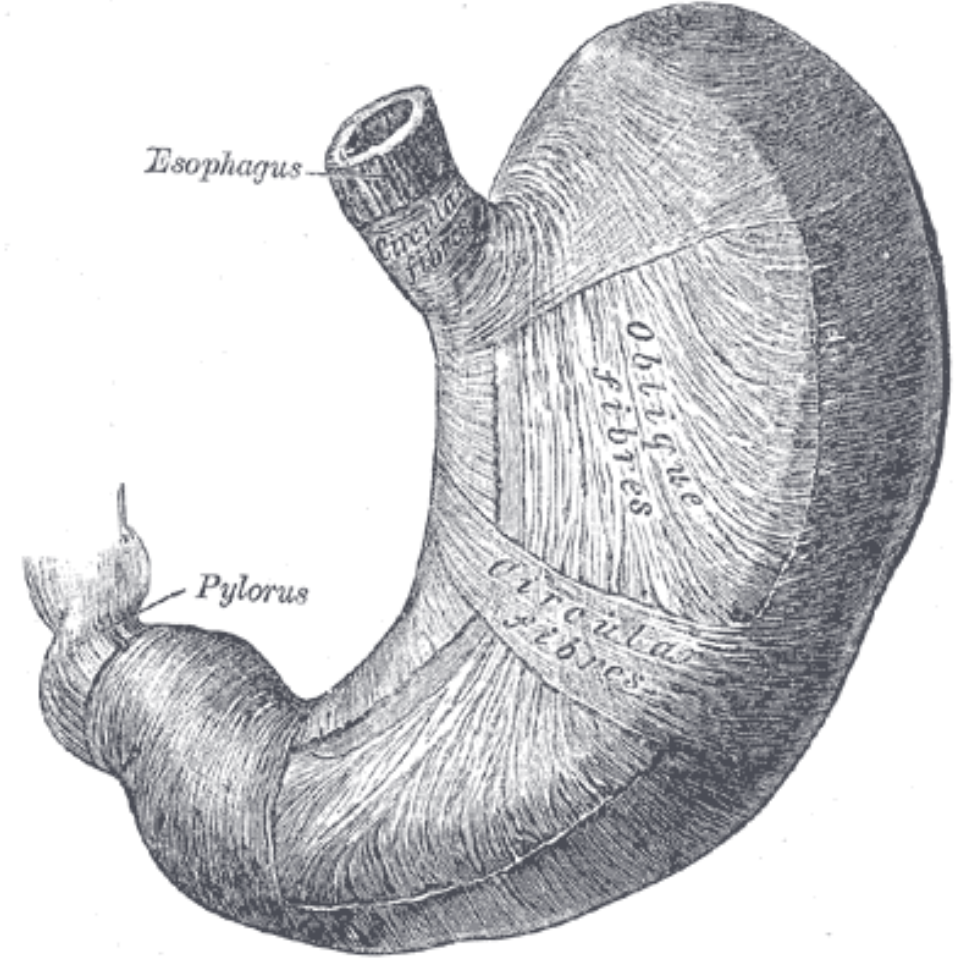
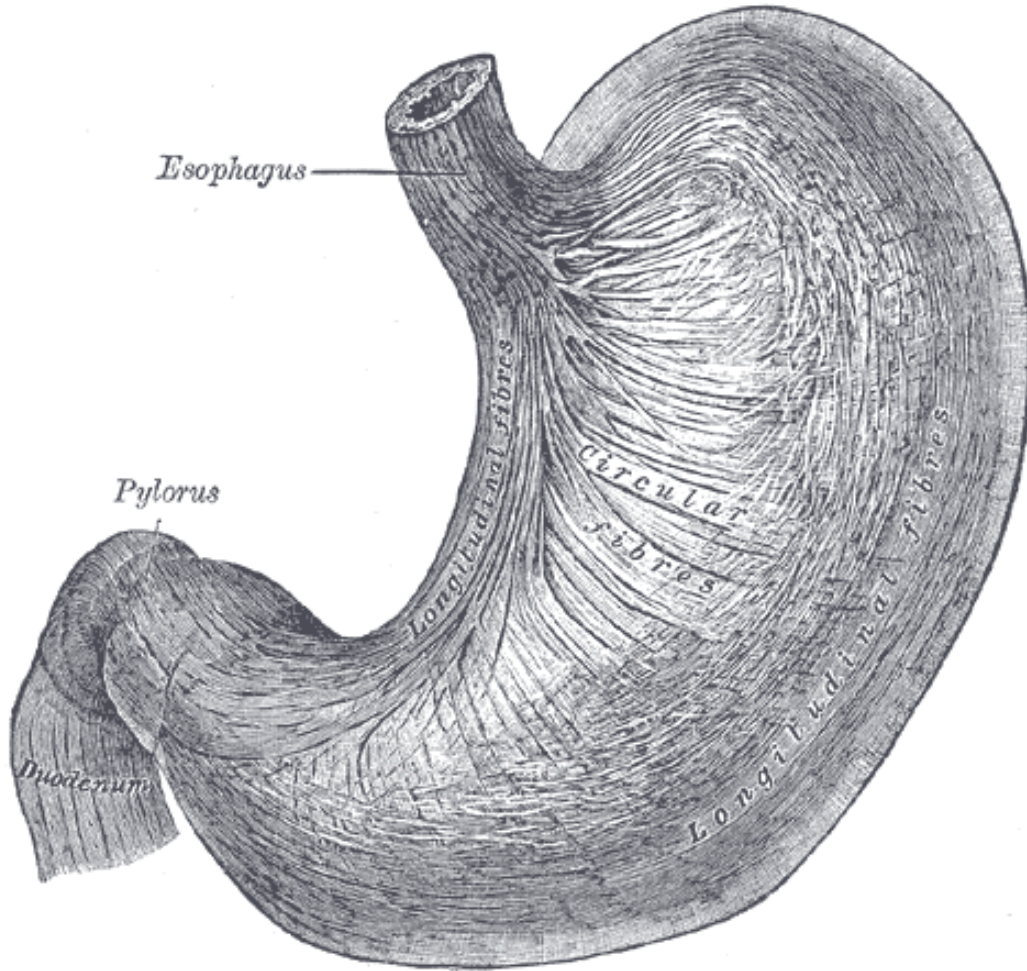
The stomach has an **anterior** and **posterior surface**, a **greater** and **lesser curvature** and two orifices, the **cardiac orifice**, and the **pylorus**. The thick circular muscle of the pyloric sphincter is easily felt, (and is hypertrophied in the condition of infantile pyloric stenosis). However, in man there is no anatomical sphincter to be demonstrated at the cardia.

The **fundus** is the dome-like projection of the stomach above and to the left of the cardiac orifice. The **body** of the stomach passes from the cardiac orifice to the incisura – it is this part of the organ that contains the **parietal cells** which **secrete HCl**. From the incisura to the pylorus is the **pyloric antrum**, (the 'anteroom'), which produces the **hormone gastrin**, responsible for the hormonal phase of **gastric acid** secretion.

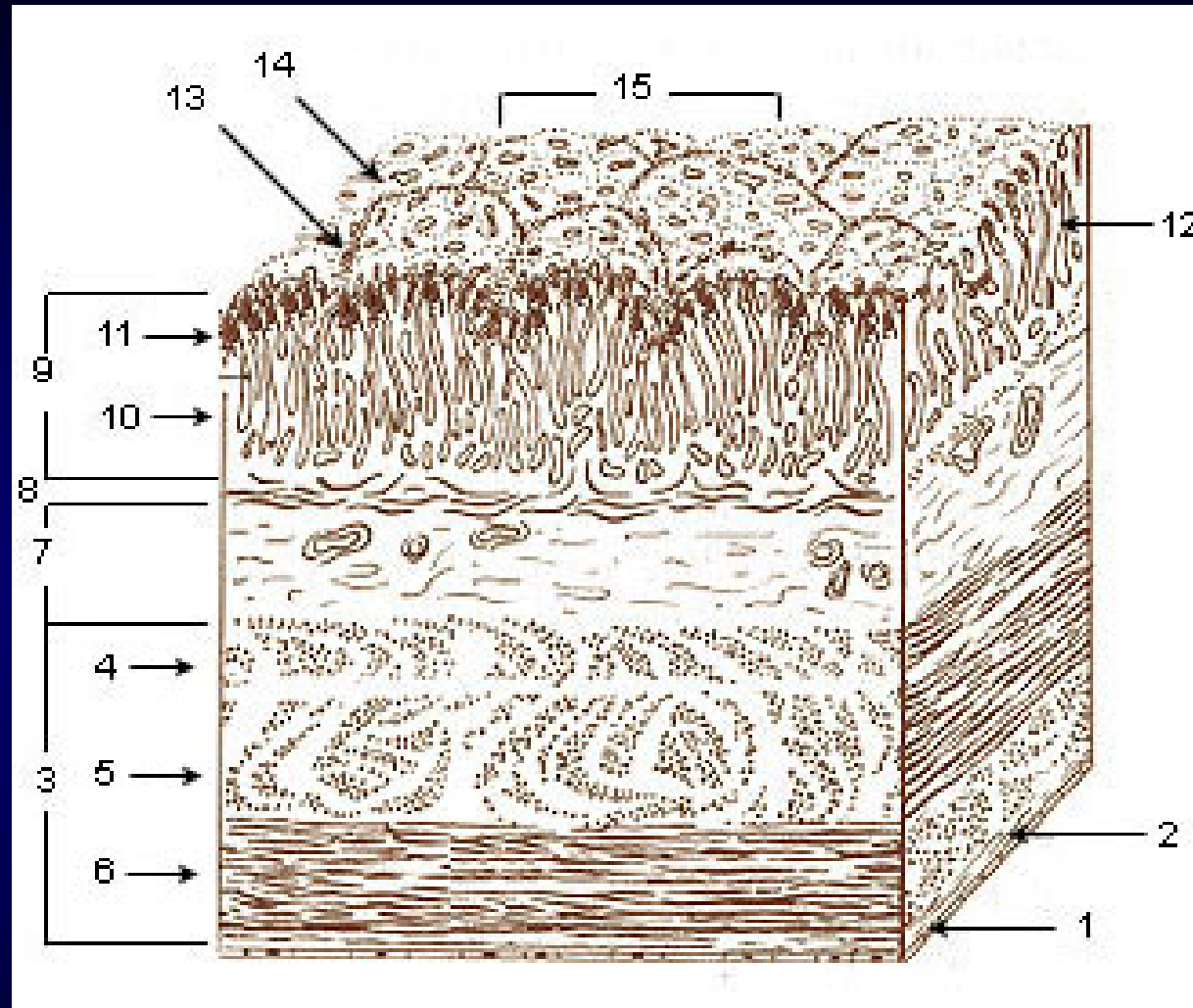


The pylorus is easily identified by palpation of the very distinct ring of sphincter muscle and is also marked by a **constant vein (of Mayo)** that crosses at this level.

Muscular layers of the gastric wall



Layers of the gastric wall

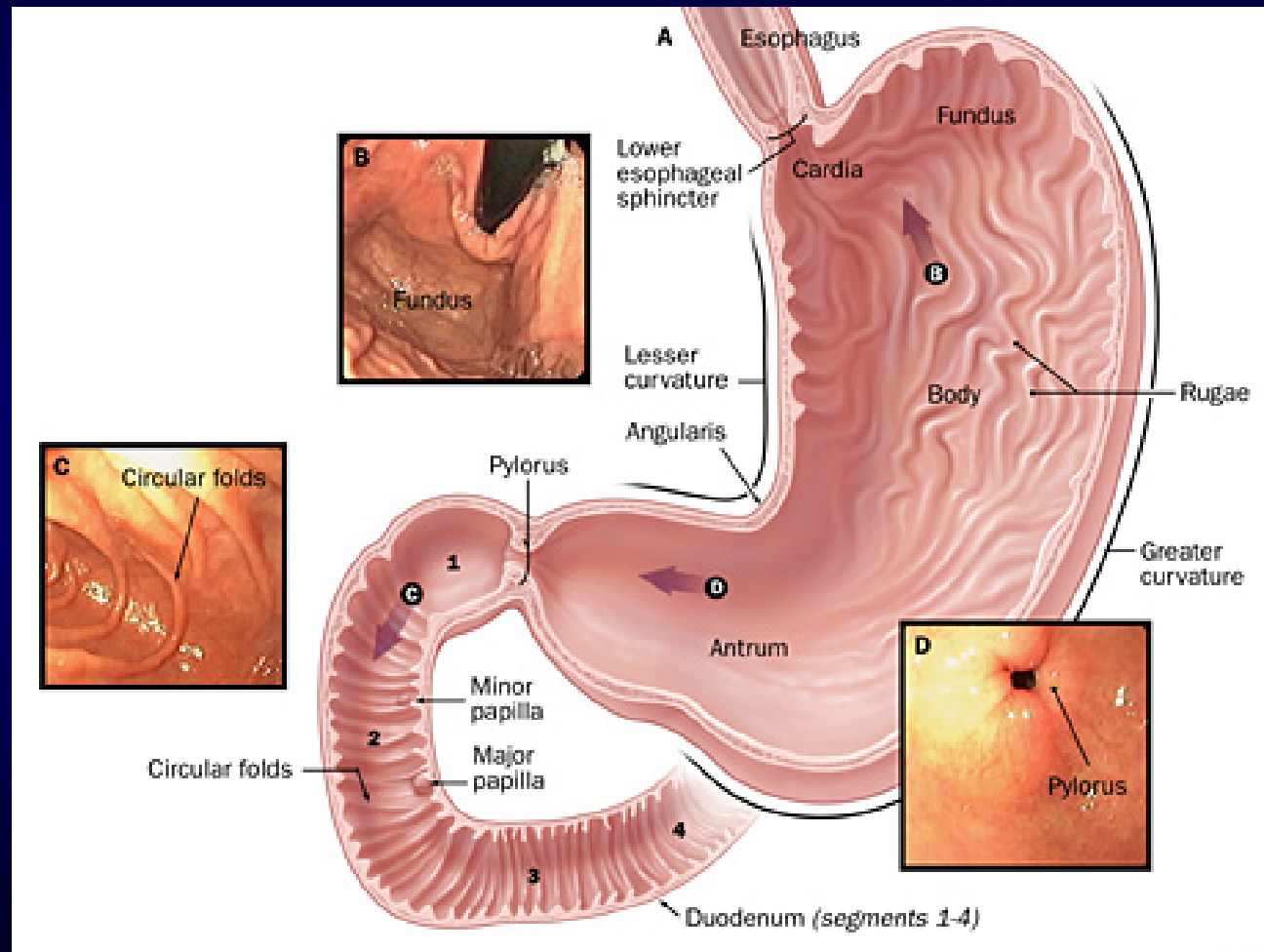


1. Serosa
2. Tela subserosa
3. Muscularis
4. Oblique fibers of muscle wall
5. Circular muscle layer
6. Longitudinal muscle layer
7. Submucosa
8. Lamina muscularis mucosae
9. Mucosa
10. Lamina propria
11. Epithelium
12. Gastric glands
13. Gastric pits
14. Villous folds
15. Gastric areas

The parts of the duodenum

The duodenum extends from the pylorus to the ligament of Treitz in a sharp curve that almost completes a circle.

It is named so, because it is about equal in length to the breadth of 12 fingers. It is largely retroperitoneal and its position is relatively fixed.



The duodenum is the shortest segment of the intestine and is about 23 to 28 cm long.

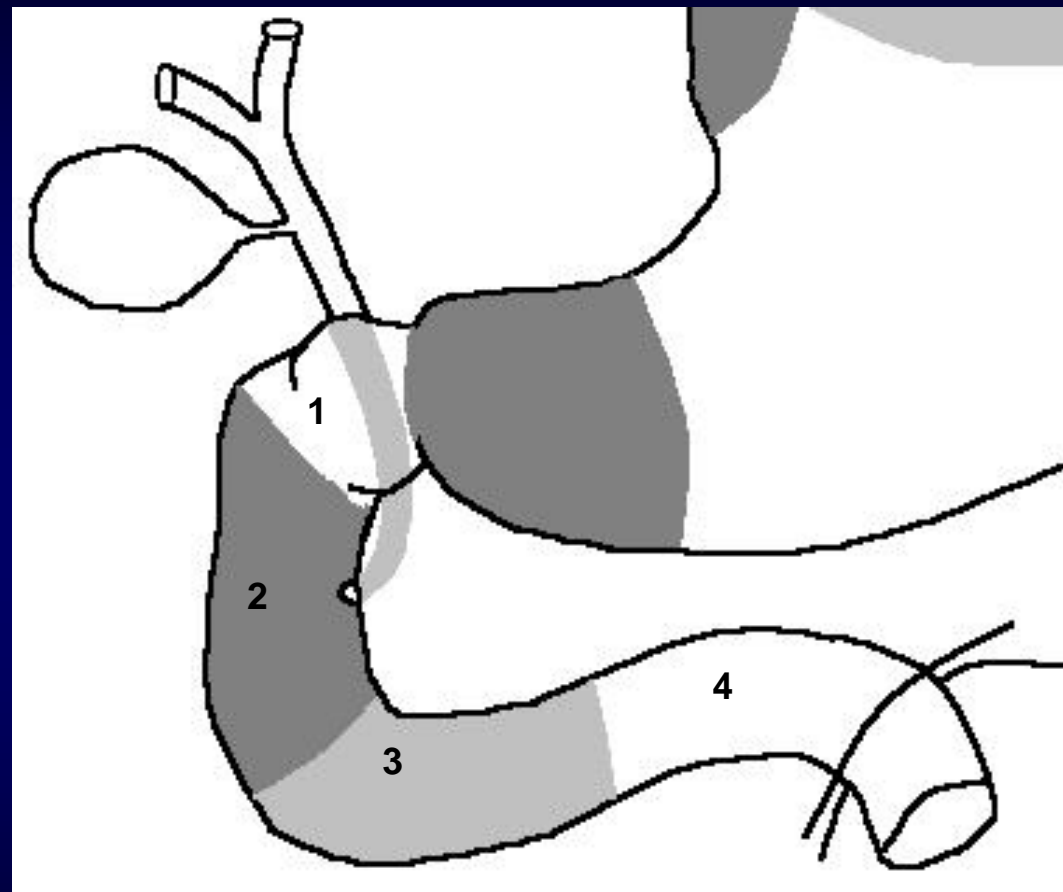
It is roughly horseshoe-shaped, with the open end up and to the left, and it lies behind the liver. On anatomic and functional grounds, it can be divided into four segments: the superior, descending, horizontal, and ascending duodenum.

1. The **superior portion** is app. 5 cm in length, beginning at the pylorus, and passes beneath the liver to the neck of the gallbladder. The first part of the superior portion (2–3 cm) is the duodenal bulb.

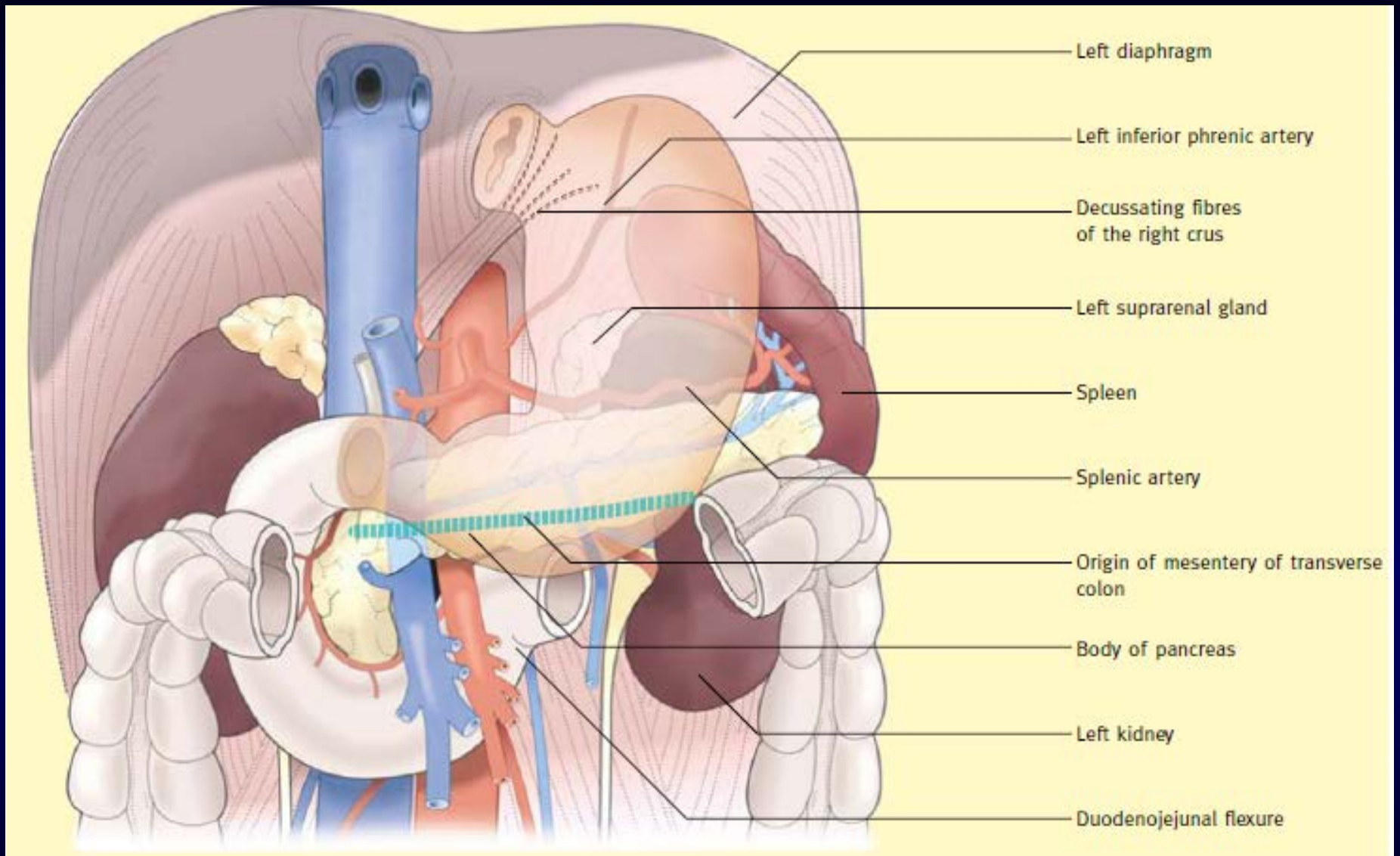
2. The **descending or second part** of the duodenum takes a sharp curve and goes down along the right margin of the head of the pancreas. The common bile duct and the pancreatic duct enter the duodenum at this level through the major papilla either separately or together.

3. The duodenum turns medially, becoming the **horizontal portion**, and passes across the spinal column, inclining upward for 5–8 cm.

4. The **ascending portion** begins at the left of the spinal column, ascending left of the aorta for 2–3 cm, and ends at the ligament of Treitz, where the intestine angles forward and downward to become the jejunum.



Posterior relations of the stomach



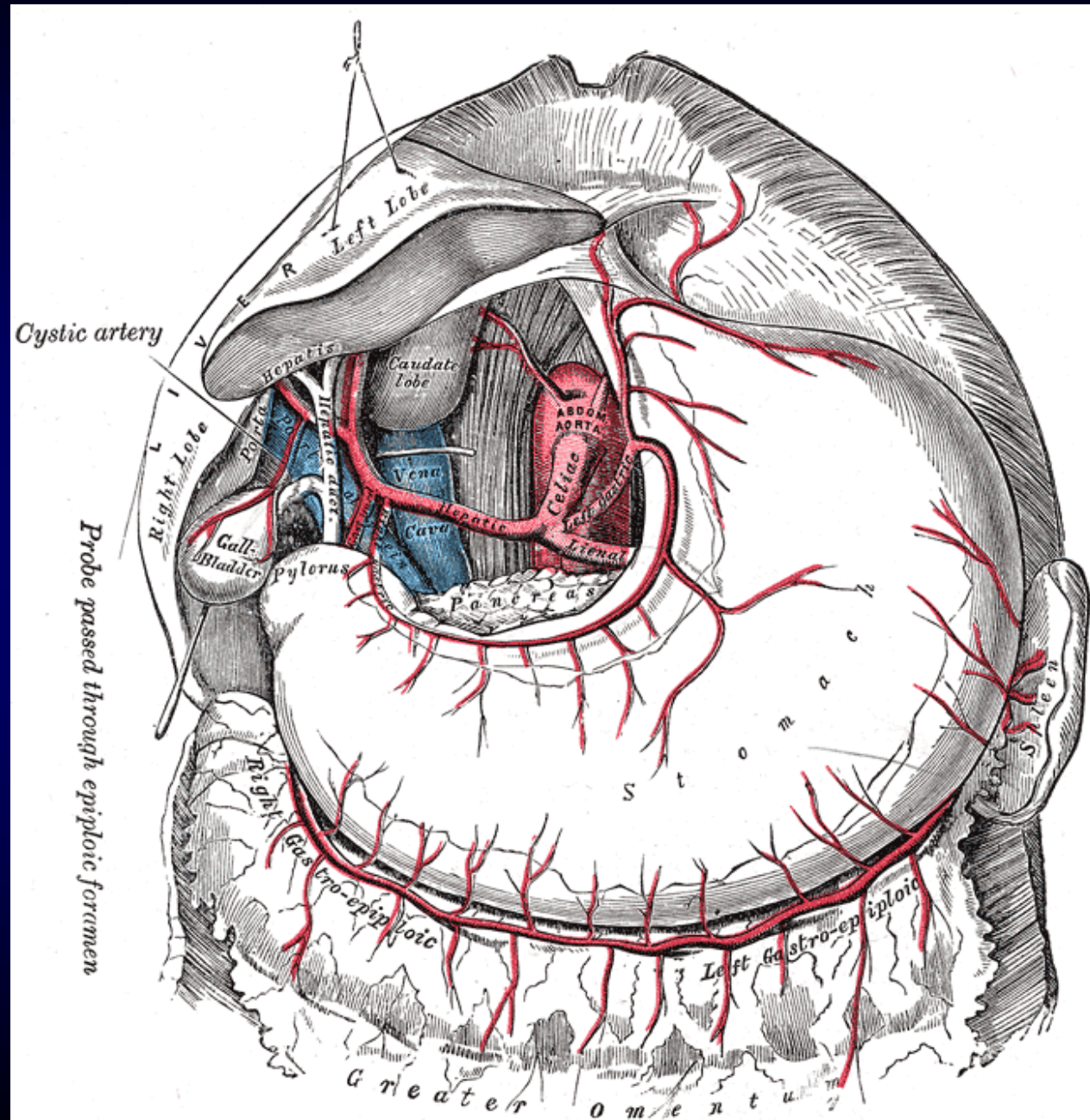
Posteriorly, the lesser sac separates the stomach from the pancreas, (with the splenic artery running its tortuous course along the upper margin of the pancreas), the transverse mesocolon, left kidney, left suprarenal gland and the spleen.

Arterial supply of the stomach (anterior view)

The stomach has a particularly rich blood supply – it is, indeed, the only organ to be supplied from both its sides, along the greater and lesser curvatures. Gastric arteries arise from all three branches of the celiac axis:

The left gastric artery, the largest vessel, is one of the three direct branches of the celiac axis.

The right gastric artery is the first branch of the hepatic artery. (These two vessels lie along the lesser curve).

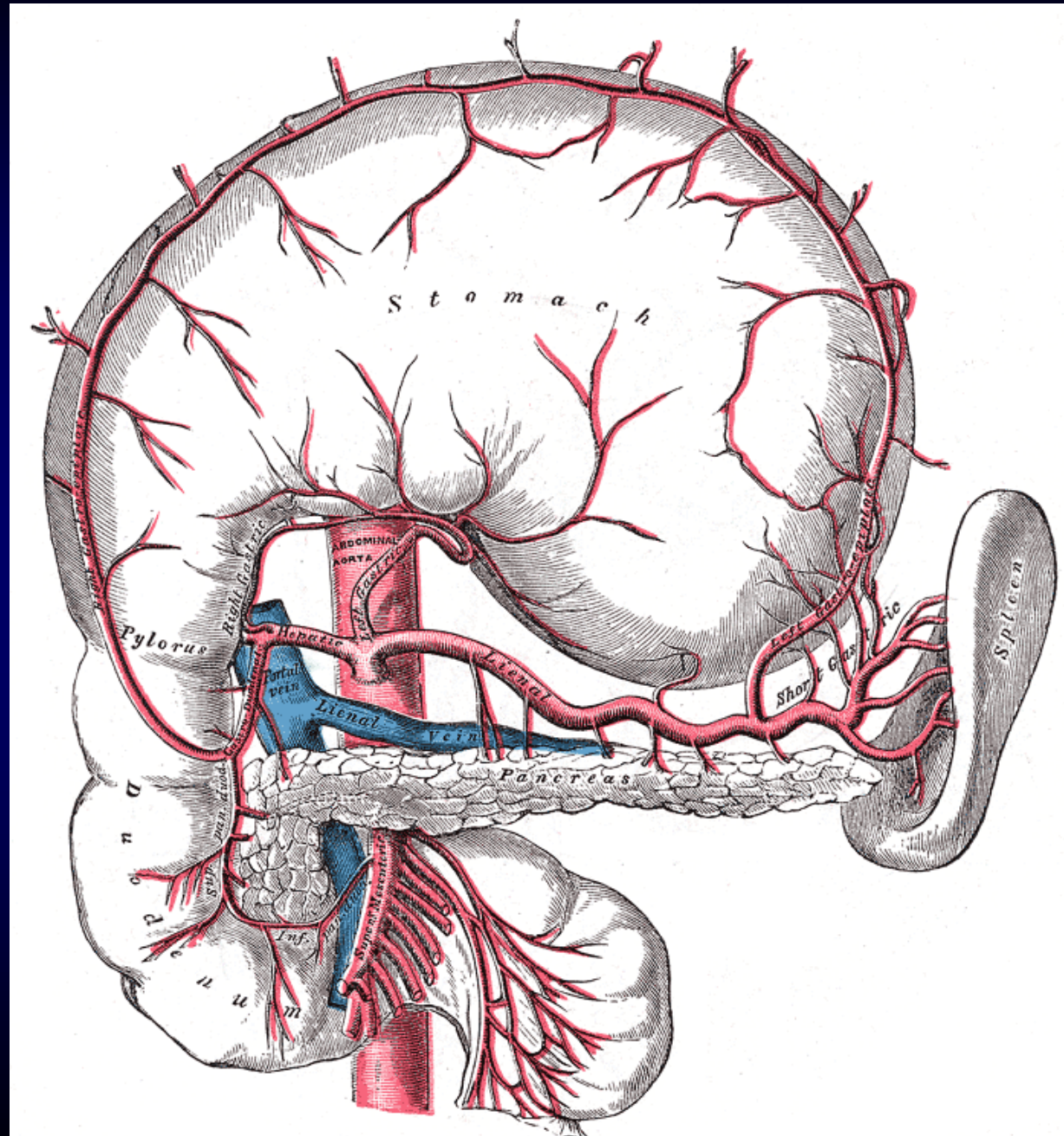


Arterial supply of the stomach (posterior view)

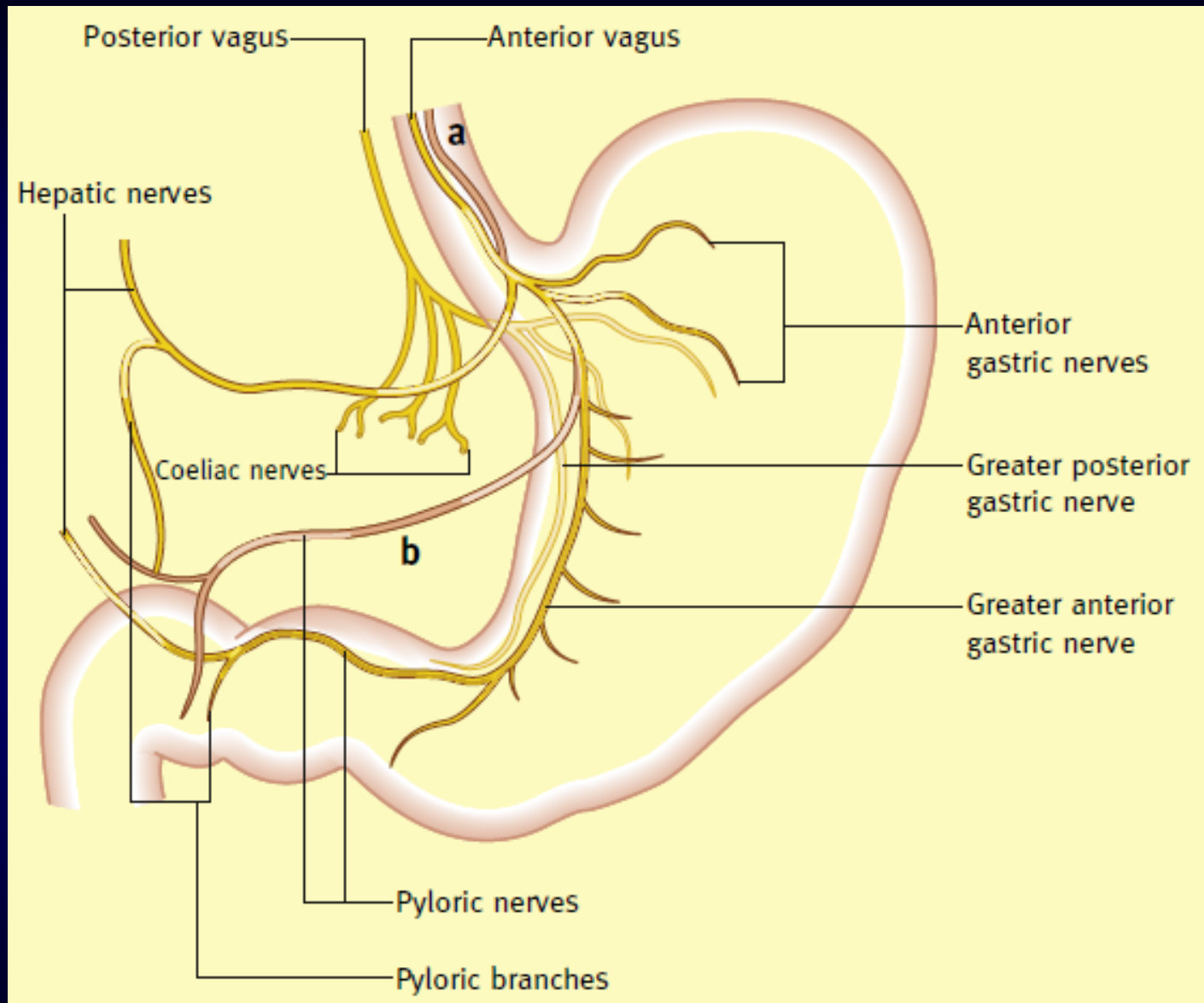
The right gastroepiploic artery arises at the bifurcation of the gastro-duodenal branch of the hepatic artery, (its other branch forming the superior pancreaticoduodenal artery).

The left gastroepiploic artery and the short gastric arteries originate from the splenic artery.

The corresponding veins, running with these vessels, drain into the portal system, mostly either into the splenic or superior mesenteric vein, although some pass directly into the portal vein.



Distribution of the vagal nerves to the stomach



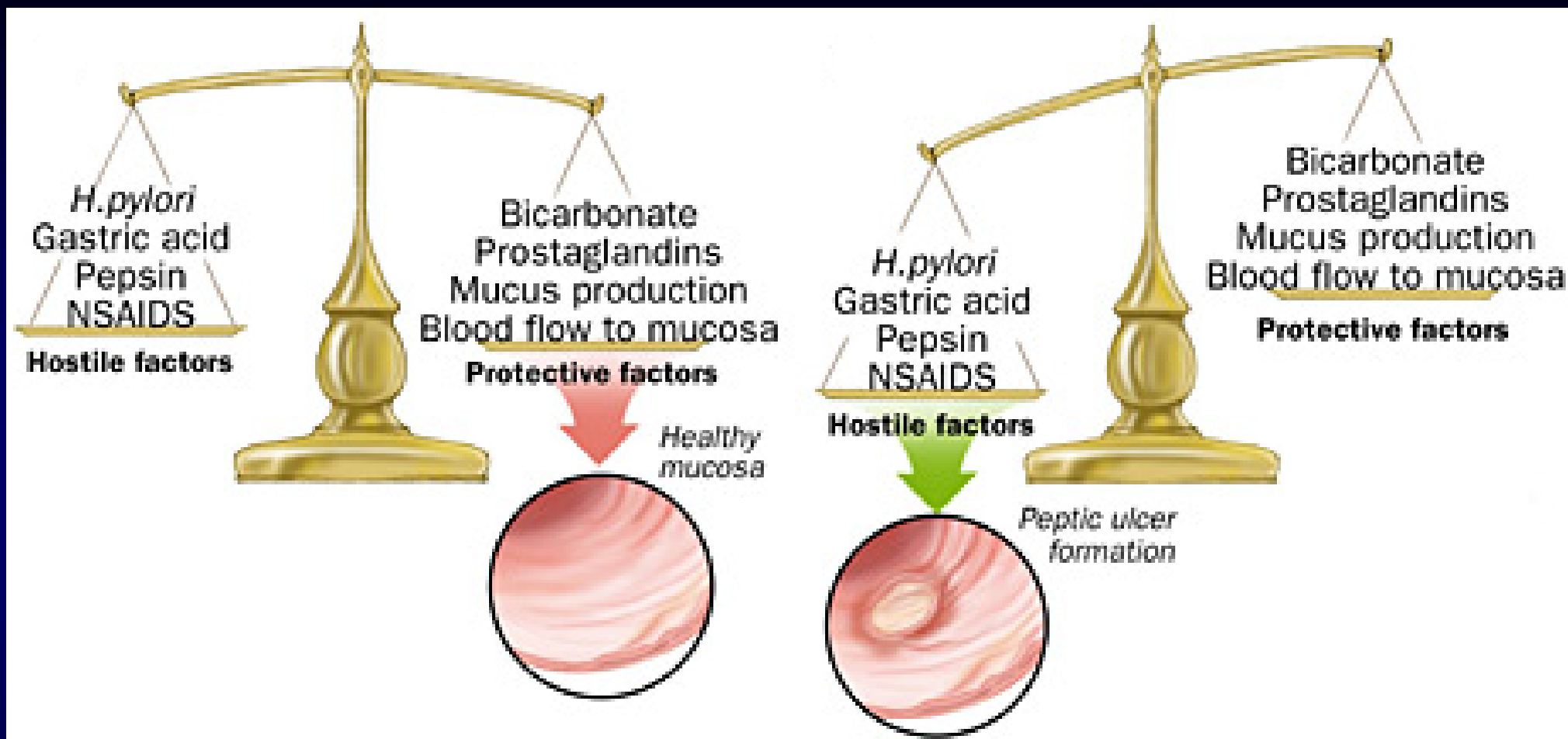
The two commonest variations in the anterior vagus are shown in pink. (a) Multiple main trunks. (b) Low origin of the hepatic/pyloric branch lying close to the lesser curvature.

Gastric acid is produced by parietal (also called oxyntic cells) in the stomach.

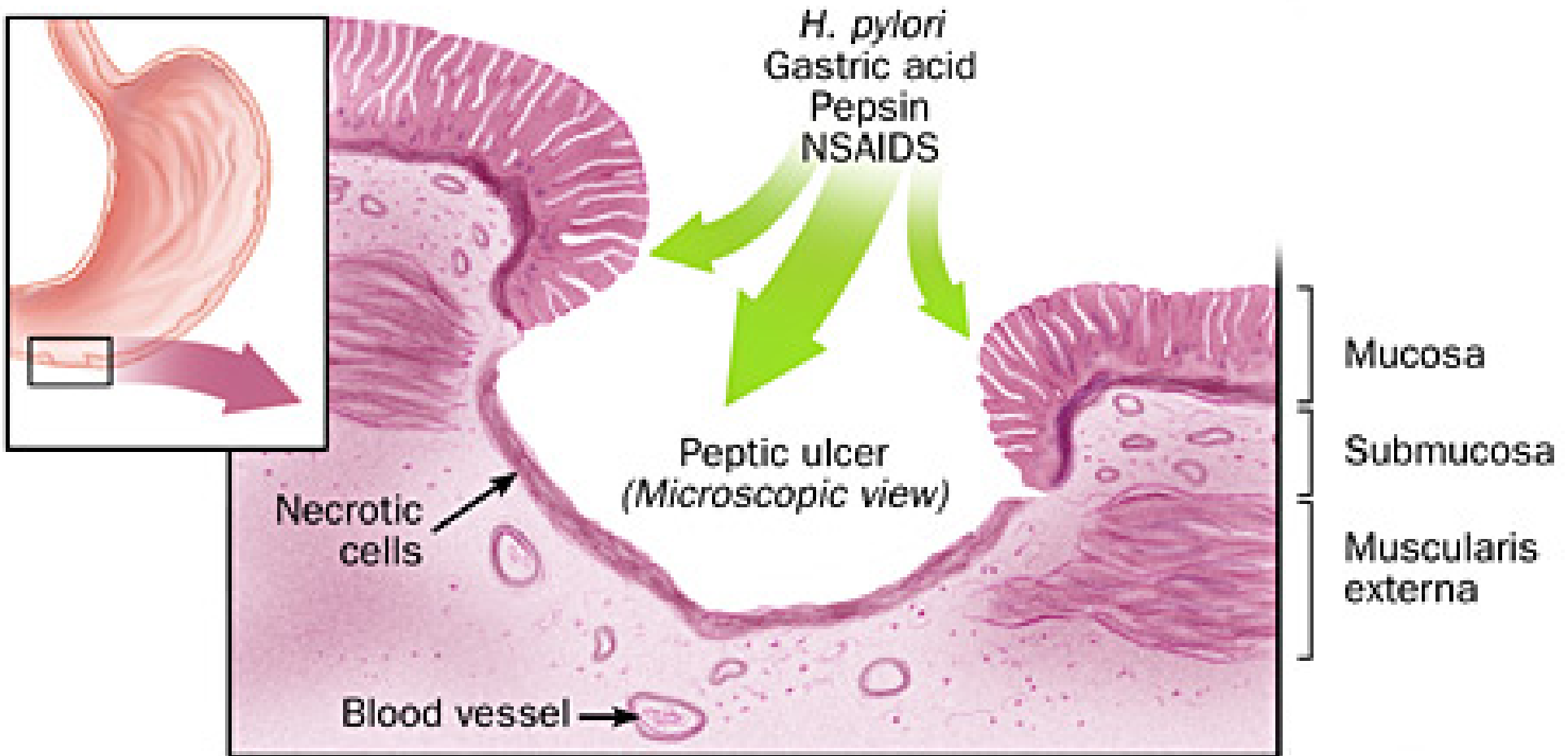
There are three phases in the secretion of gastric acid:

- 1. The cephalic phase: Thirty percent of the total gastric acid secretions to be produced is stimulated by anticipation of eating and the smell or taste of food.**
- 2. The gastric phase: Sixty percent of the acid secreted is stimulated by the distention of the stomach with food. Plus, digestion produces proteins, which causes even more gastrin production.**
- 3. The intestinal phase: The remaining 10% of acid is secreted when chyme enters the small intestine, and is stimulated by small intestine distention.**

There is also a small continuous basal secretion of gastric acid between meals of usually less than 10 mEq/hour.




“No gastric acid, no peptic ulcer” is a misconception. Excessive gastric acid secretion is only one factor in the pathogenesis of peptic ulcer disease. Decreased mucosal defense against gastric acid is another cause. The integrity of the upper gastrointestinal tract is dependent upon the balance between “hostile” factors such as gastric acid, *H. pylori*, NSAIDs and pepsin, and “protective” factors such as prostaglandins, mucus, bicarbonate, and blood flow to mucosa affecting gastrointestinal mucosa.



Injury to gastric and duodenal mucosa develops when deleterious effects of gastric acid overwhelm the defensive properties of the mucosa. **Inhibition** of endogenous **prostaglandin** synthesis leads to a **decrease** in epithelial **mucus**, **bicarbonate secretion**, **mucosal blood flow**, **epithelial proliferation**, and **mucosal resistance to injury**. Lower mucosal resistance increases the incidence of injury by endogenous factors such as acid, pepsin, and bile salts as well as exogenous factors such as NSAIDs, ethanol and other noxious agents

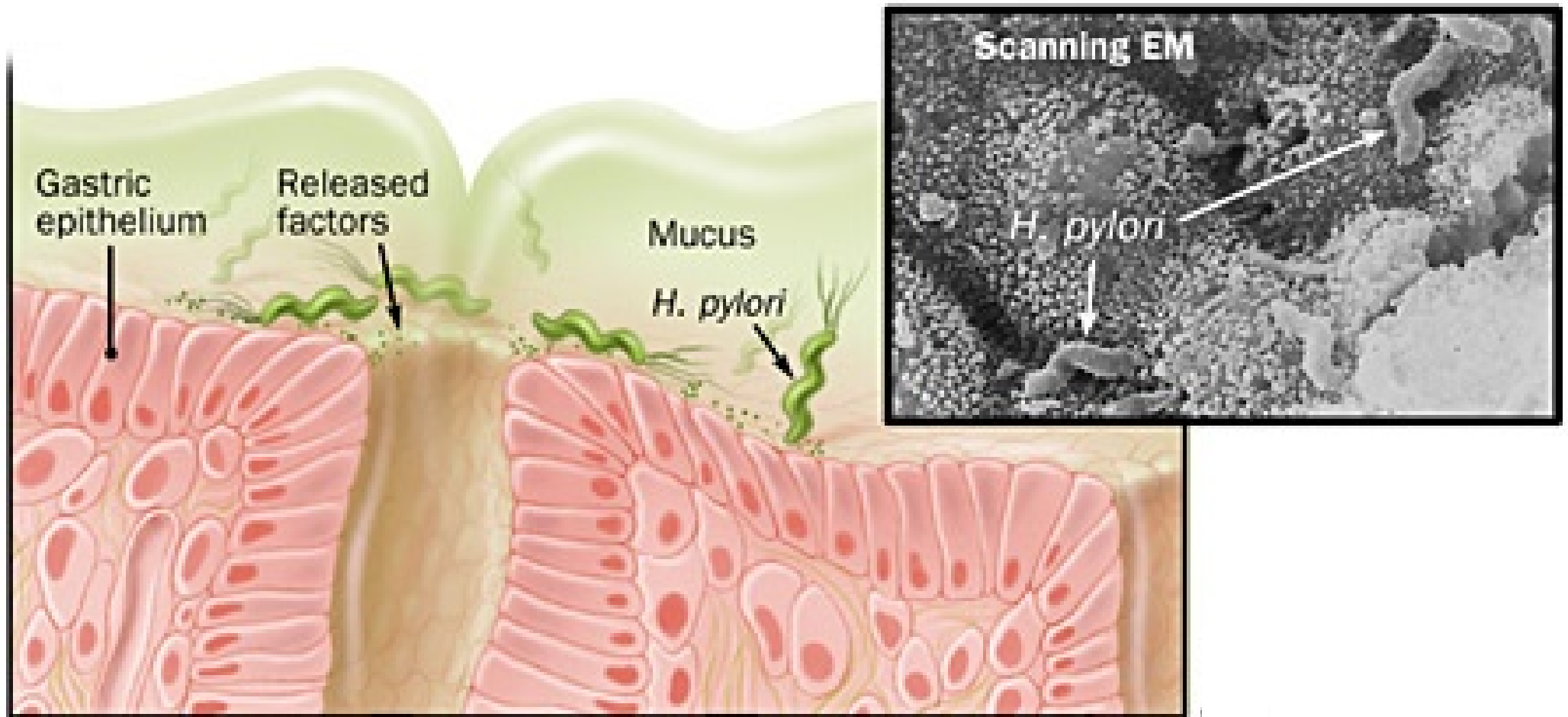


Barry Marshall, AC, FRACP, FRS, FAA, DSc



John Robin Warren, AC

In 2005, **Barry Marshall** and **John Robin Warren** were awarded the **Nobel Prize** in Physiology or Medicine for their discovery that **PUD** was primarily caused by **Helicobacter pylori**, a bacteria with affinity for acidic environments, such as the stomach. As a result, PUD that is associated with *H. pylori* is currently treated with antibiotics used to eradicate the infection.



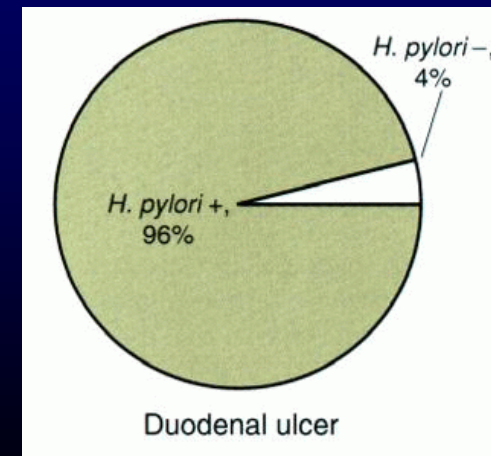
***H. pylori* is the etiologic factor in most patients with peptic ulcer disease and may predispose individuals to the development of gastric carcinoma. *H. pylori* colonizes in the human stomach. The method of *H. pylori* transmission is unclear, but seems to be person-to-person spread via a fecal-oral route. The prevalence of *H. pylori* in adults appears to be inversely related to the socioeconomic status. It is also thought that water is a reservoir for transmission of *H. pylori*.**

Peptic ulcer disease may be due to any of the following:

- ***H pylori* infection (Excluding patients who used NSAIDs, 61% of duodenal ulcers and 63% of gastric ulcers were positive for *H pylori*).**
- **Drugs (NSAID use is a common cause of PUD. These drugs disrupt the mucosal permeability barrier, rendering the mucosa vulnerable to injury. As many as 30% of adults taking NSAIDs have GI adverse effects).**
- **Lifestyle factors (Evidence that tobacco use is a risk factor for duodenal ulcers is not conclusive).**
- **Severe physiologic stress (Cushing ulcers; Curling ulcers).**
- **Hypersecretory states (Gastrinoma (Zollinger-Ellison syndrome) or multiple endocrine neoplasia type I (MEN-I); Antral G cell hyperplasia; Systemic mastocytosis; Basophilic leukemias; Cystic fibrosis; Short bowel syndrome; Hyperparathyroidism) (uncommon).**
- **Genetic factors (More than 20% of patients have a family history of duodenal ulcers).**

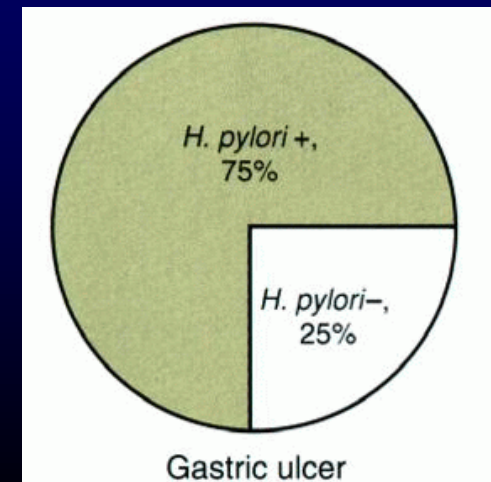
Duodenal Ulcers

- Duodenal sites are 4x as common as gastric sites
- Most common in middle age – peak 30-50 years
- Male to female ratio – 4:1
- Genetic link: 3x more common in 1st degree relatives
- More common in patients with blood group O
- Associated with increased serum pepsinogen
- *H. pylori* infection common – up to 95%
- Smoking is twice as common

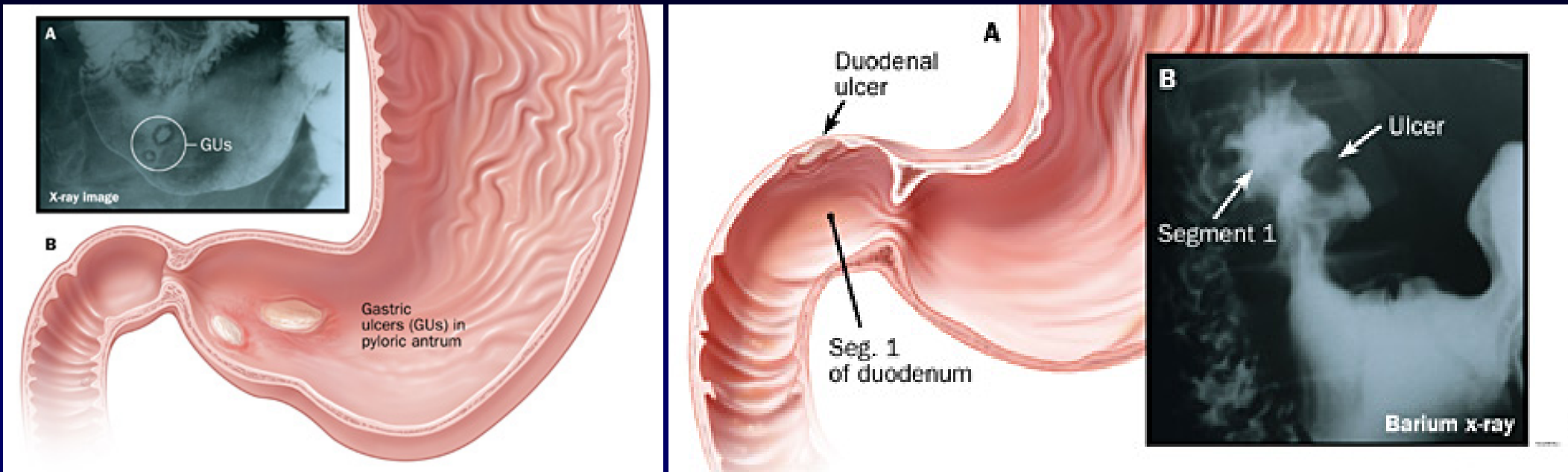


Gastric Ulcers

- Common in late middle age – incidence increases with age
- Male to female ratio—2:1
- More common in patients with blood group A
- Use of NSAIDs - associated with a three- to four-fold increase in risk of gastric ulcer
- Less related to *H. pylori* than duodenal ulcers – about 80%
- 10 - 20% of patients with a gastric ulcer have a concomitant duodenal ulcer

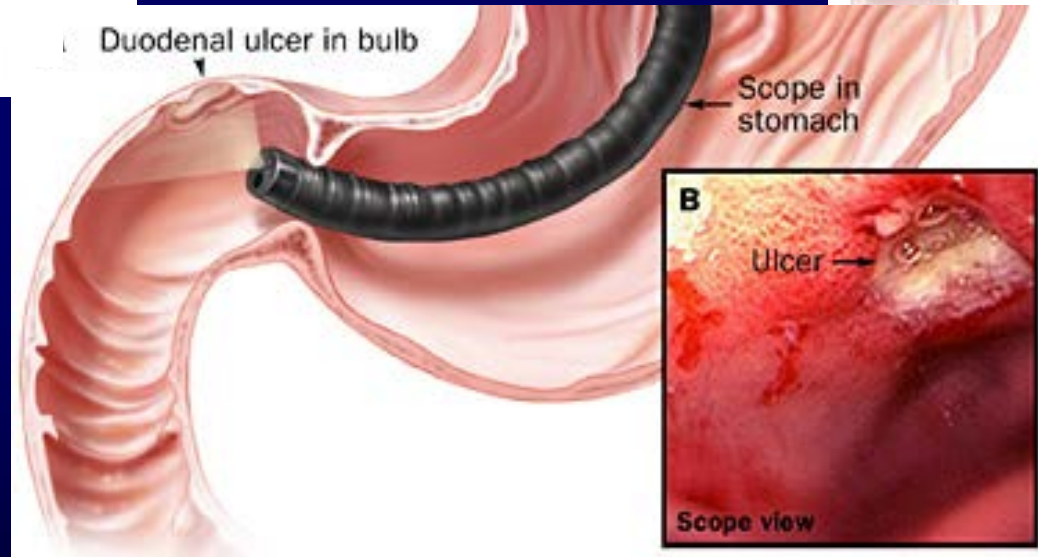
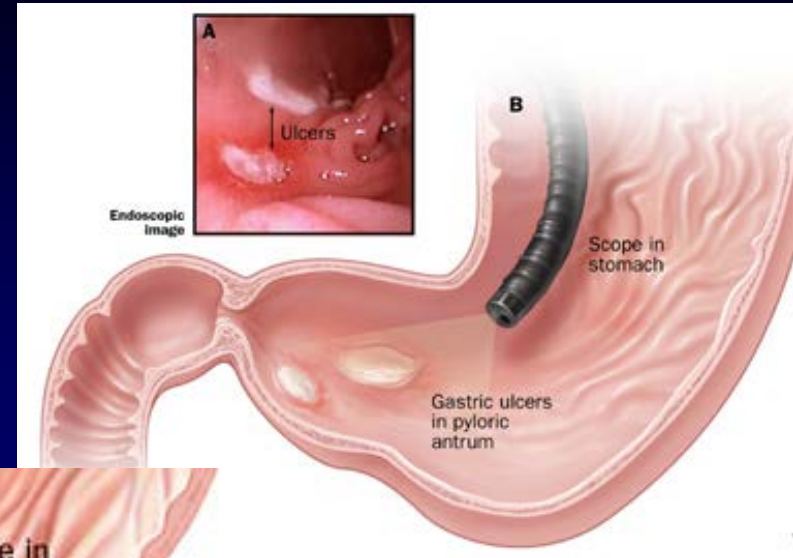
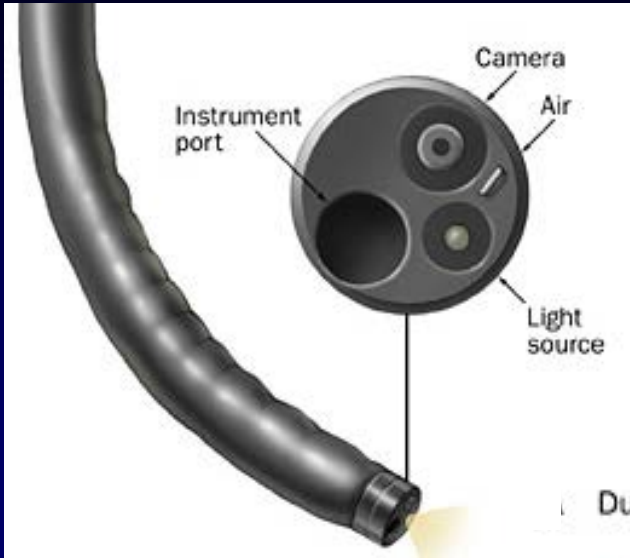

Barium x-ray or upper GI series is a widely available and accepted method to establish a diagnosis of peptic ulcer in the stomach or duodenum.



Though less invasive than endoscopy, the barium x-ray is limited by being less sensitive and accurate at defining mucosal disease, or distinguishing benign from malignant ulcer disease. In patients who have anatomic deformities from previous gastric surgery or scarring from chronic inflammation, barium x-rays may be difficult to interpret. Generally, these x-rays have up to a **30% false negative and a 10% false positive rate. Until 1970, peptic ulcers were diagnosed almost exclusively by radiological methods. The most common inaccuracies of radiological diagnosis include the failure to recognize true ulcers, or the misdiagnosis of a scar or a deformed duodenal bulb as a true ulcer. Since the 1970s, increasing numbers of peptic ulcers are diagnosed by endoscopy.**

Esophagogastroduodenoscopy (EGD) is the most direct and accurate method of establishing the diagnosis of peptic ulcer disease.



In addition to identifying the ulcer, its location and size, EGD also provides an opportunity to detect subtle mucosal lesions and to biopsy lesions to establish histopathological basis. Endoscopic biopsies are indicated for all gastric ulcers at the time of diagnosis, whereas duodenal ulcers are almost always benign, not requiring biopsy in usual circumstances.

Diagnostic Tests for *Helicobacter pylori*

Test	Sensitivity (%)	Specificity (%)	Usefulness
Invasive			
Endoscopy with biopsy			Diagnostic strategy of choice in children with persistent or severe upper abdominal symptoms
Histology	> 95	100	Sensitivity reduced by PPIs, antibiotics, and bismuth-containing compounds
Urease activity	93 to 97	> 95	Sensitivity reduced by PPIs, antibiotics, bismuth-containing compounds, and active bleeding
Culture	70 to 80	100	Technically demanding
Noninvasive			
Serology for immunoglobulin G	85	79	Sensitivity and specificity vary widely; positive result may persist for months after eradication Reliability in children not adequately validated; not recommended
Urea breath test	95 to 100	91 to 98	Requires separate appointments; sensitivity reduced by PPIs, antibiotics, and bismuth-containing compounds; reliable test for cure Best available noninvasive test in children but higher false-positive rates in infants and children younger than six years compared with school-age children and adolescents
<i>H. pylori</i> stool antigen	91 to 98	94 to 99	Test for cure seven days after therapy is accurate; sensitivity reduced by PPIs, antibiotics, and bismuth-containing compounds Easy to perform independent of age; possible alternative to urea breath test; monoclonal antibody-based test most reliable

PPI = proton pump inhibitor.

Selected Long-Duration Regimens for *Helicobacter pylori* Eradication

<u>Treatment regimen</u>	<u>Duration</u>	<u>Eradication rate (%)</u>	<u>Cost (generic) per day*</u>
Omeprazole (Prilosec), 20 mg twice daily, <i>plus</i> amoxicillin, 1 g twice daily, <i>plus</i> clarithromycin (Biaxin), 500 mg twice daily	14 days	80 to 86	Omeprazole: \$9 (8) Amoxicillin: \$2 (2 to 3) Clarithromycin: \$10 (9)
Lansoprazole (Prevacid), 30 mg twice daily, <i>plus</i> amoxicillin, 1 g twice daily, <i>plus</i> clarithromycin, 500 mg twice daily	10 to 14 days	86	Lansoprazole: \$10 Amoxicillin: \$2 (2 to 3) Clarithromycin: \$10 (9)
Bismuth subsalicylate (Pepto-Bismol), 525 mg four times daily, <i>plus</i> metronidazole (Flagyl), 250 mg four times daily, <i>plus</i> tetracycline, 500 mg four times daily, <i>plus</i> histamine H ₂ blocker	14 days (H ₂ blocker alone for an additional 14 days taken once or twice daily)	80	Bismuth subsalicylate: \$1 Metronidazole: \$10 (2) Tetracycline: \$2 (1)

*Estimated cost to the pharmacist based on average wholesale prices (rounded to the nearest dollar) in Red Book. Montvale, N.J.: Medical Economics Data, 2006. Cost to the patient will be higher, depending on prescription filling fee.

Adapted with permission from Meurer LN, Bower DJ. Management of *Helicobacter pylori* infection. *Am Fam Physician* 2002;65:1333.

Until recently, the recommended duration of therapy for *H. pylori* eradication was 10 to 14 days.

Although not proven, potential benefits of shorter regimens include better compliance, fewer adverse drug effects, and reduced cost to the patient.

By Region/Location

- Duodenal
- Gastric
- Acute (< 1 cm)
- Chronic (2-5 cm for the stomach and 1-2 cm for the duodenum)

- Stressful conditions that may cause PUD include burns, CNS trauma, surgery, and severe medical illness.
- Serious systemic illness, sepsis, hypotension, respiratory failure, and multiple traumatic injuries increase the risk for secondary (stress) ulceration.
- **Cushing ulcers** are associated with a **brain tumor or injury** and typically are single, deep ulcers that are **prone to perforation**. They are associated with high gastric acid output and are located in the duodenum or stomach.
- **Extensive burns** are associated with **Curling ulcers**.
- Zollinger-Ellison syndrome

Modified **Johnson Classification** of peptic ulcers:

- **Type I:** Ulcer along the body of the stomach, most often along the lesser curve at incisura angularis along the locus minoris resistentiae.
- **Type II:** Ulcer in the body in combination with duodenal ulcers. Associated with acid oversecretion.
- **Type III:** In the pyloric channel within 3 cm of pylorus. Associated with acid oversecretion.
- **Type IV:** Proximal gastroesophageal ulcer
- **Type V:** Can occur throughout the stomach. Associated with chronic NSAID use (such as aspirin).



Now it is time to have a break

Peptic Ulcer Perforation

Perforated peptic ulcers are now most commonly seen in elderly patients, particularly women, the majority of which are attributable to NSAID use.

Primrose JN. Stomach and duodenum. In: Russell RCG, Williams NS, Bulstrode CJK, eds. Bailey and love's short practice of surgery. London: Hodder Arnold, 2004; 1026-1061.

- Overall incidence for admission with peptic ulceration is falling
- **The number of perforated ulcers remains unchanged**
- Sustained incidence possibly due to increased NSAID in elderly
- **80% of perforated duodenal ulcers are *H. pylori* positive**

The annual incidence of perforated peptic ulcer estimates 3.8-14.0/100,000 population.

Lau JY., et al.: Digestion 2011; 84:102-13.

Classification

BY ORIGIN

PERFORATION OF THE ACUTE ULCER

PERFORATION OF THE CHRONIC ULCER

BY LOCALIZATION

PERFORATION OF THE DUODENAL ULCER

PERFORATION OF THE GASTRIC ULCER

BY EVOLUTION

PERFORATION INTO THE PERITONEAL CAVITY

ATYPICAL PERFORATION

SEALED PERFORATION

- **EARLY - STAGE OF SHOCK**
- **INTERMEDIATE – STAGE OF THE FALSE IMPROVEMENT**
- **LATE – STAGE OF PERITONITIS**

- **Sudden onset of pain “knife-like pain”**
- ***Pain localization:* epigastric area, right subcostal area, left subcostal area, top part of abdomen, lower part of abdomen, left half of abdomen, right half of abdomen, the whole abdomen.**
- ***Pain irradiation:* right shoulder, left shoulder, right scapula, left scapula, left clavicle.**
- **Vomiting is uncommon**

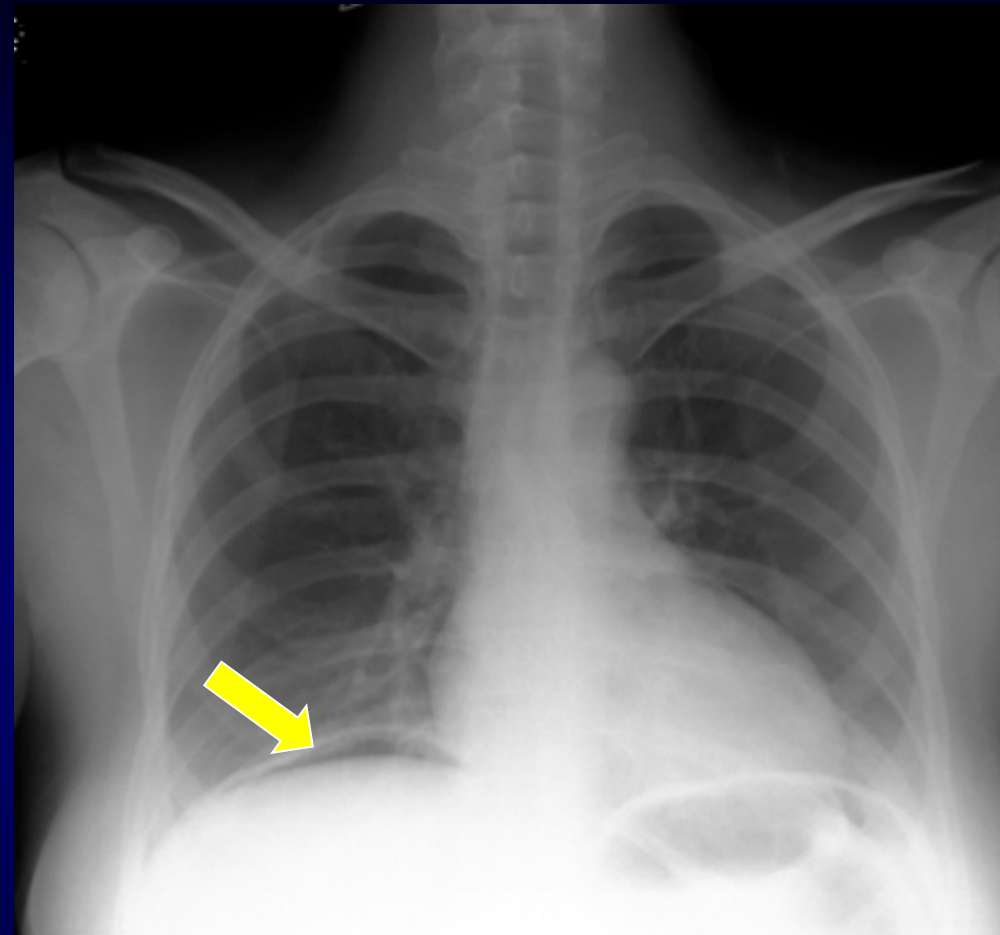
Physical examination:

- Abdominal wall rigidity – “board-like” abdomen
- Triad of Mondor – Pain, Tenderness, PUD history
- Blumberg sign – also referred as rebound tenderness. Deep palpation of the anterior abdominal wall followed by sudden release of the pressure causes the severe pain.
- Clarke sign – upon percussion of the abdomen absence of the liver dullness (pneumoperitoneum).
- Mendel sign – upon percussion of the abdomen pain increases.
- Kerven sign – shiftable dullness in the right iliac region as well as pain in this region.

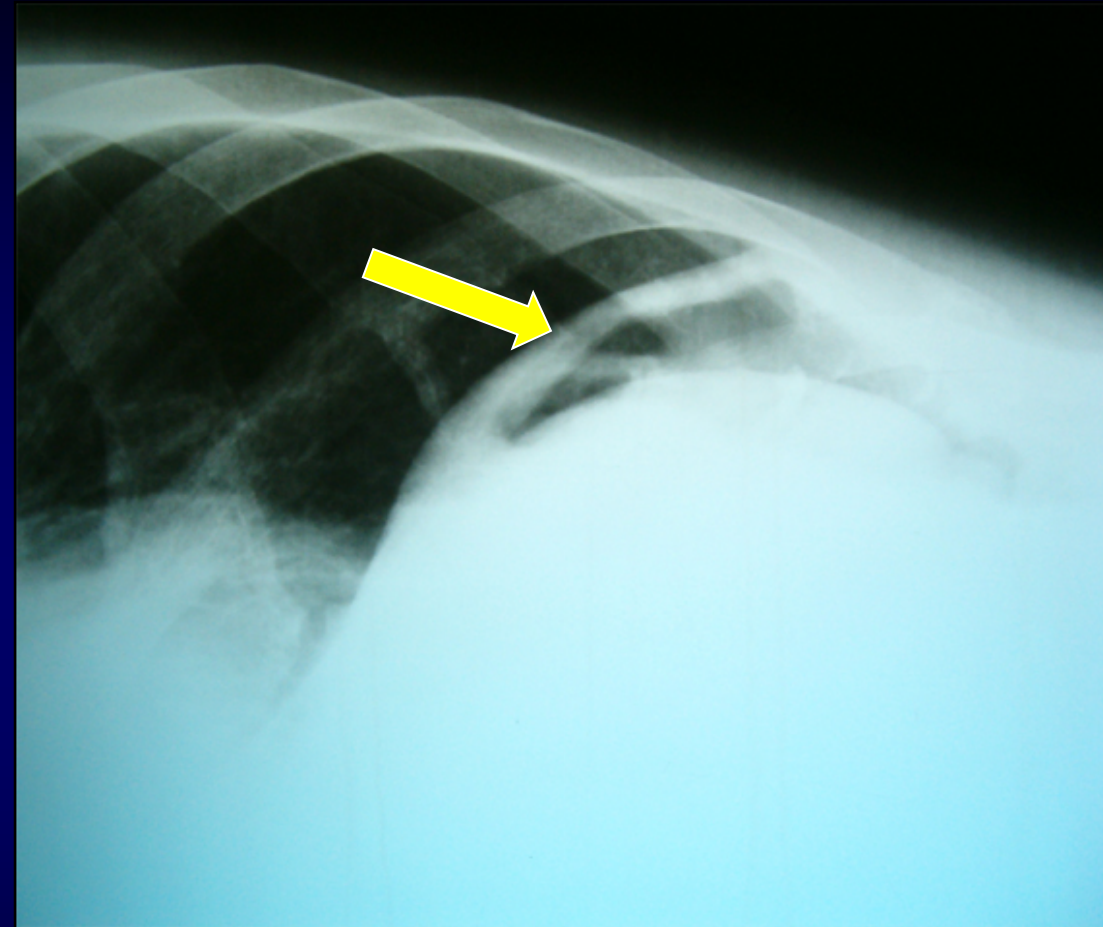
Physical examination:

- **Kulenkampf-Grassman sign – pain increases in intensity upon rectal examination (fluid in the Douglas space).**
- **Eleker sign – pain in the epigastria, right upper quadrant, right clavicle or scapula.**
- **Ratner-Vikker sign – in case of sealed perforation, after a sudden onset of pain, general improvement but RUQ tenderness and pain persists.**
- **Vighiatto sign – posterior duodenal wall perforation – periumbilical subcutaneous emphysema (gas spreads through the round ligg.).**
- **Podlah sign – perforation of a posterior located cardia ulcer – left-sided emphysema in the supraclavicular region.**

Only approximately 50% of patients will have visible sub-diaphragmatic gas on a plain erect chest X-ray

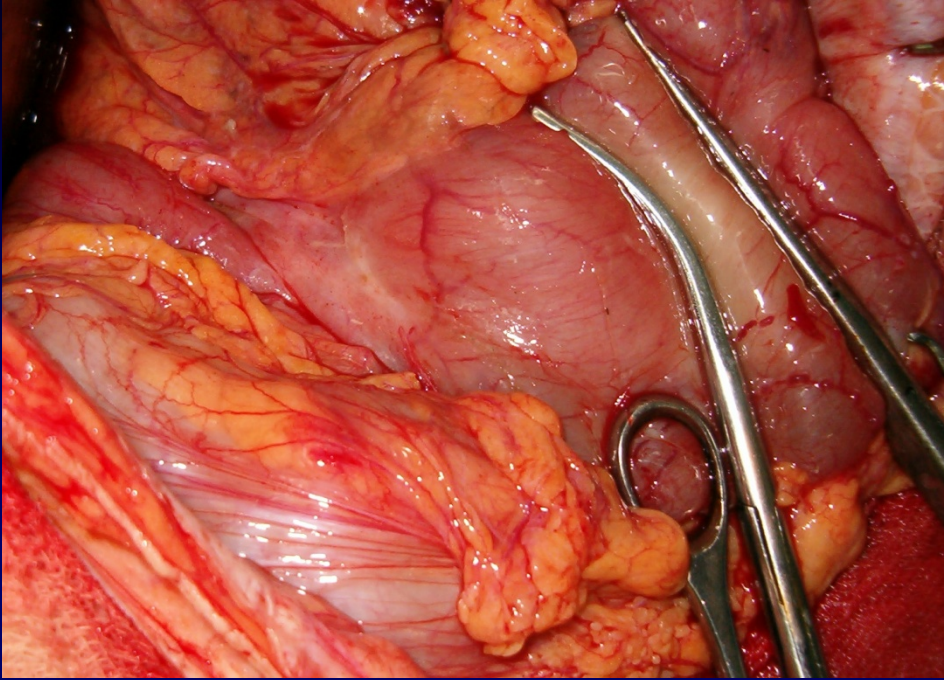


Upright simple upper abdominal and chest x-ray – pneumoperitoneum (arrow) under the right diaphragm)

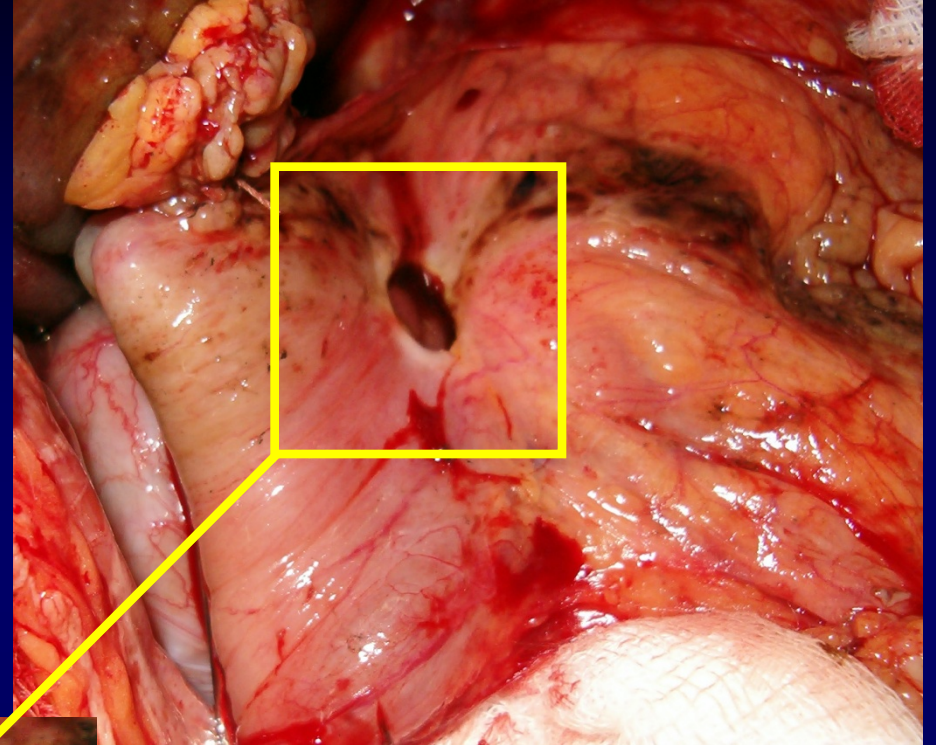


Lateral simple abdominal and chest x-ray – pneumoperitoneum (arrow) under the left diaphragm)

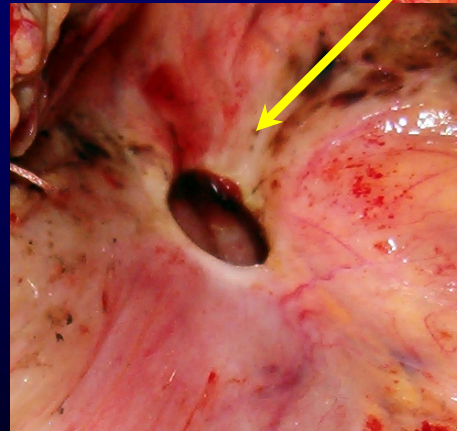
Free air is not detected by x-ray in 25-35% of perforated duodenal ulcers



Pyloric region anterior wall



Pyloric region - posterior wall with ulcer perforation in the lesser sac



ULCER PERFORATION: ATYPICAL PERFORATION

It is postulated that gastrointestinal (GI) endoscopy is contraindicated in patients with suspected perforated ulcer.

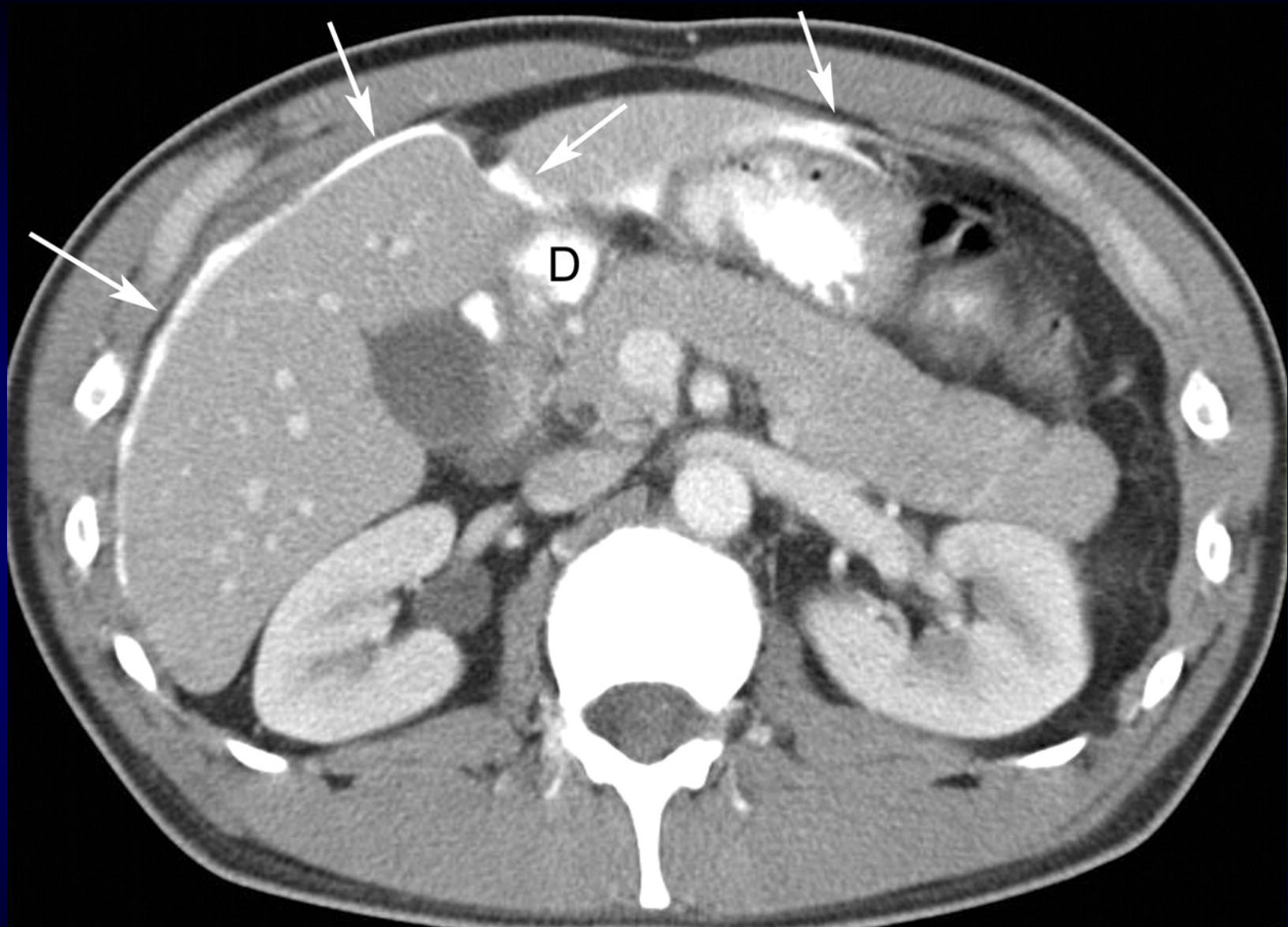
There is clear precedent for the nonoperative management of peptic ulcer perforation.

**Wangensteen OH. Minn Med. 1935;18:477-478.
Berne TV., et al.: Arch Surg. 1989;124:830-832.
Crofts TJ., et al.: N. Engl J Med. 1989;320:970-973.**

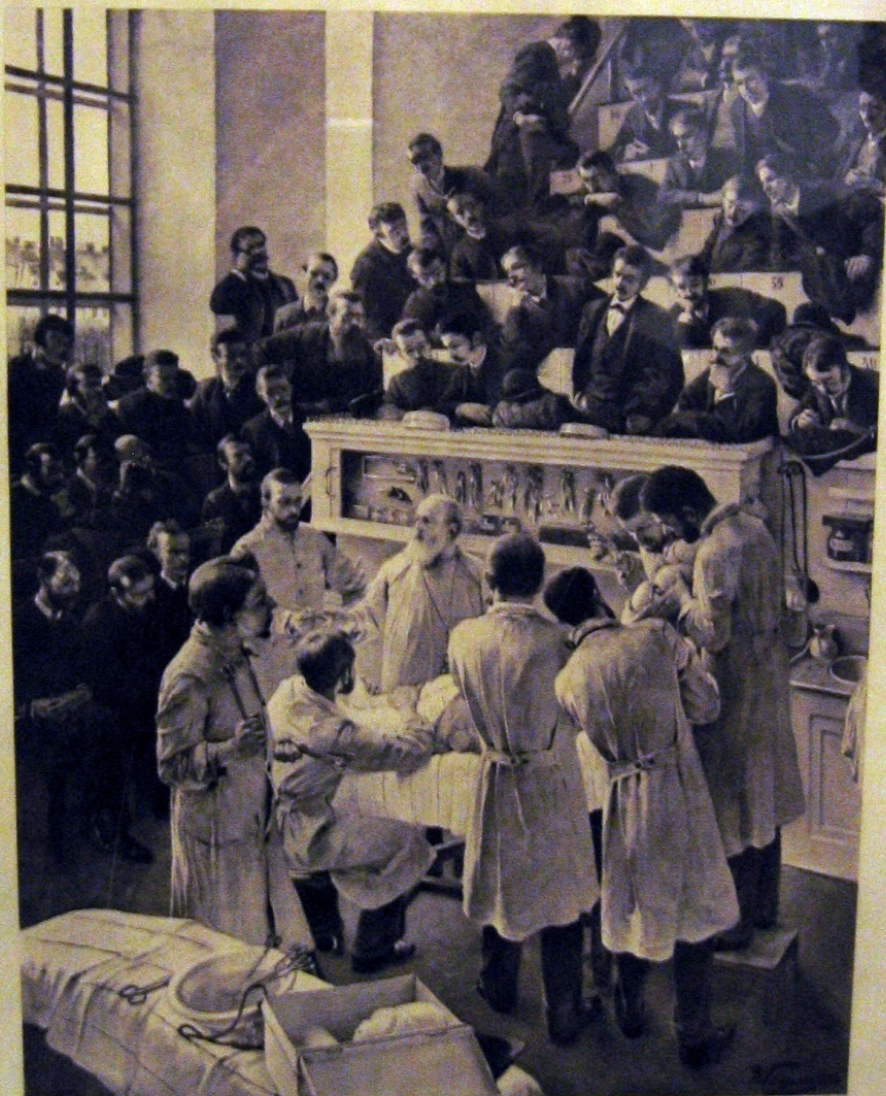Patients who present with small amounts or no free air visible under the diaphragms on upright chest film and who are stable clinically may undergo upper GI contrast study.

If no leak is identified, there is no reason why upper endoscopy could not be part of the diagnostic evaluation of such patients if clinical improvement occurred with supportive care including intravenous fluids and systemic antibiotics, and if sufficient time elapsed to be certain that a strong seal of the perforation had occurred.

Patients who harbor significant comorbid conditions or who are unstable are probably best treated with aggressive resuscitation and early operation.

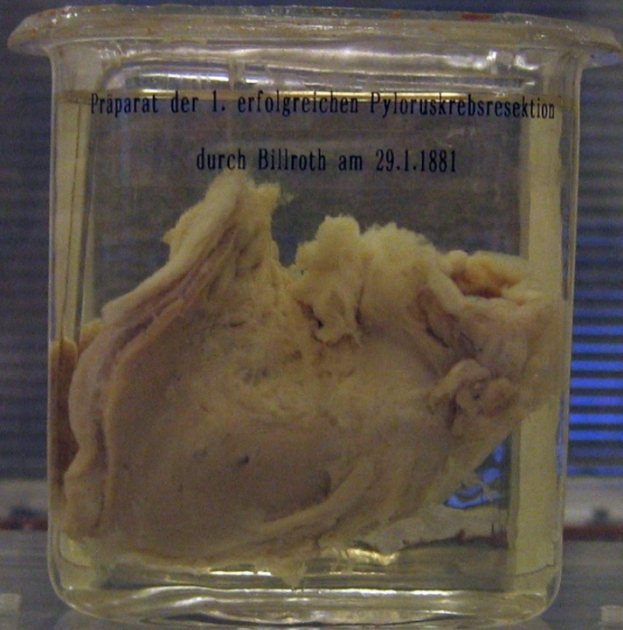

Axial CT scan shows oral contrast material extravasation in perihepatic space (arrows), which leaked from perforated duodenum (D).



THEODOR BILLROTH
1829 — 1894

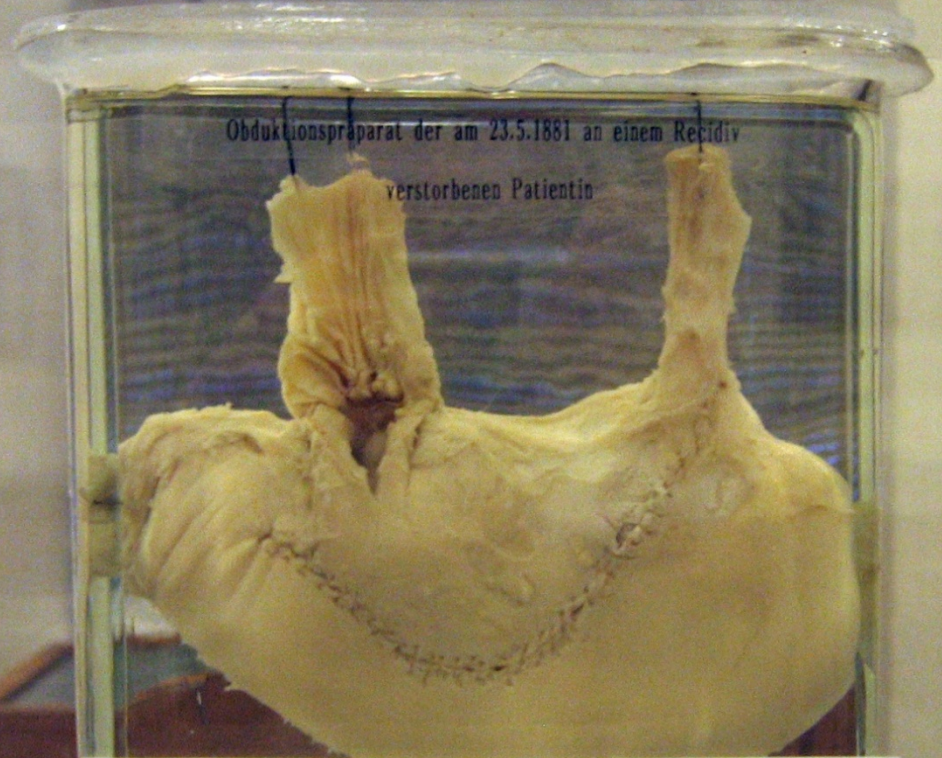
29.01.1881 First successful gastric resection (Theodor Billroth)



Präparat der 1. erfolgreichen Pyloruskrebsresektion
durch Billroth am 29.1.1881



Operationspräparat, herausgeschnittenes Magenkrebsgeschwür
Surgical specimen, a resected stomach carcinoma



Obduktionspräparat der am 23.5.1881 an einem Recidiv
verstorbenen Patientin

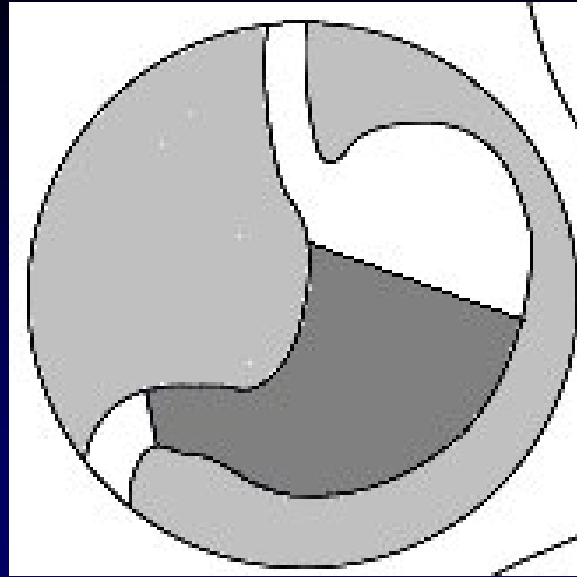
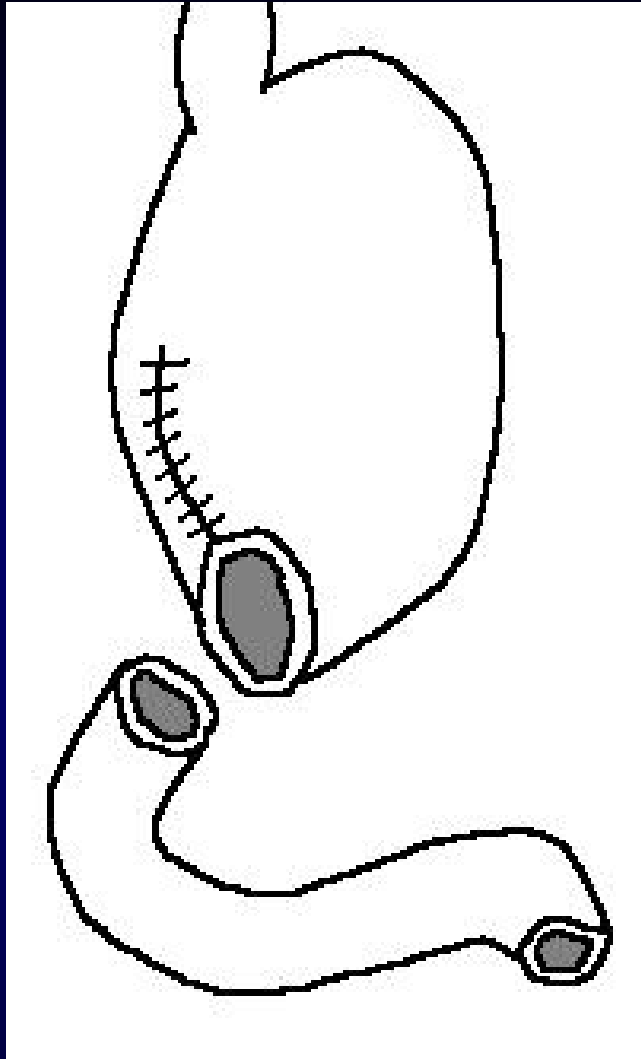


Obduktionspräparat: die Patientin starb 3 Monate nach der
Operation an den Folgen von Metastasen.

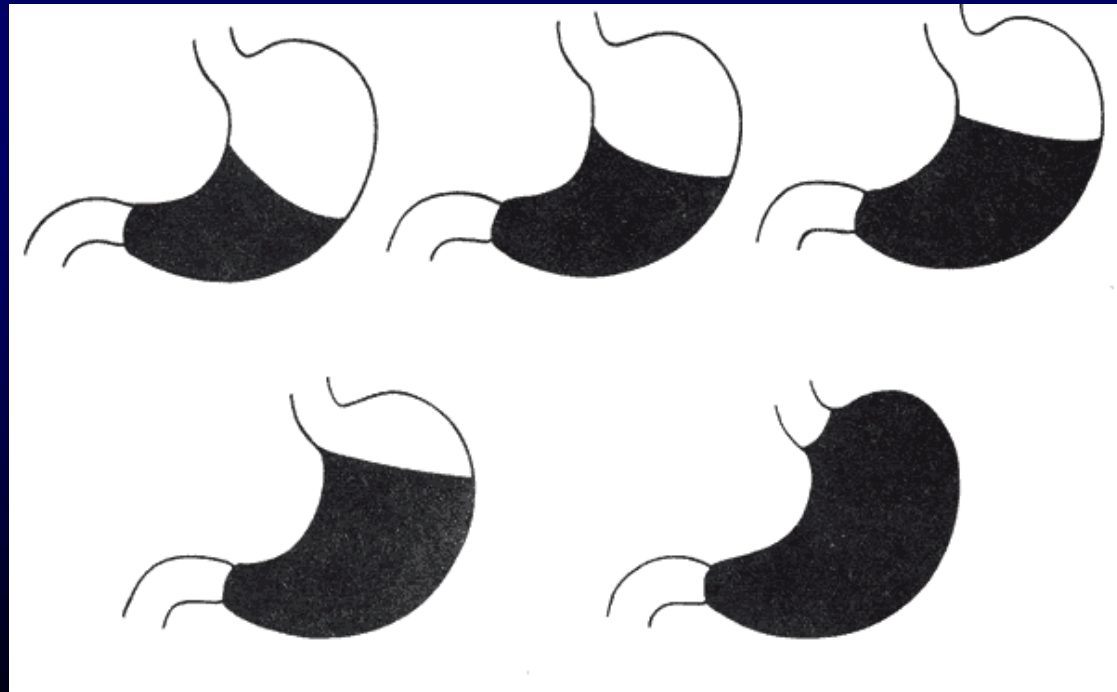
Dissection specimen: the patient died 3 months after the surgery as a
consequence of metastases.



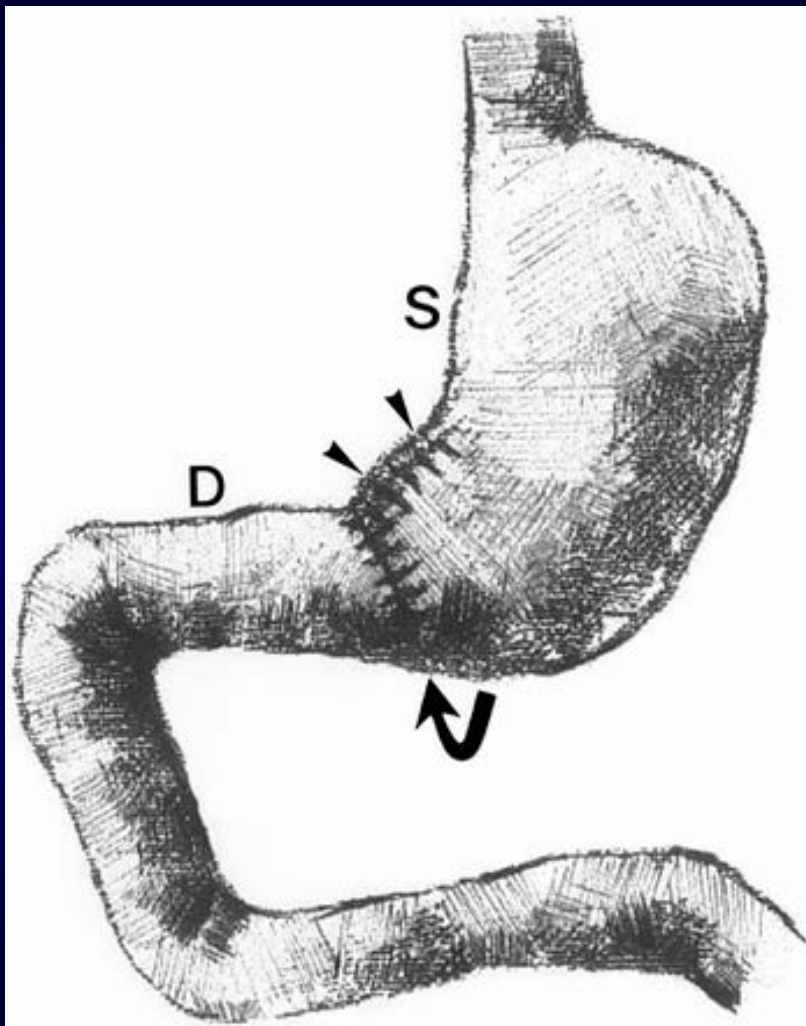
The patient died 3 month later due to metastases



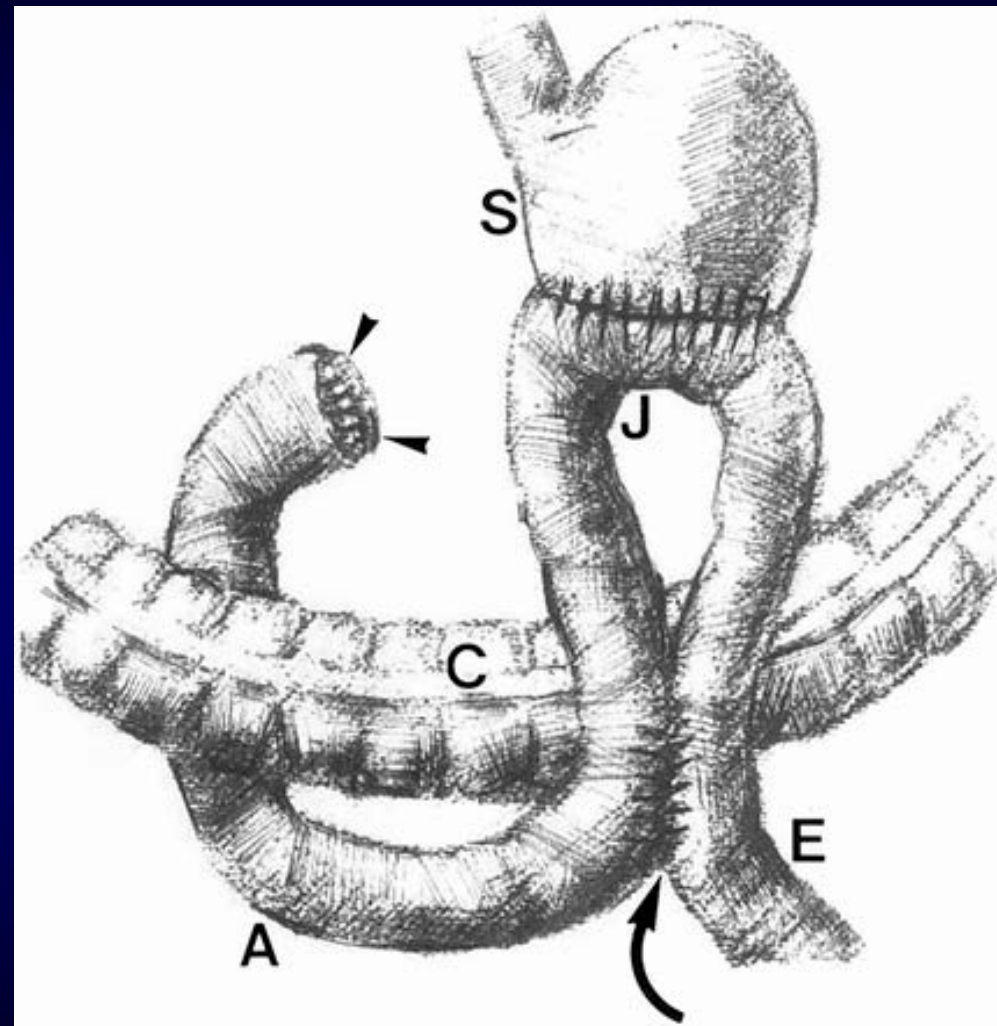
- **BILLROTH, 1881**
- **PEAN, 1879**
- **RYDYGIER, 1881**



GR PEAN-BILLROTH I



GR BILLROTH II



BALFOUR

Recent reports confirm that omental patch closure of peptic ulcer perforations, combined with medical therapy for acid hypersecretion and *Helicobacter pylori*, yield excellent results with low recurrence rates.

Ng EKW., et al.: *Ann Surg.* 2000;231:153-158.

Feliciano DV., et al. *Ann Surg.* 1999;229:801-804, discussion 804-806.

Similar operations may be completed using the laparoscope.

Wing TS., et al.: *Ann Surg.* 2002;235:313-326.

While endoscopic therapies using ligation and clipping techniques have been very successful in the management of upper GI hemorrhage, few reports are available that support the use of these avenues in the management of typical peptic ulcer perforation. Those that are available cite significant mortality and complications.

Hashiba K., et al.: *Gastrointest Endosc.* 2001;54:500-504.

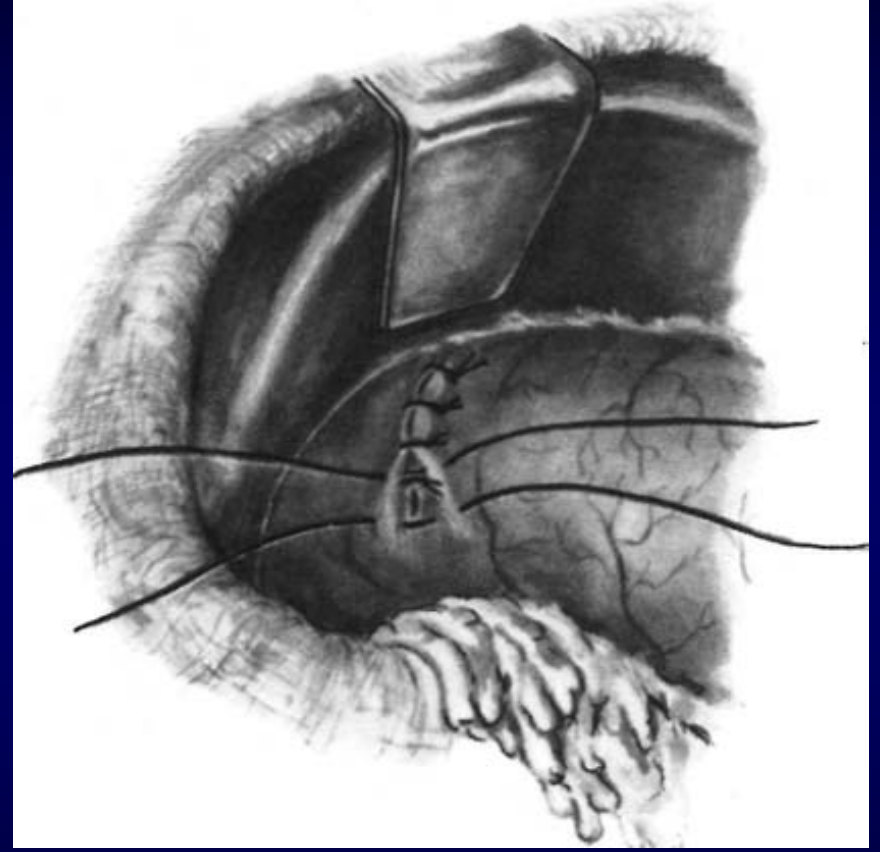
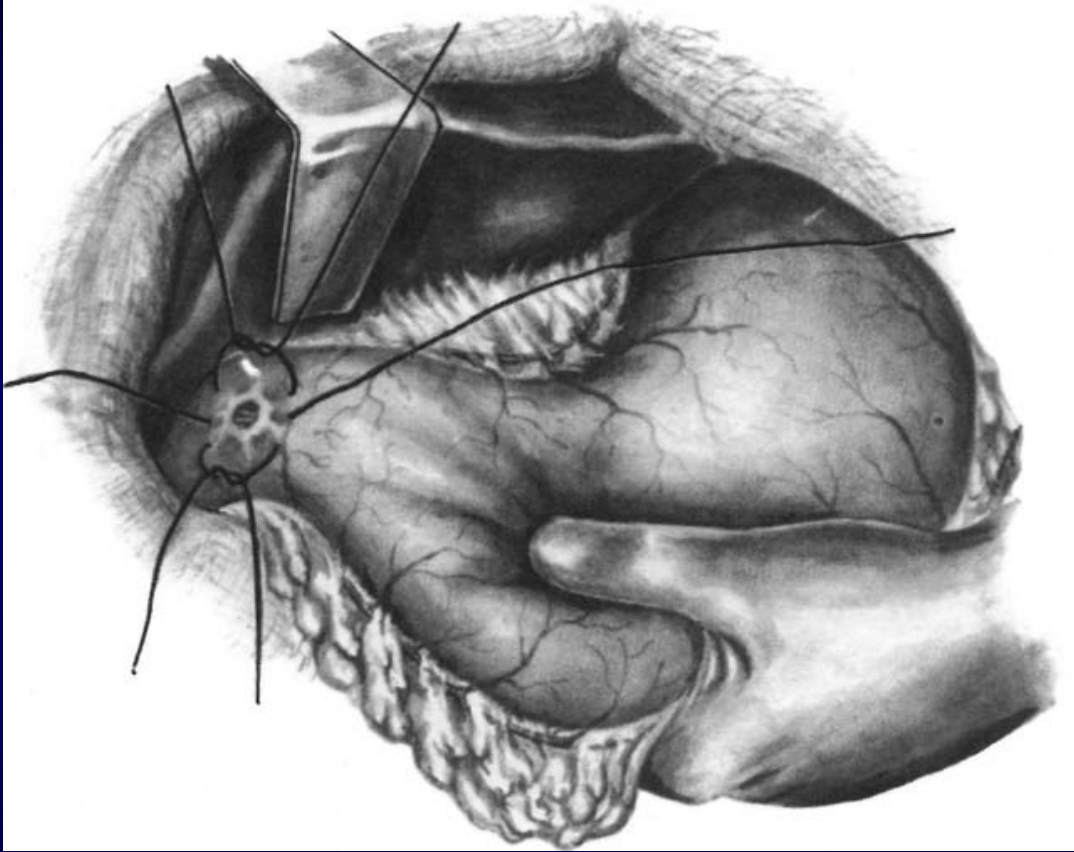
Ishiguro T., et al.: *Gastrointest Endosc.* 2001;53:378-379.

Potential risk for spreading contamination and increasing pneumoperitoneum in the decision not to utilize early endoscopy for diagnosis or therapy for the typical patient with peptic ulcer perforation.

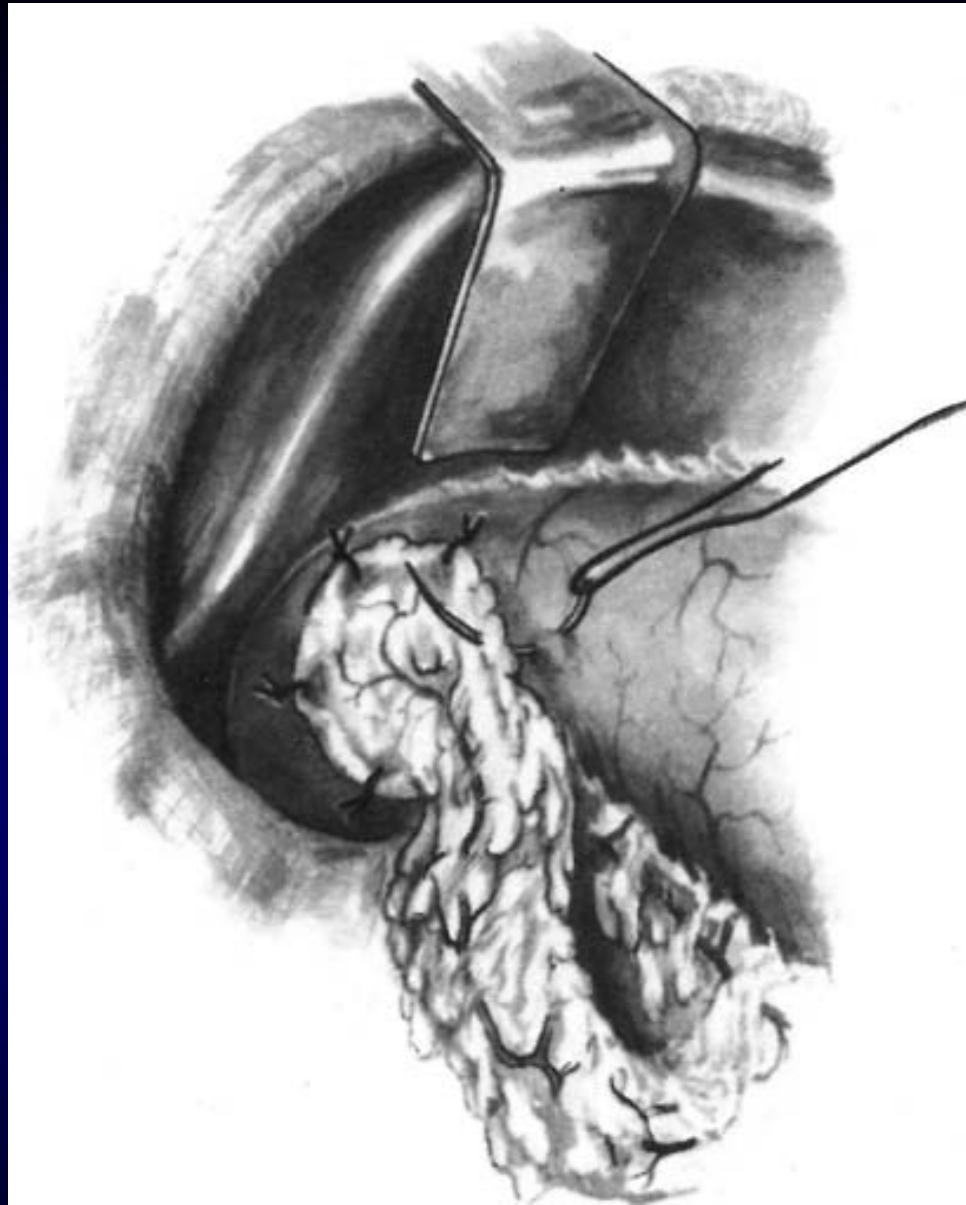
Another disadvantage is the difficulty in positioning the endoscope and applying metal ulcer closure clips in the inflamed duodenum.

As a diagnostic strategy, carefully selected patients may be candidates for endoscopy. As a therapeutic intervention, endoscopy is not supported by current evidence.


Simple suture type Miculicz



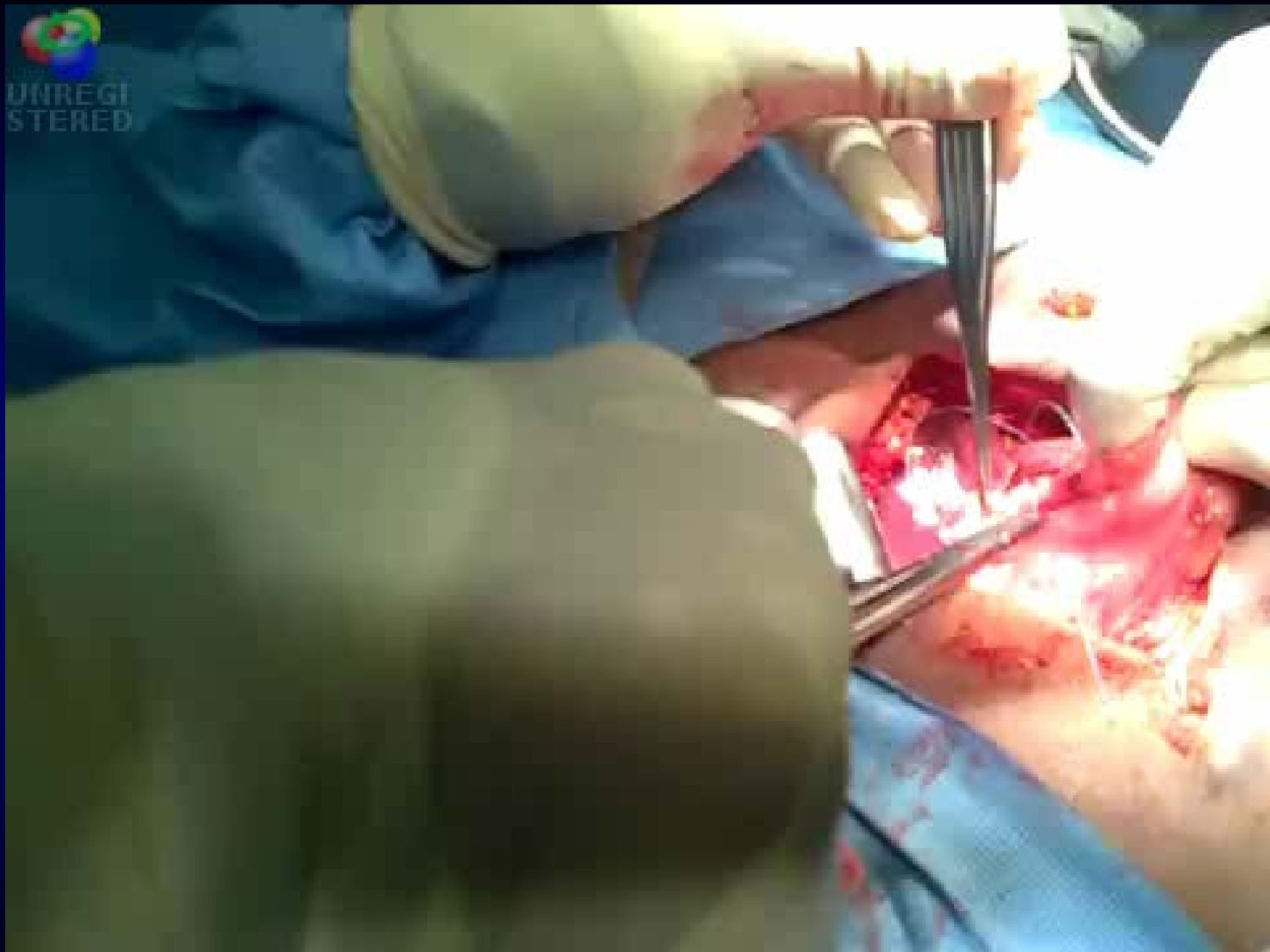On the edges of the ulcer perforation defect, separate sutures are placed through all the layers, a second suture line is mandatory in order to reinforce the first suture line.



In case of severe infiltration of the ulcer walls omental patch is useful with separate sutures without affecting the omental blood supply.

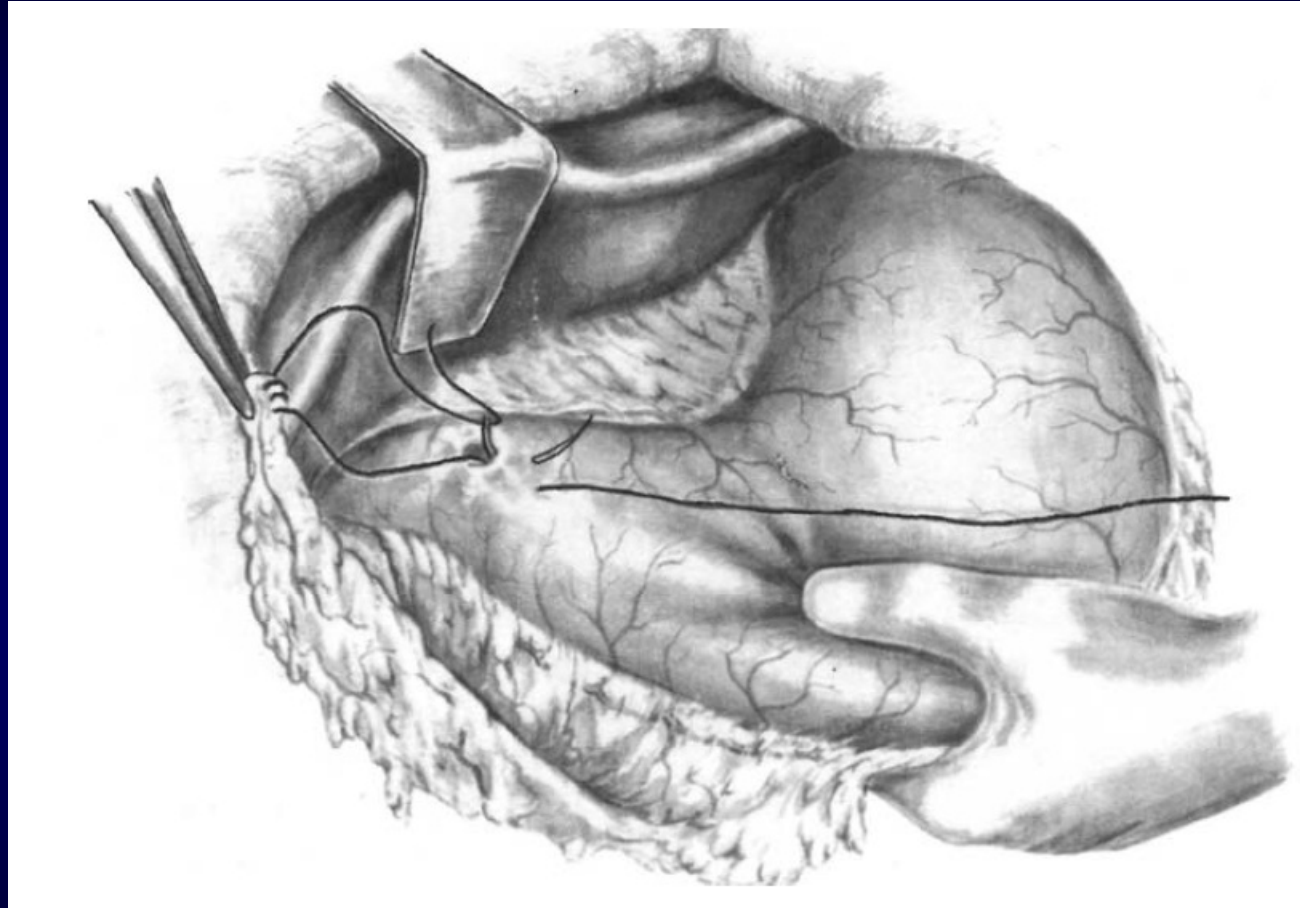


UNREGI
STERED



Simple suture of a perforated duodenal ulcer (Miculicz procedure)

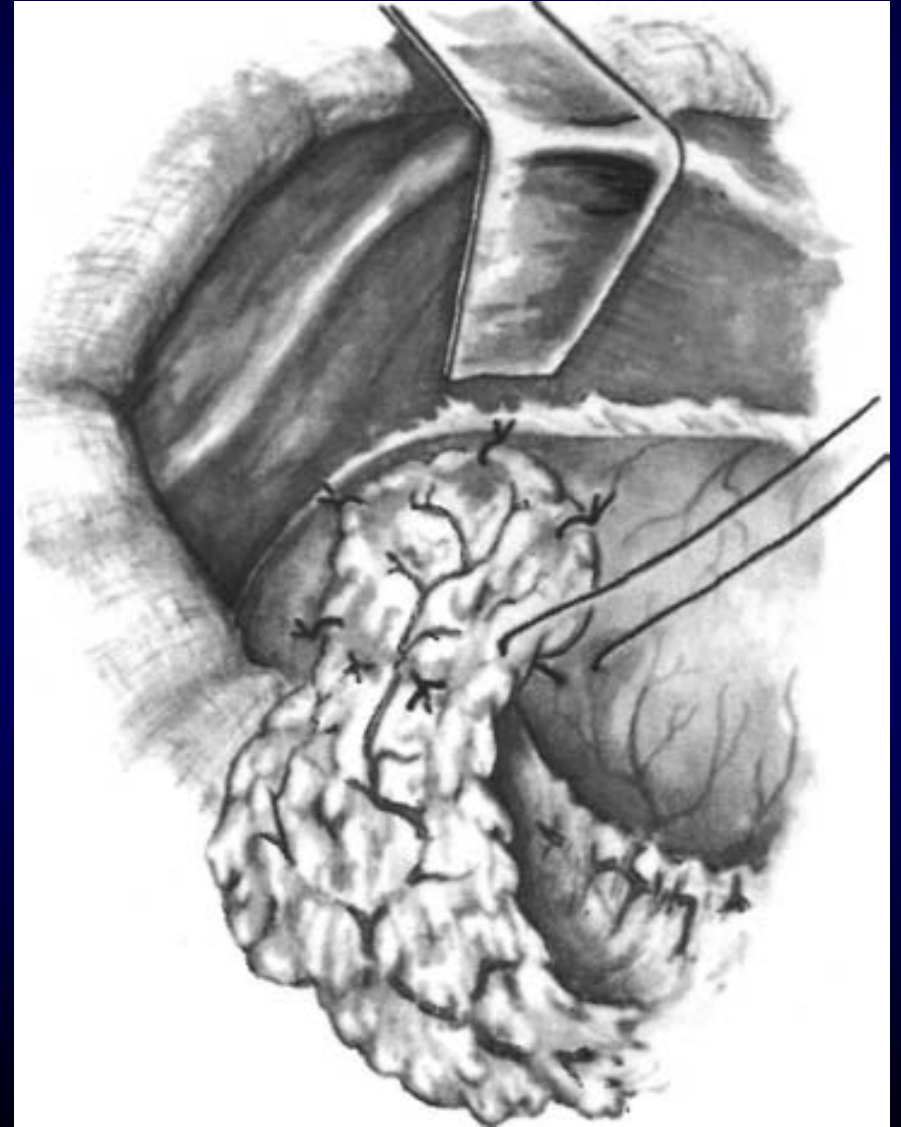
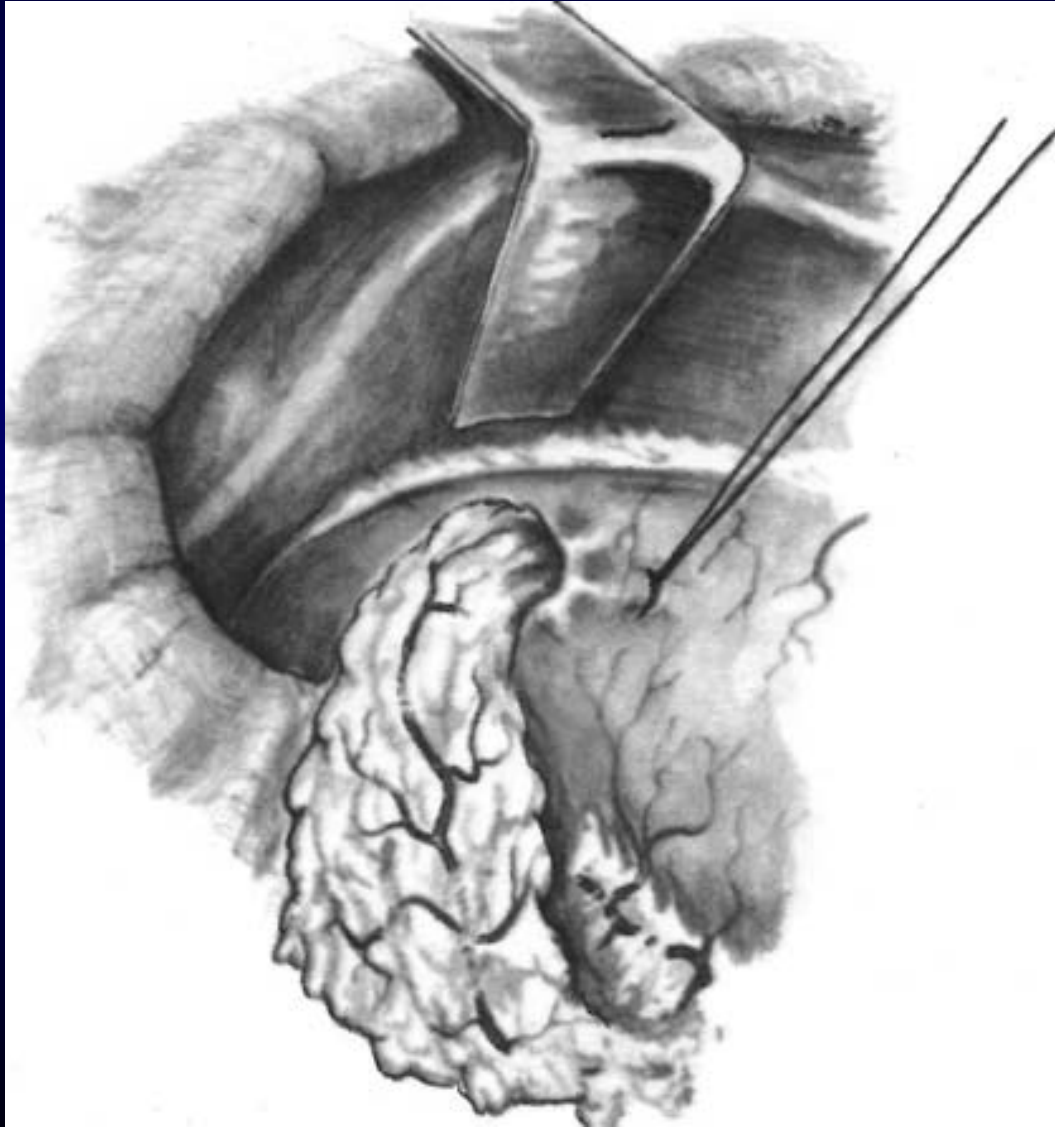
Oppel-Polikarpov procedure for perforated peptic ulcer

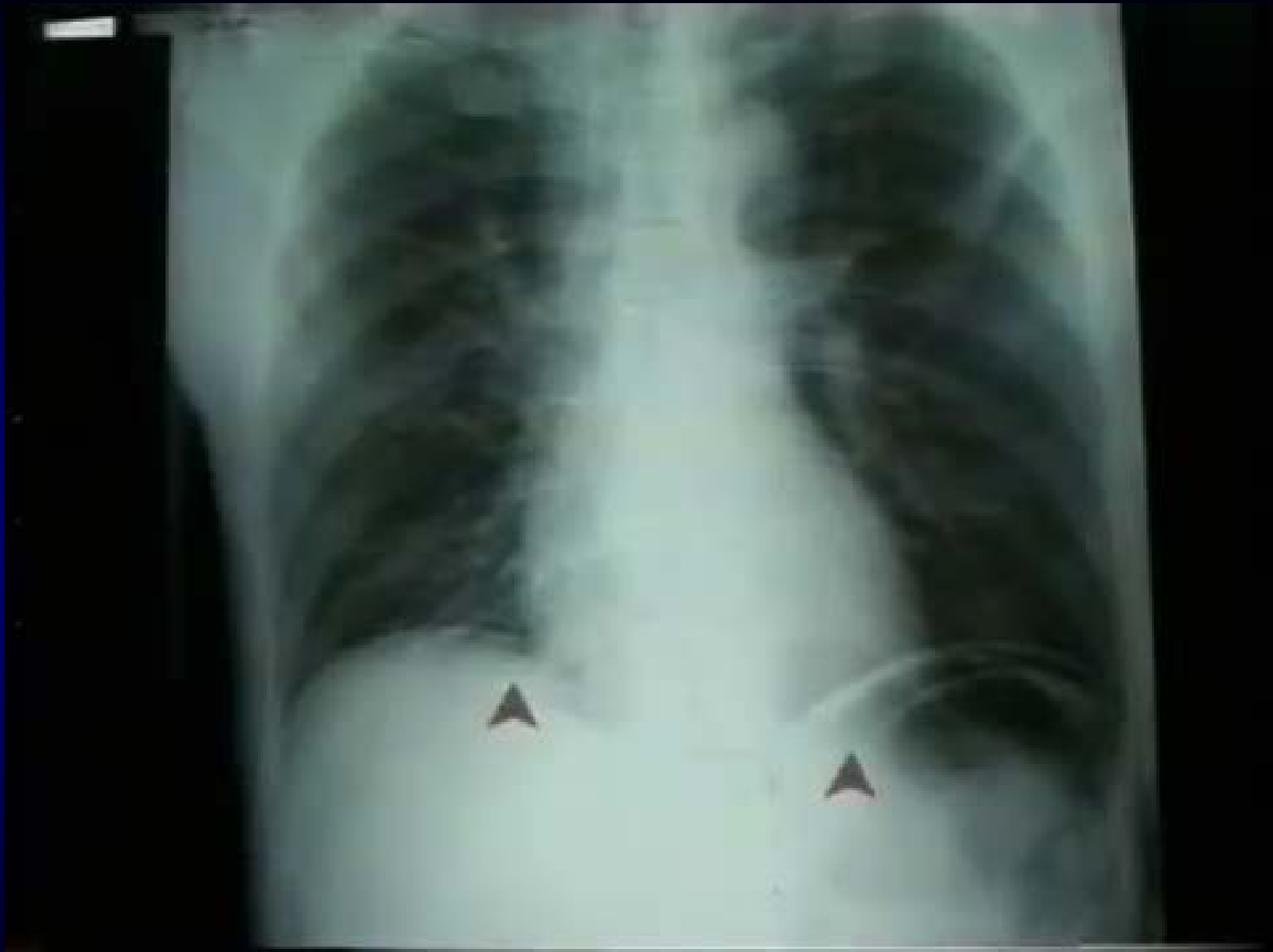


Indications:

- Over 6 h from perforation and diffuse or total peritonitis
- Chronic ulcer with high risk of suture leakage

Oppel-Polikarpov procedure for perforated peptic ulcer





Laparoscopic management of perforated PUD

Ulcer resection with pyloroplasty (Judd procedure)

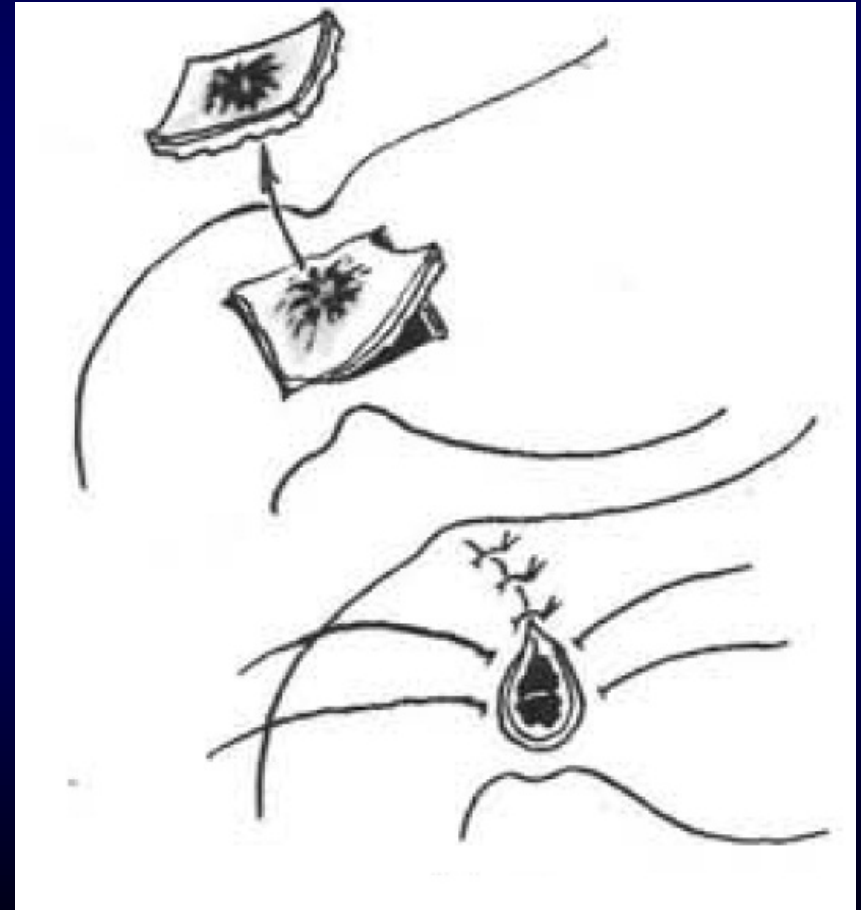
Indications:

- Ulcer perforation on the anterior duodenal wall
- Ulcer stenosis
- Organ preserving procedures
- Small size and medium size ulcers

Pyloroplasty

With
vagotomy

Without
vagotomy

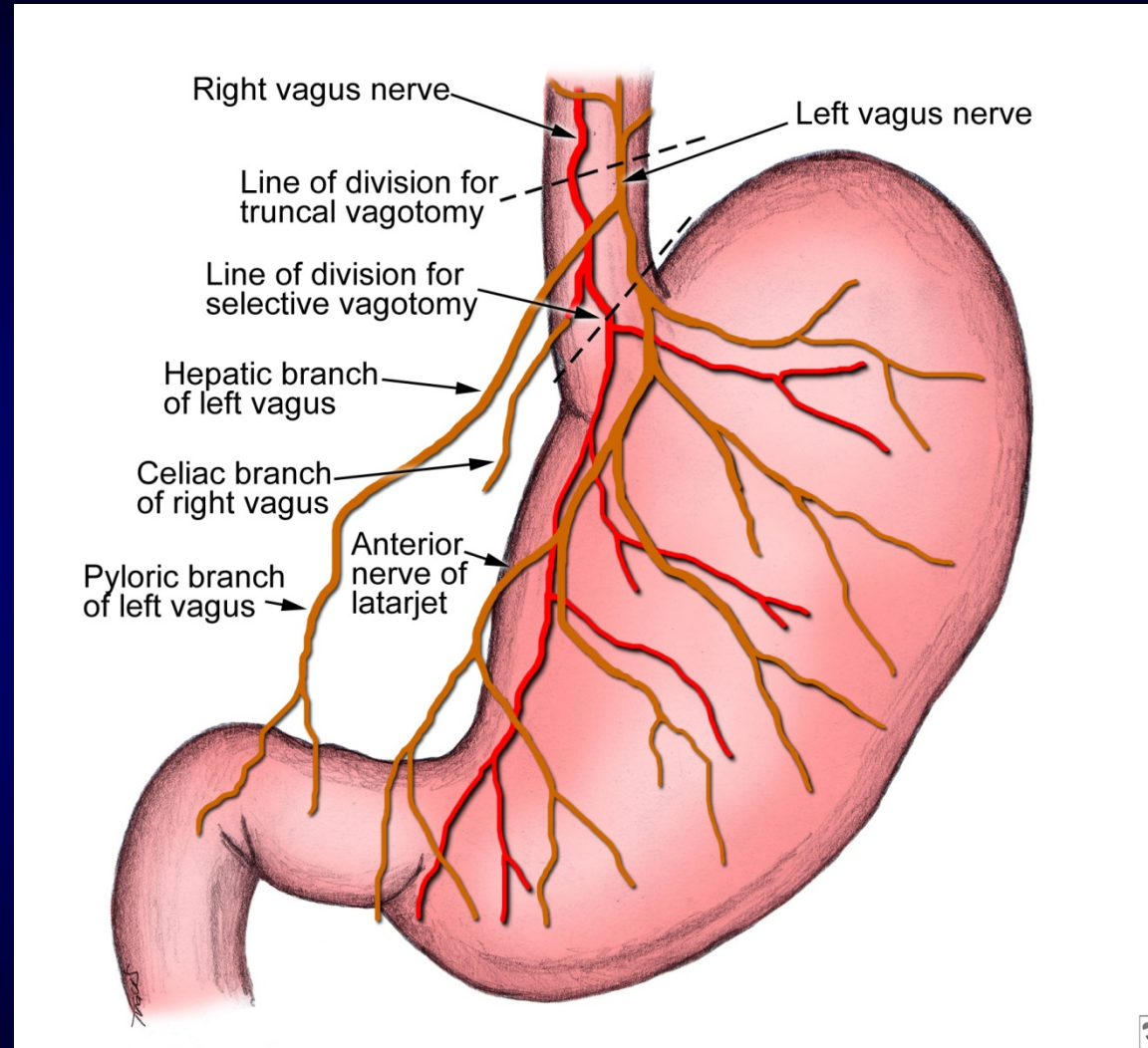


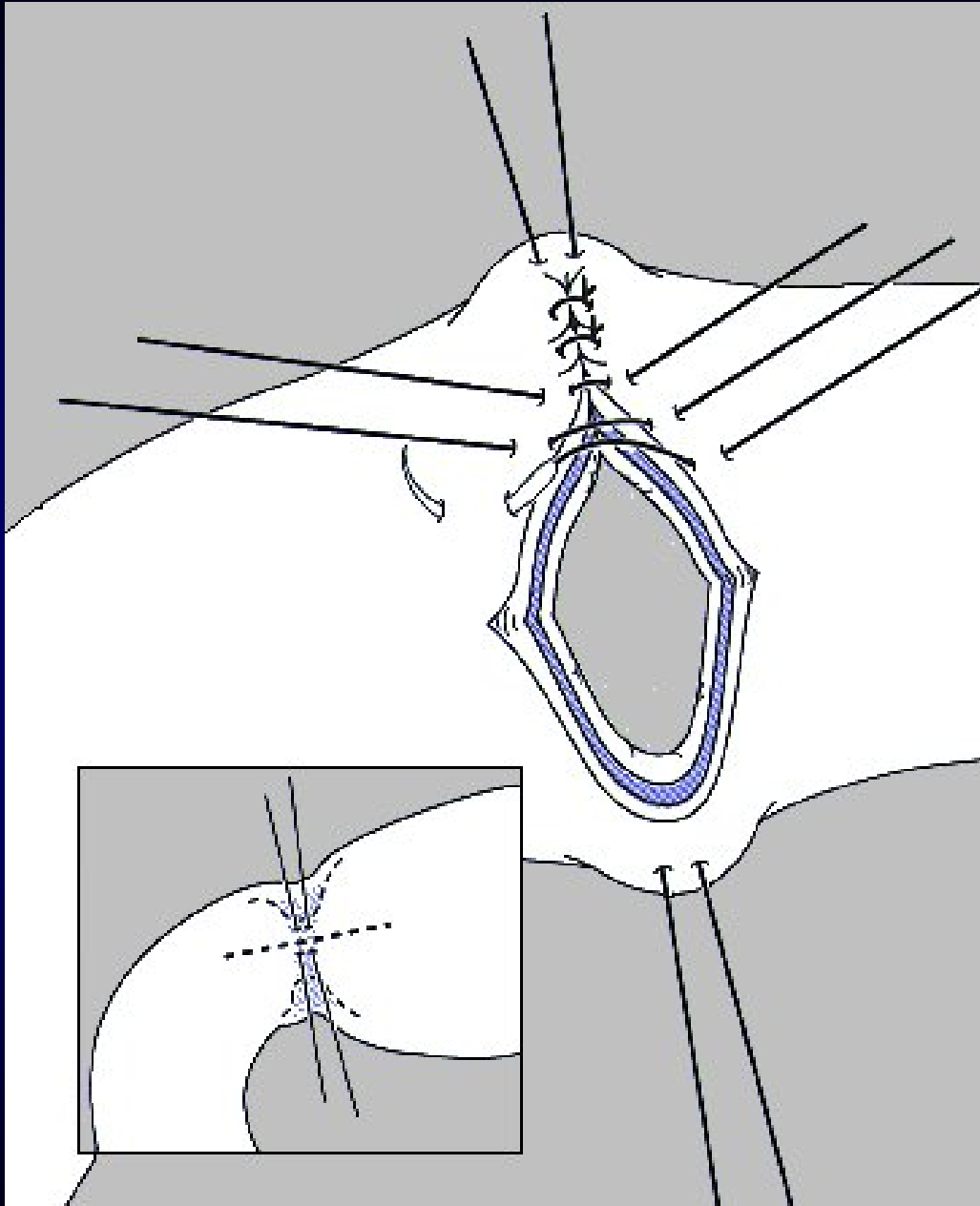
Truncal vagotomy is a treatment option for chronic duodenal ulcers. Truncal or total abdominal vagotomy divides the main vagal trunks as they emerge through the hiatus.

Truncal vagotomy produces total abdominal vagal denervation and requires a drainage procedure to prevent gastric stasis.

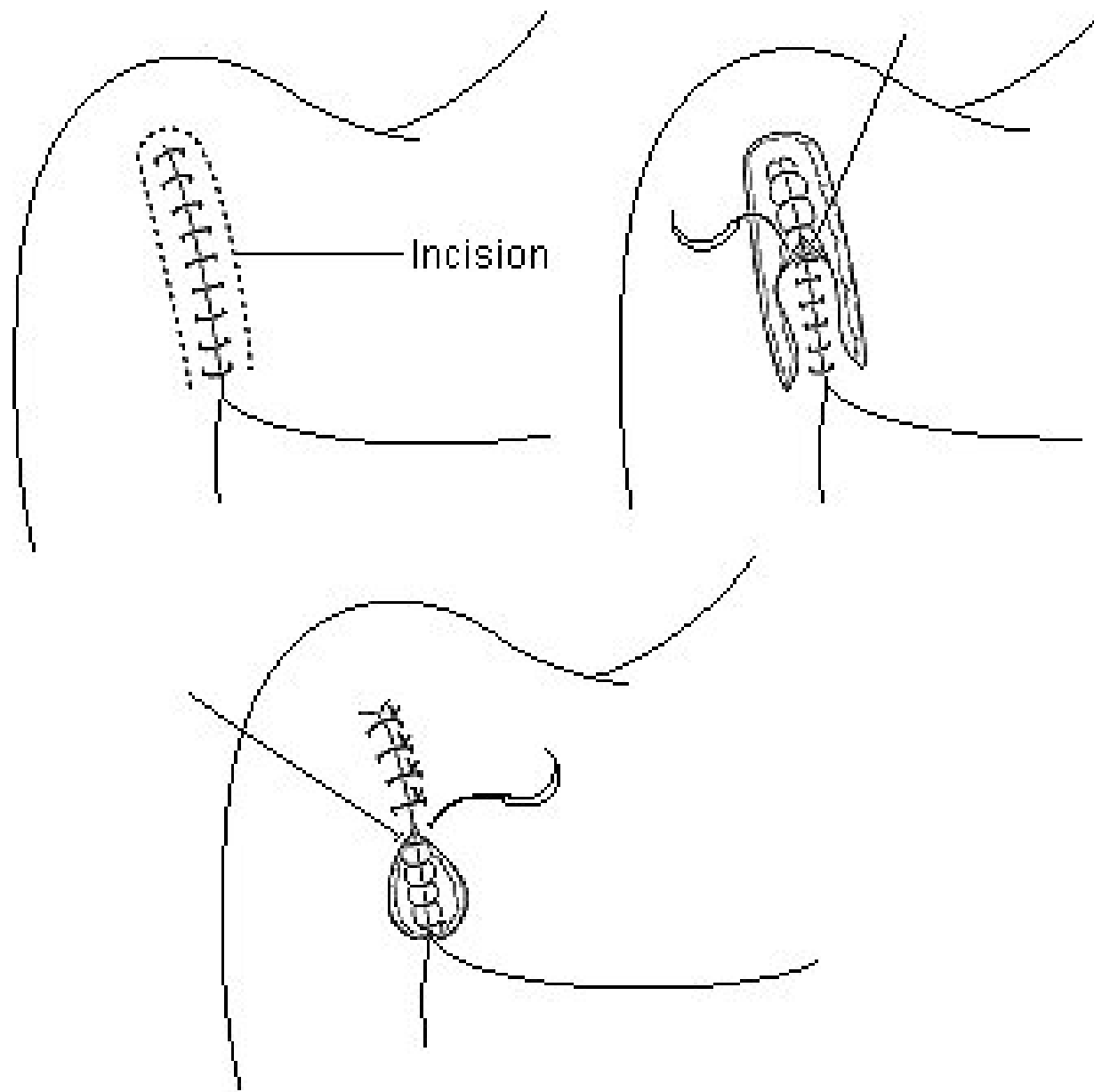
Kuremu RT. *East African Medical Journal*. 2002; 79 (9): 454–6.

Selective vagotomy spares the vagal branches to the liver and small intestine, but produces a total gastric vagotomy. A drainage procedure is required. **This vagotomy is rarely performed.**

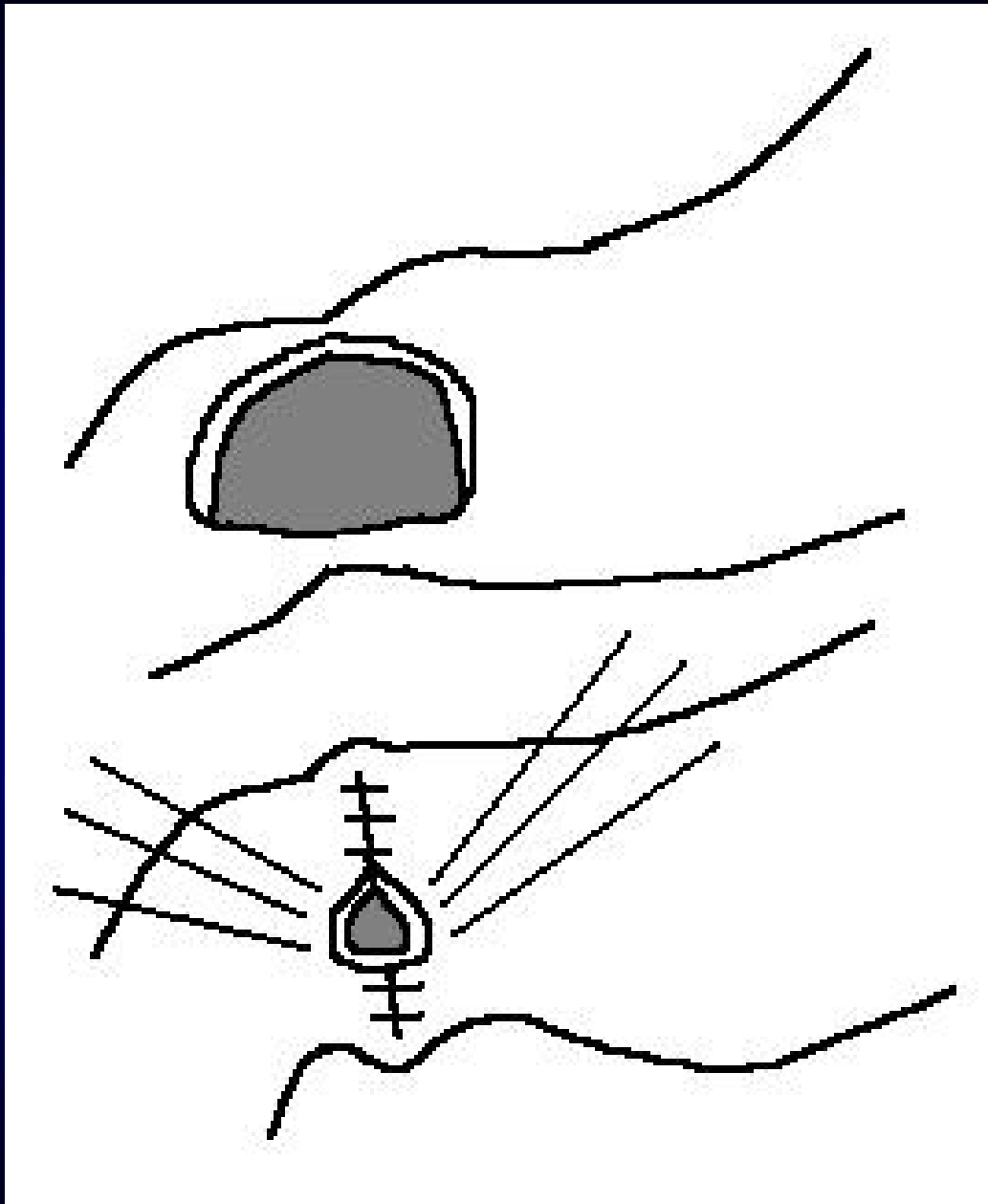




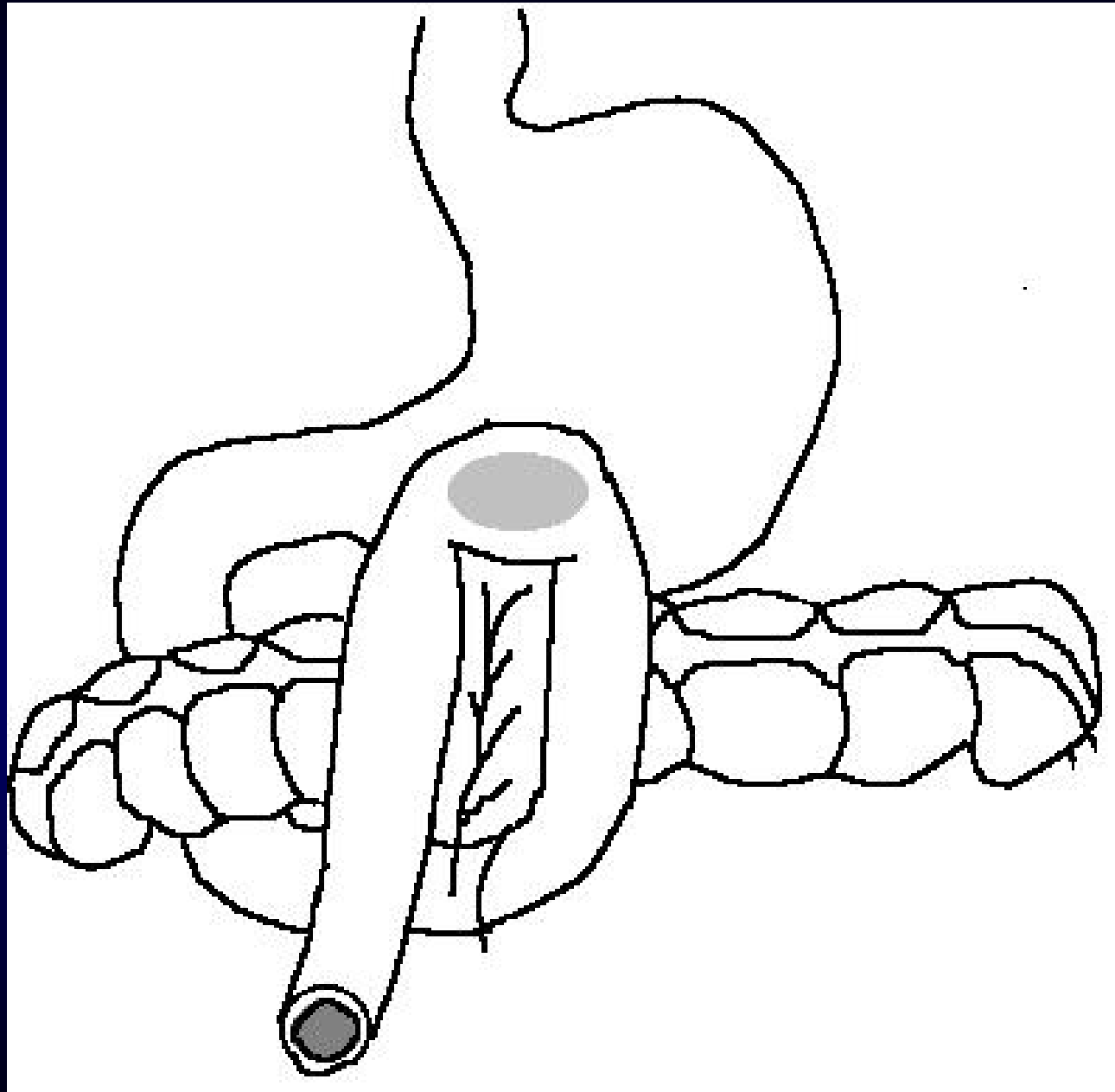
**PYLOROPLASY
HEINEKE-MIKULICZ,
1886-1887**



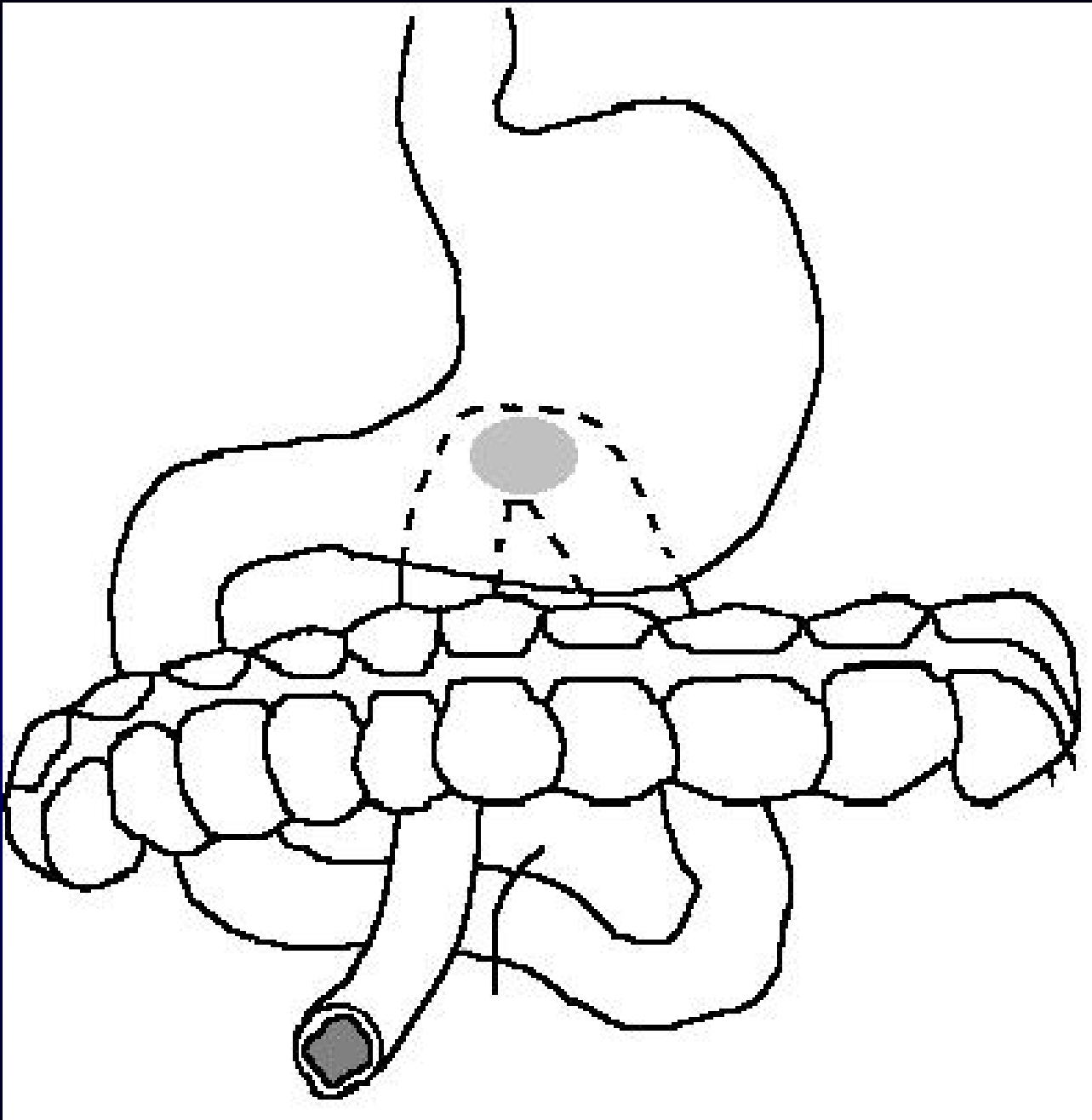
**PYLOROPLASTY
FINNEY, 1902**



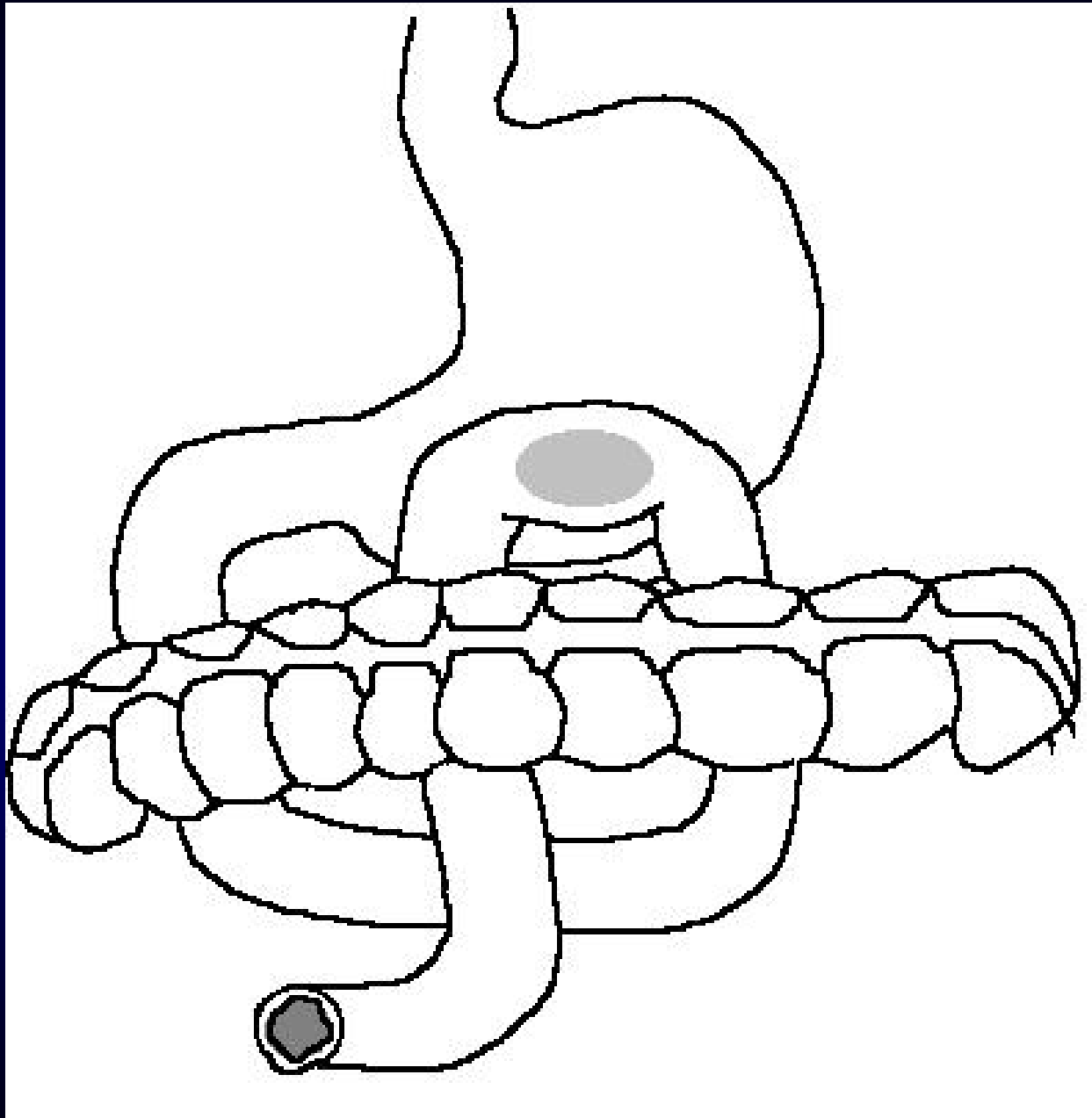
PYLOROPLASTY
BURLUI, 1969



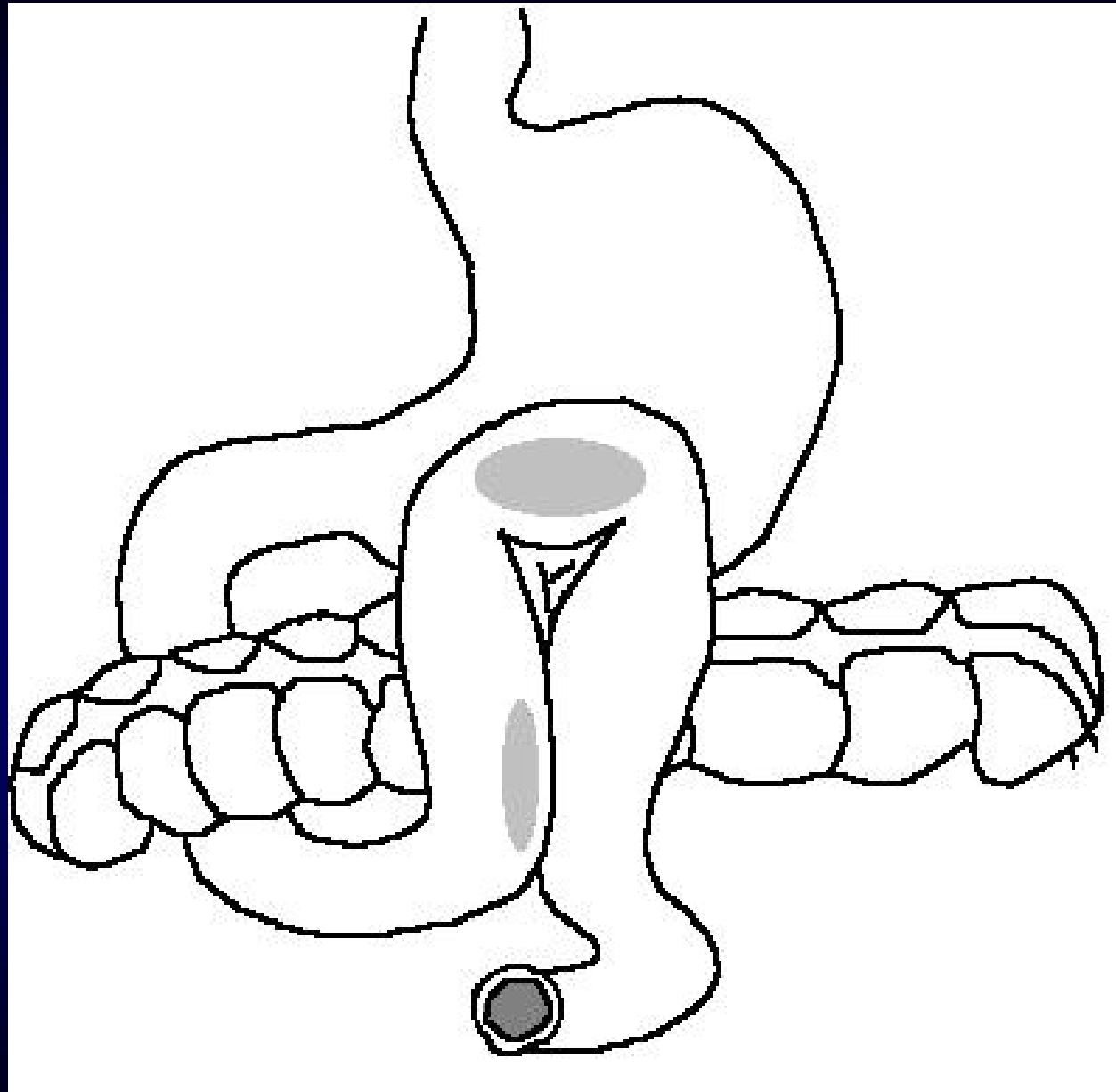
WOELFLER, 1881



HACKER, 1885



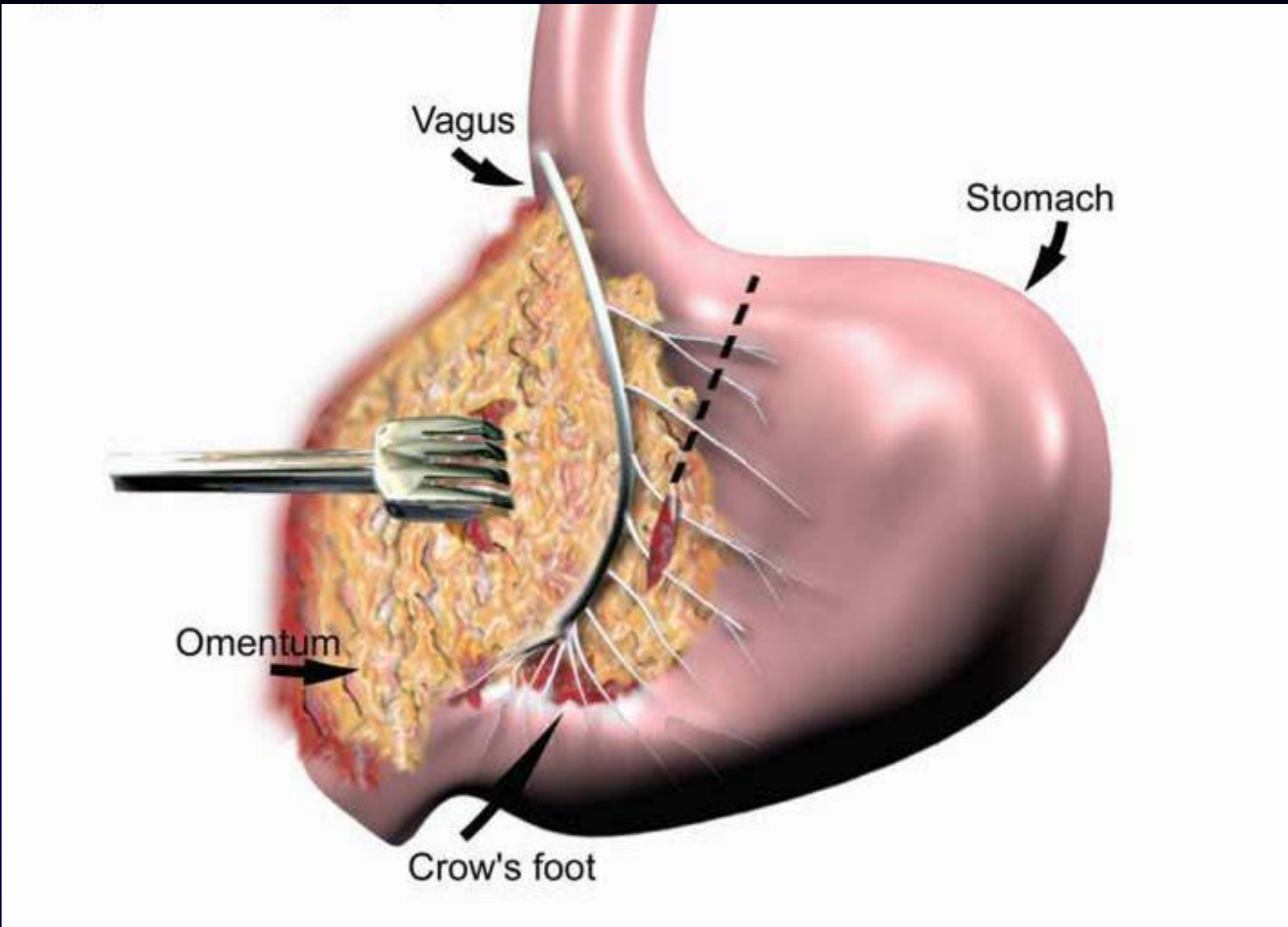
BRENNER, 1891



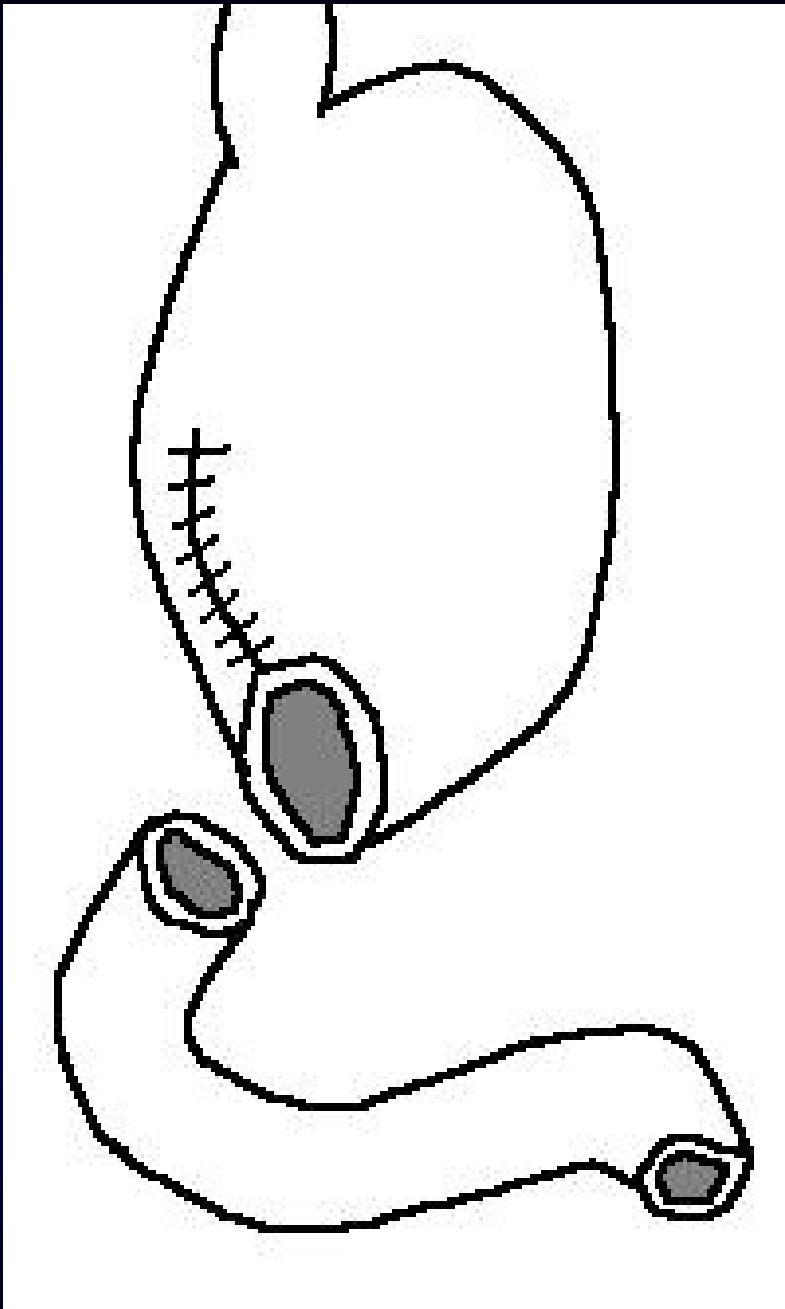
BRAUN, 1892



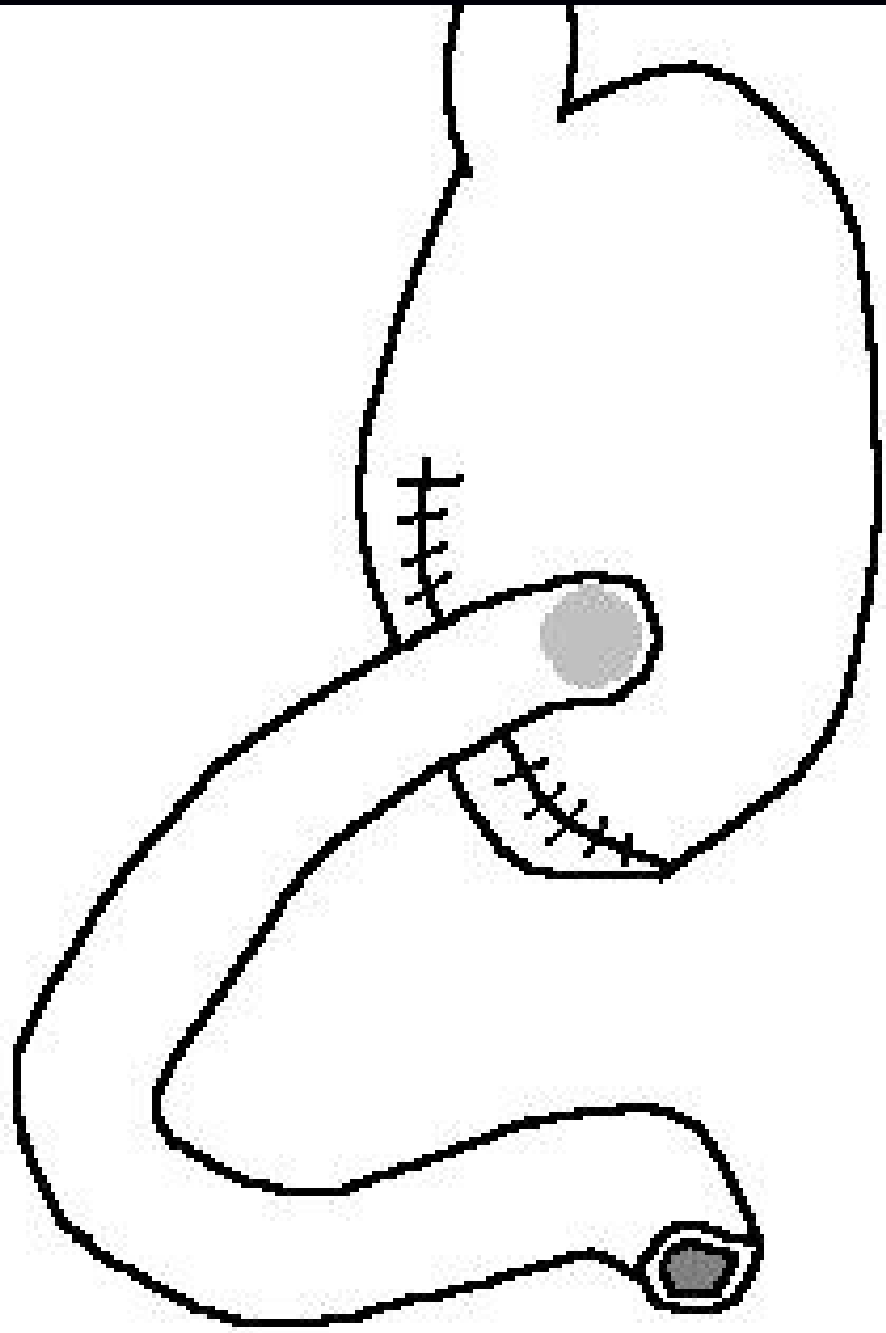
GDS JABOULAY




Highly selective vagotomy (HSV) produces selective denervation of the parietal cell mass. No drainage procedure is needed, as antral innervation is preserved.



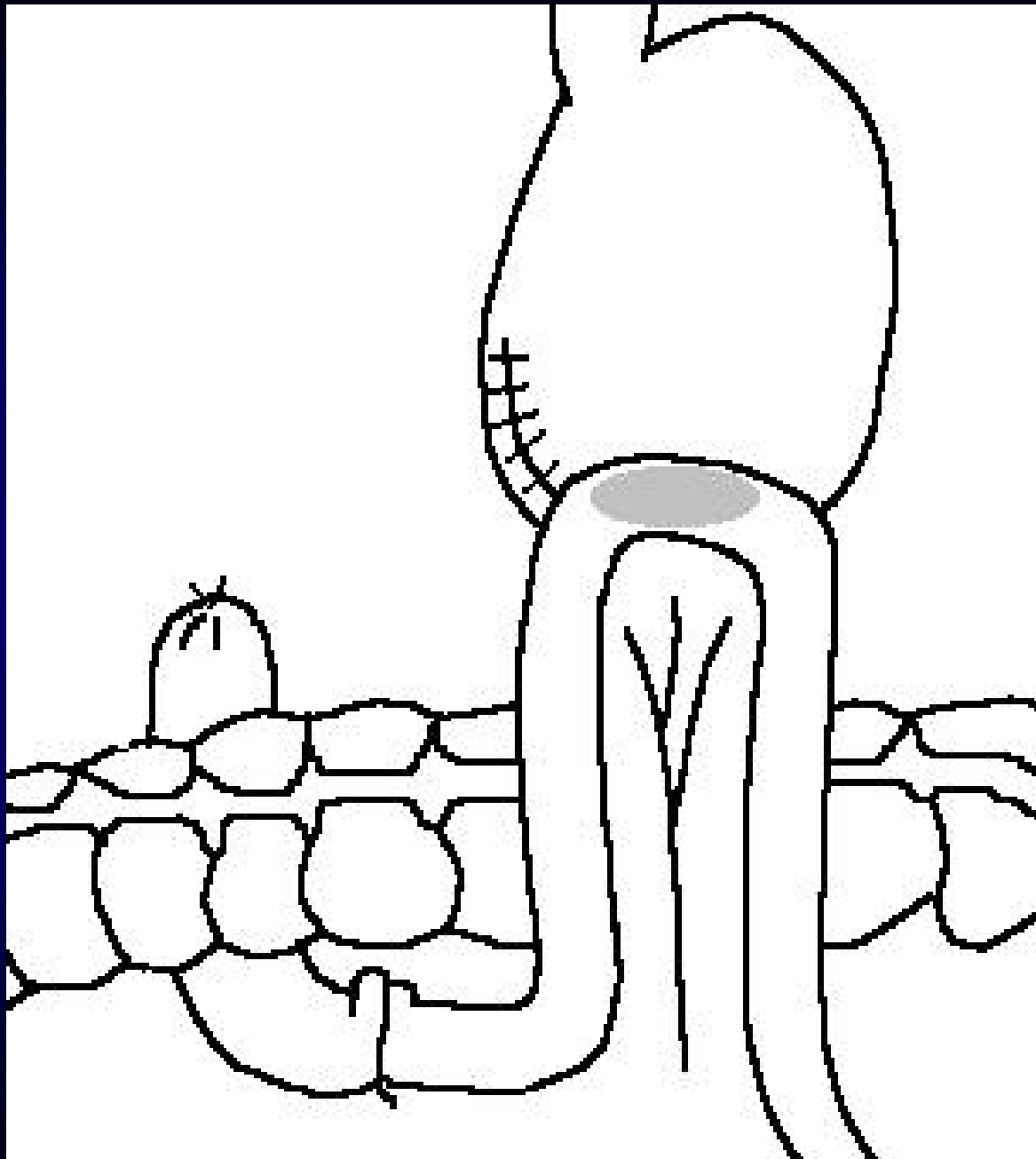
Billroth I gastrectomy (gastro-duodenum anastomosis)



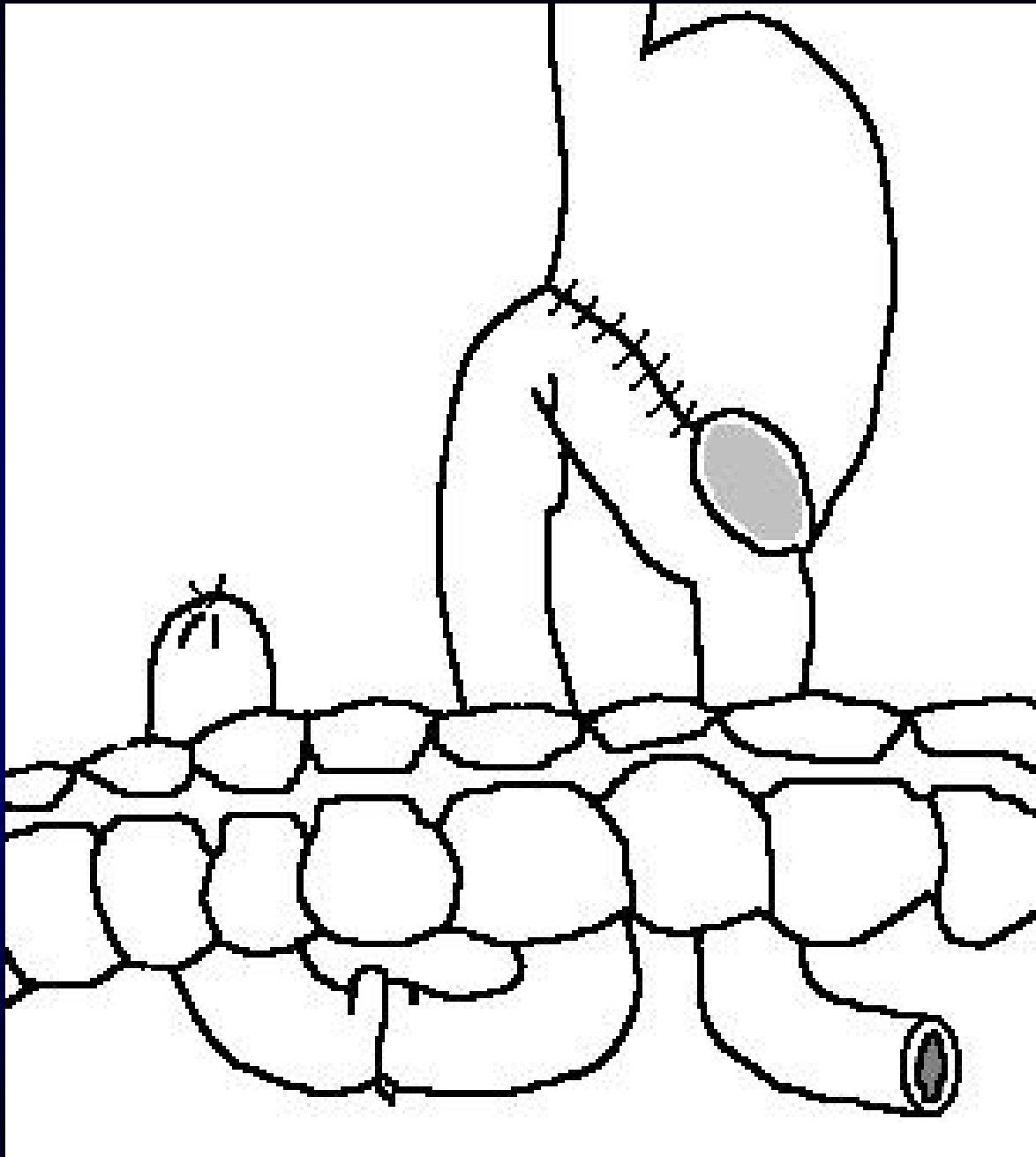
KOCHER



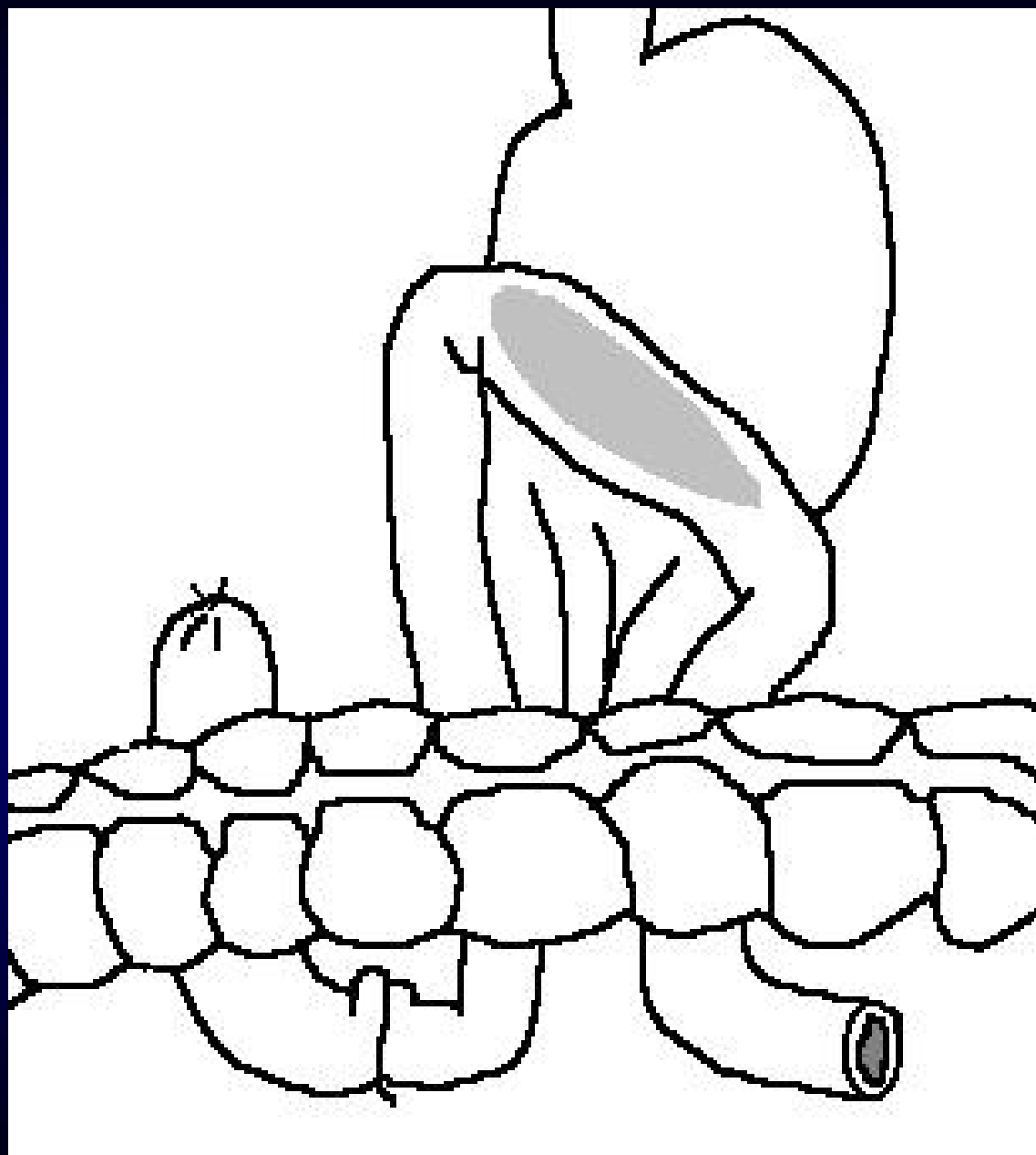
HABERER



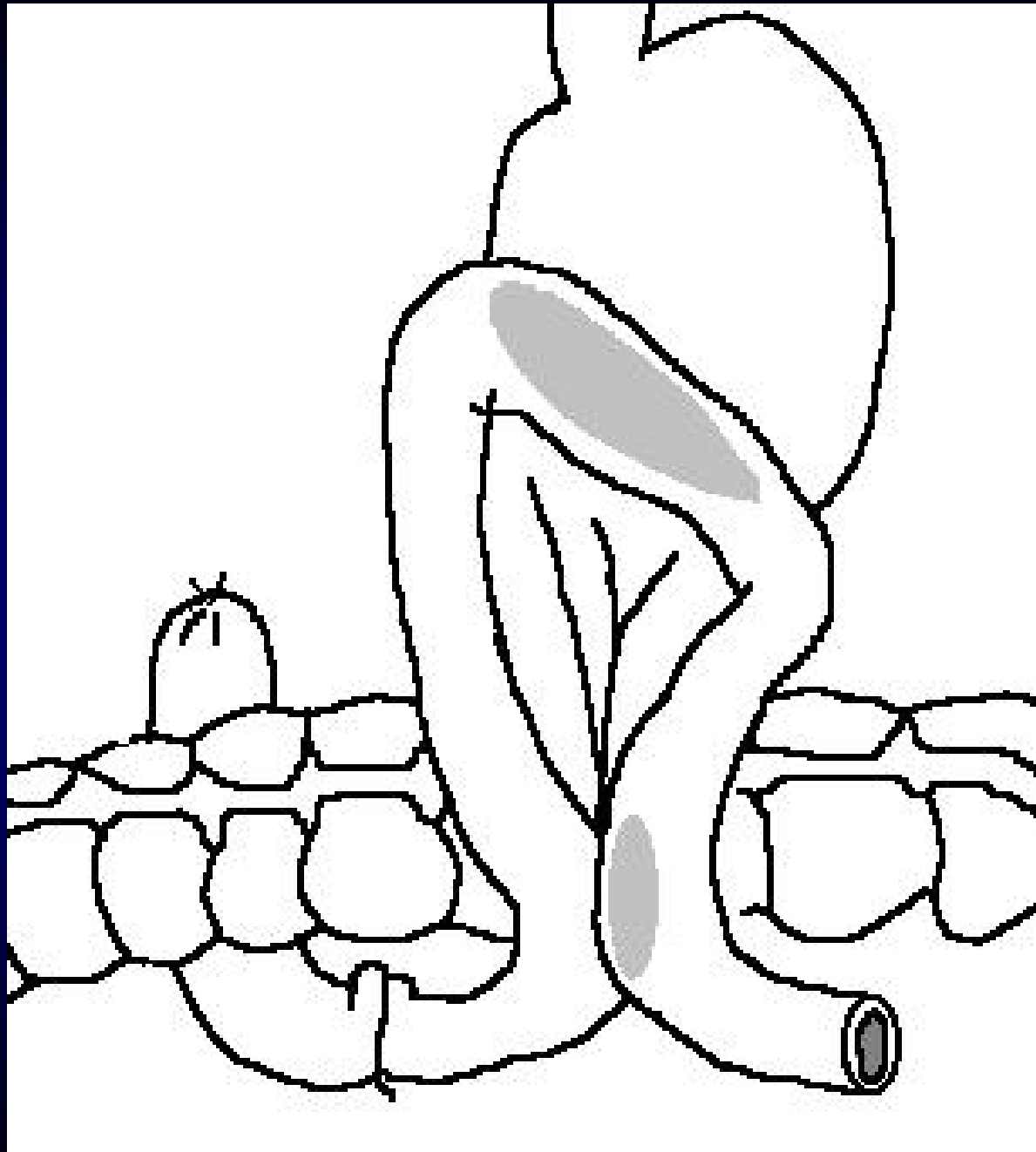
BILLROTH-II



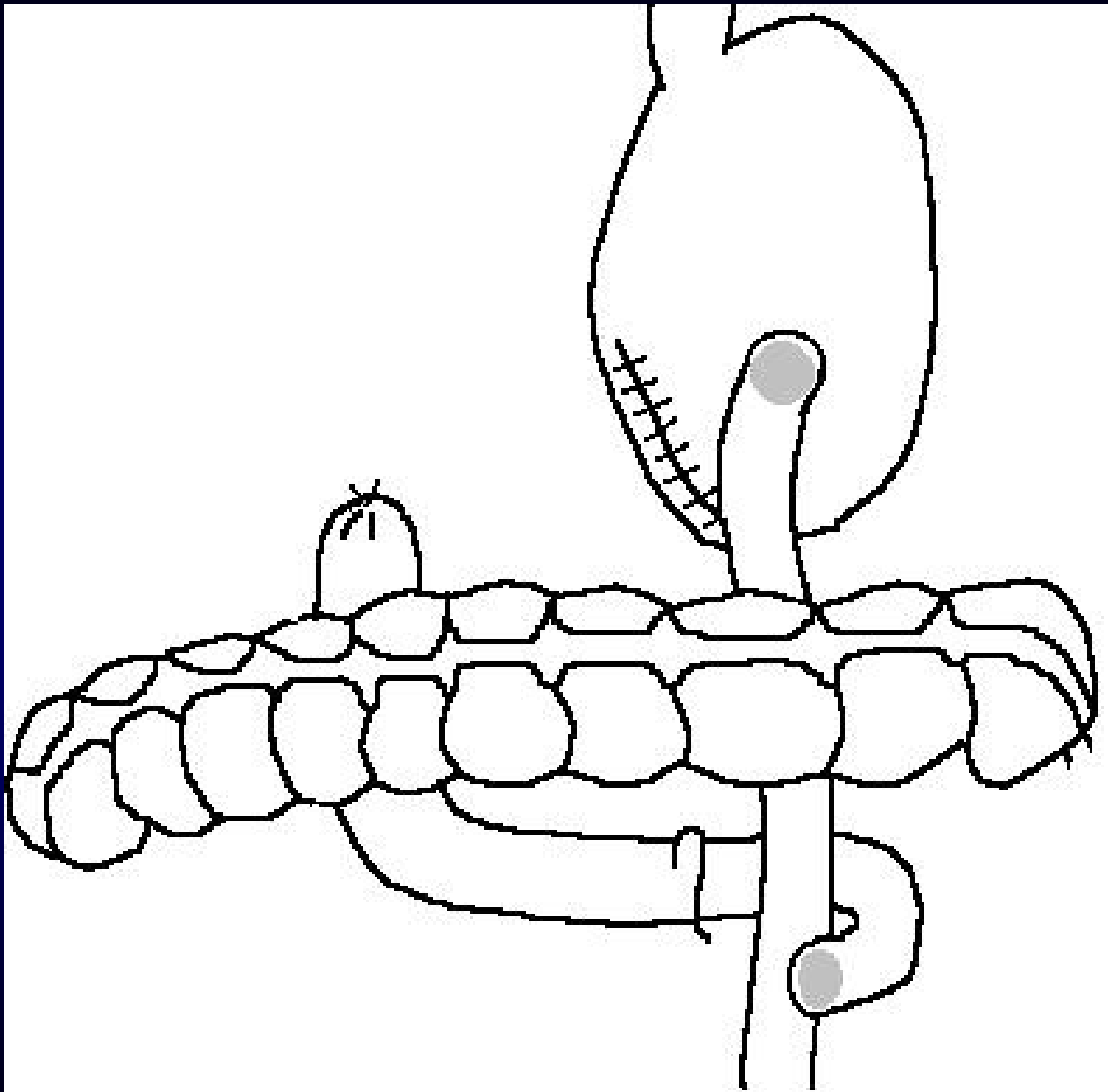
HOFMEISTER-FINSTERER



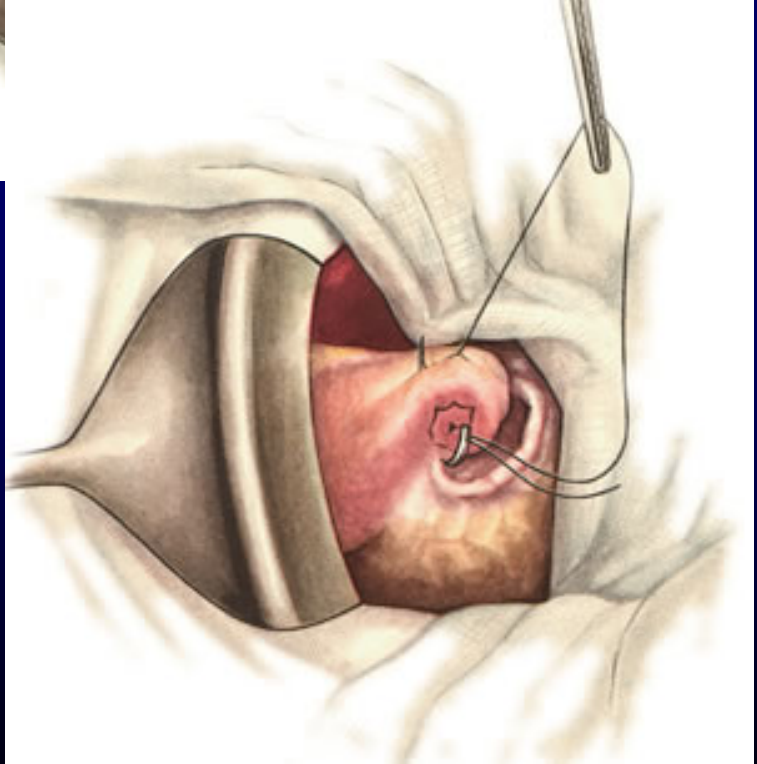
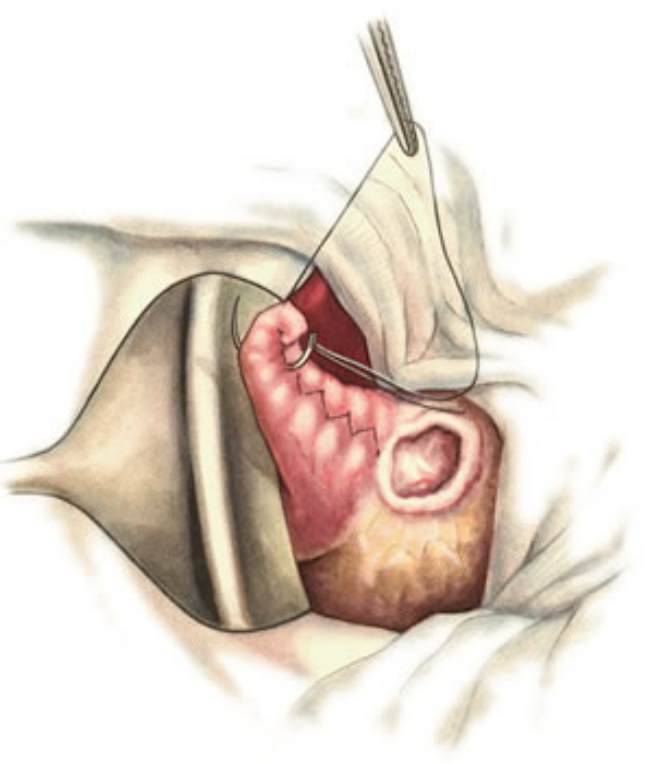
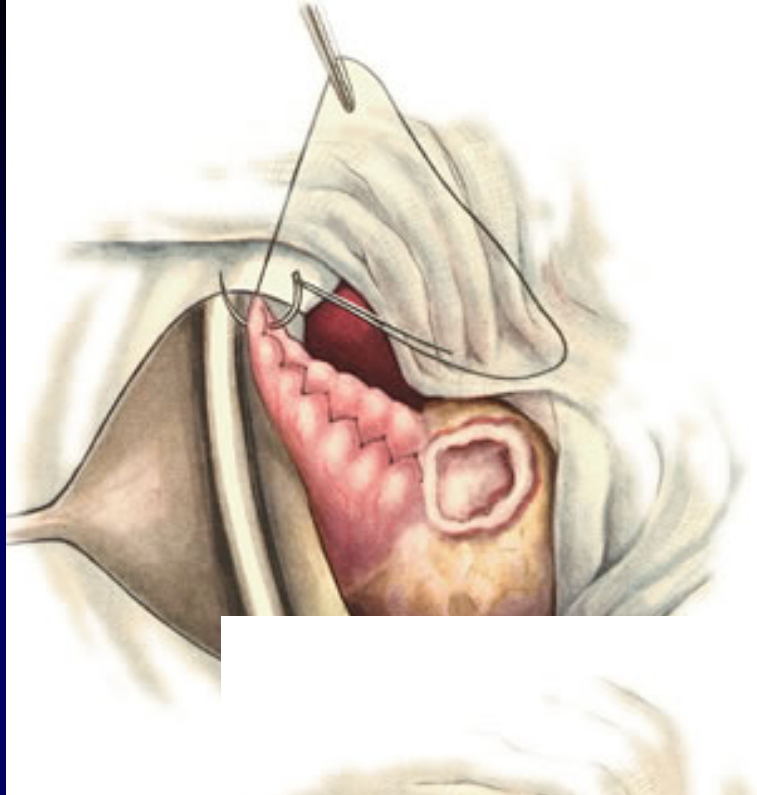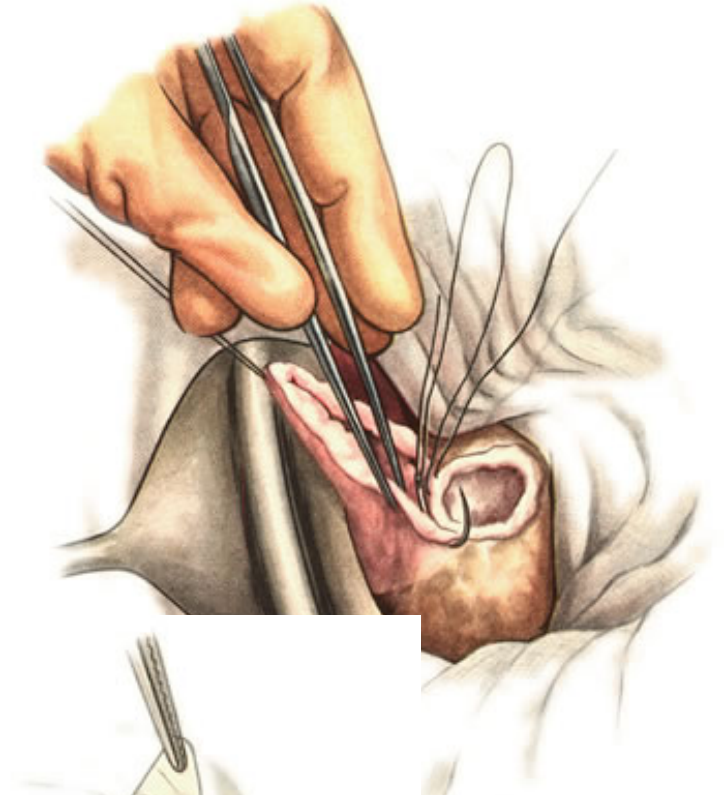
RECHEL-POLYA



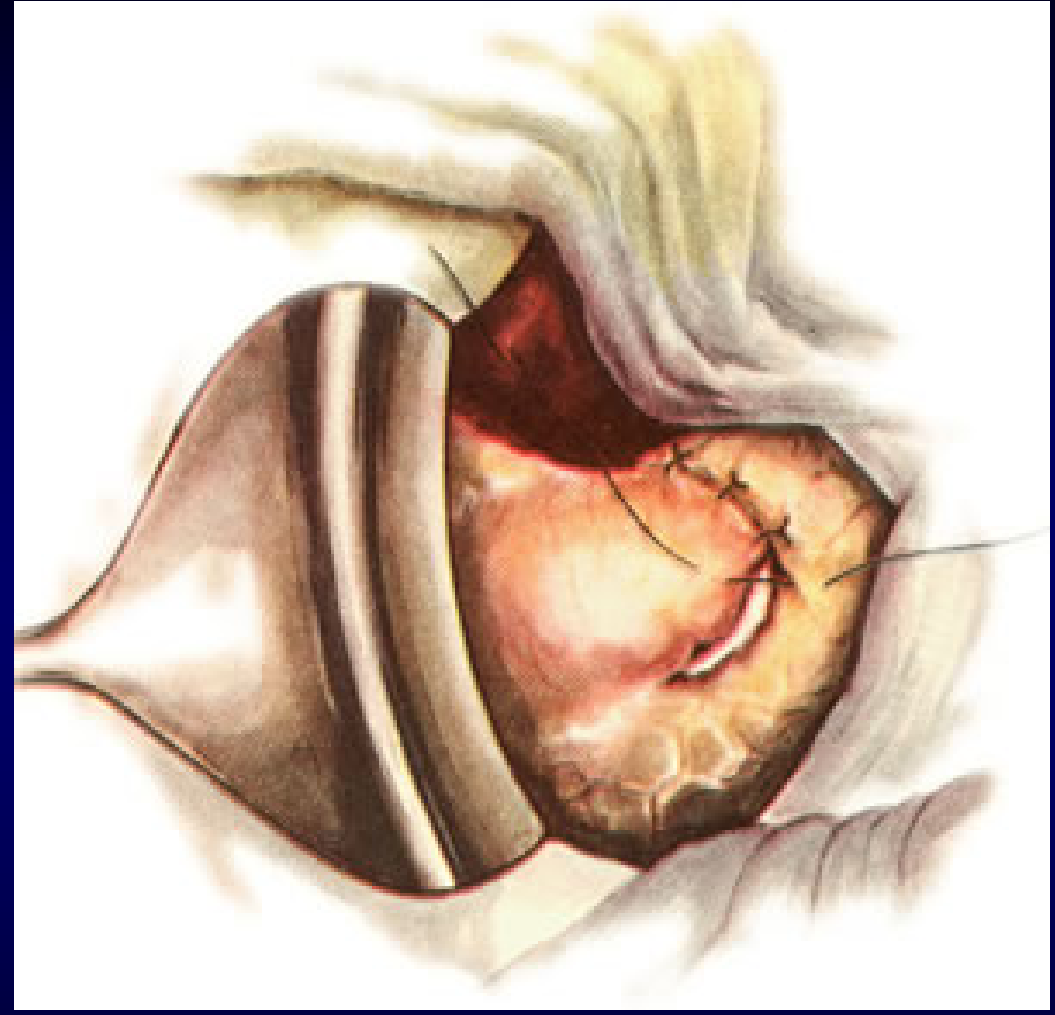
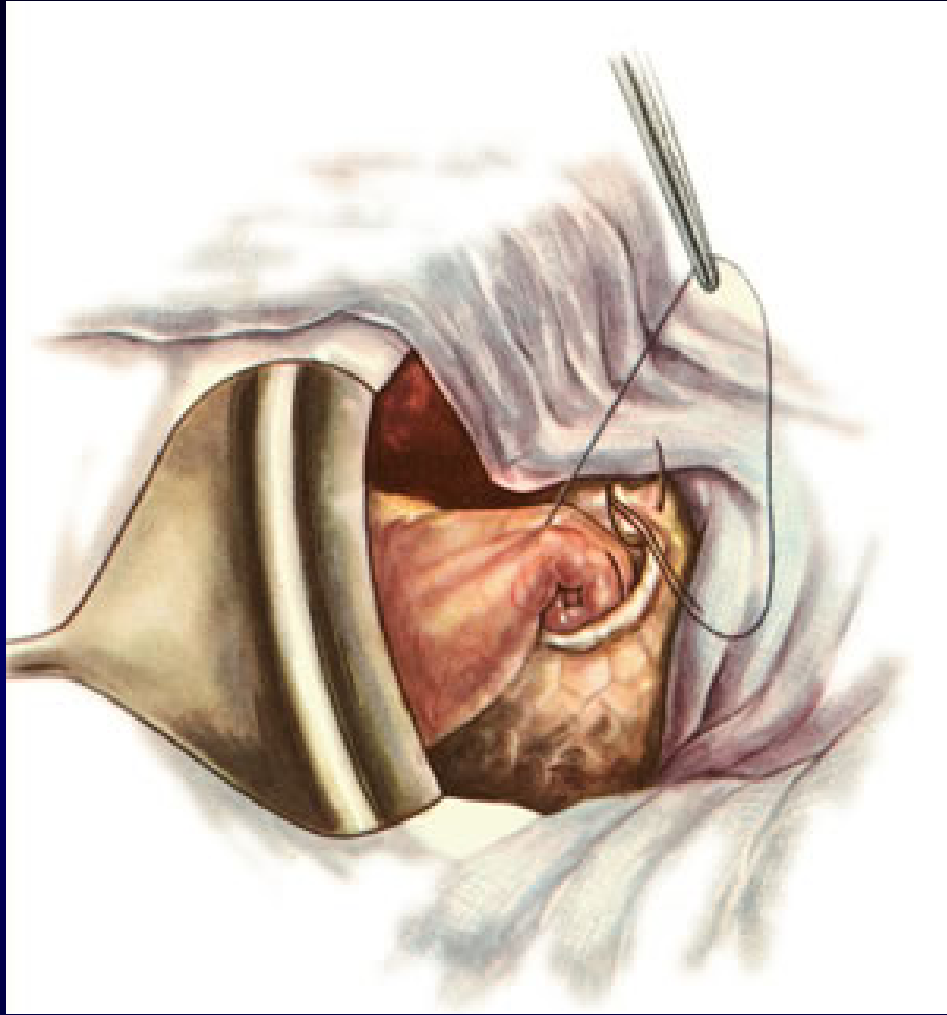
BALFOUR



ROUX



Method to closure a duodenal stump



Method to closure a duodenal stump (Final view).

Peptic ulcer bleeding

Upper gastrointestinal hemorrhage (UGIH) is an urgent disease often encountered in daily medical practice. Massive hemorrhage influences the circulatory dynamic state, causes various problems with internal organs, and can of course prove fatal.

Quickly grasping patient status, starting primary treatment, and stopping bleeding is thus important.

Endoscopic hemostasis is widely known to be useful in treating UGIH.

Jensen DM,. et al.: Gastroenterology 2002; 123: 407-413

Sung JJ,. et al.: Ann Intern Med 2003; 139: 237-243

Kahi CJ,. et al.: Gastroenterology 2005; 129: 855-862

Acute upper GI bleeding is defined as hemorrhage proximal to the ligament of Treitz.

Bleeding peptic ulcer incidence estimates of 19.4-170/100,000 population.

Lau JY., et al.: *Digestion* 2011; 84:102-13.
Spiegel BM., et al.: *Am J Gastroenterol* 2003; 98:86-97.

- **Hematemesis – (vomiting of blood)**
- **Melena – (tarry, foul-smelling feces due to oxidized iron from hemoglobin).**

The black color is caused by oxidation of the iron in hemoglobin during its passage through the ileum and colon.

Acute gastrointestinal bleeding emerges with symptoms of **haematemesis or melena**, or with both symptoms.

Around 20% patients with peptic ulcer bleeding are admitted in hospital with melaena.

30% have signs of haematemesis.

50% of patients have both symptoms.

Laine L, Peterson WL. N Engl J Med 1994;331:717-27.

Haematochesis (the passage of red blood through the rectum), as a symptom of bleeding from gastric or duodenal ulcer appears in 5% of patients.

Laine L, Peterson WL. N Engl J Med 1994;331:717-27.
Wara P, et al.: Scand J Gastroenterol 1985;20:72-8.

Classification of upper GI bleeding according to the volume of hemorrhage

GRADE	Defic. of CBV (%)	SBP (mm Hg)	Ps (b/min)	RBC ($\times 10^{12}/l$)	Ht (%)
I	< 20	> 100	90-100	> 3,5	> 35
II	20-30	90-70	100-120	3,5-2,5	35-25
III	> 30	< 70	120-140	< 2,5	<25

Forrest classification stratify patients with acute upper gastrointestinal bleeding into high- and low-risk categories for mortality.

Initial Forrest classification for bleeding peptic ulcer

Forrest Classification	Rebleeding Incidence	Surgical Requirement	Incidence of Death
<i>Type I: Active Bleed</i> Ia: Spurting Bleed Ib: Oozing Bleed	55-100%	35%	11%
<i>Type II: Recent Bleed</i> IIa: Non-Bleeding Visible Vessel (NBVV) IIb: Adherent Clot	40-50%	34%	11%
<i>Type III: Lesion without Bleeding</i> Flat Spot Clean Base	10% 5%	6% 0.5%	3% 2%

Upper GI endoscopy is the first line diagnostic procedure for upper GI bleeding, since it allows not only to **establish a diagnosis** (bleeding source, bleeding activity), but also allows **hemostasis**.

Active hemorrhage

Risk of rebleeding if untreated (%)

- Forrest I a (Spurting hemorrhage) 90
- Forrest I b (Oozing hemorrhage) 30

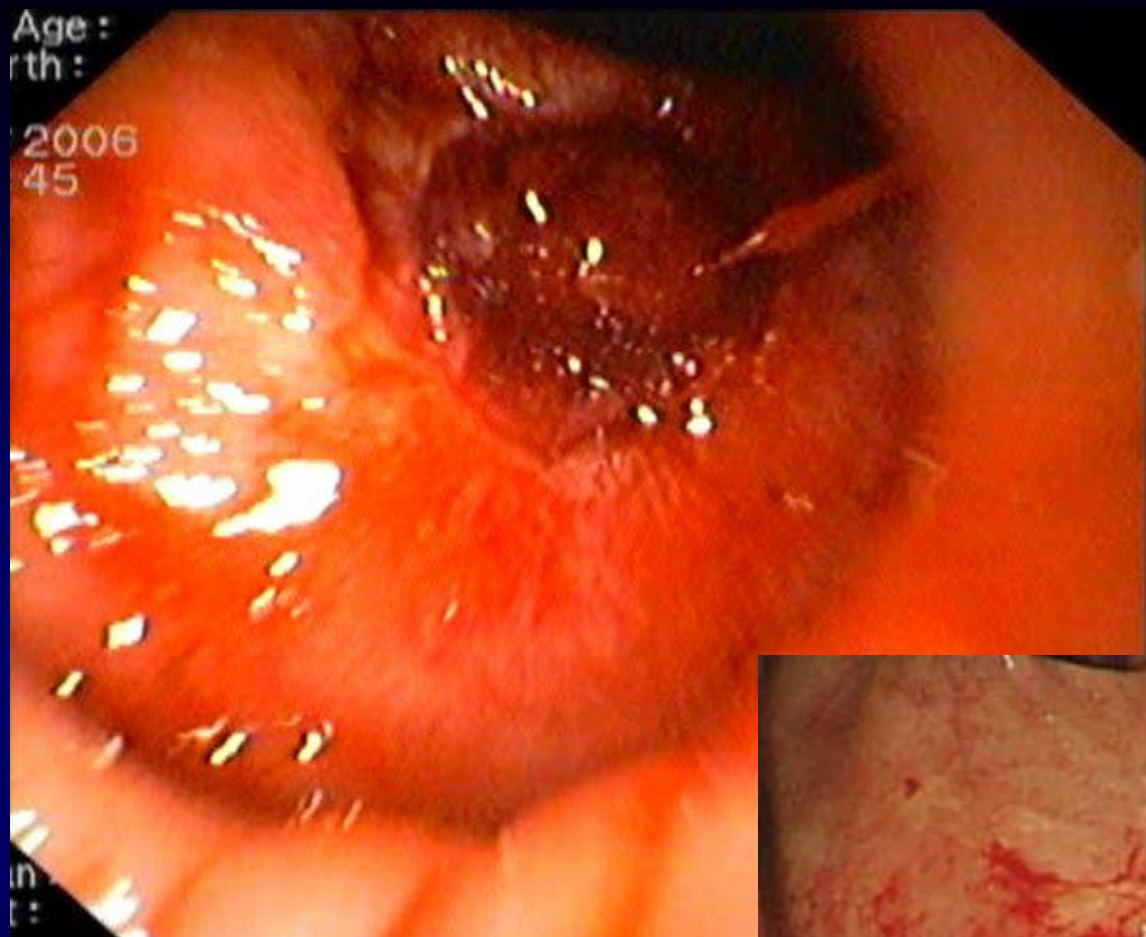Signs of recent hemorrhage

- Forrest II a (Visible vessel) 50-100
- Forrest II b (Adherent clot) 20
- Forrest II c (Hematin on ulcer base) <5

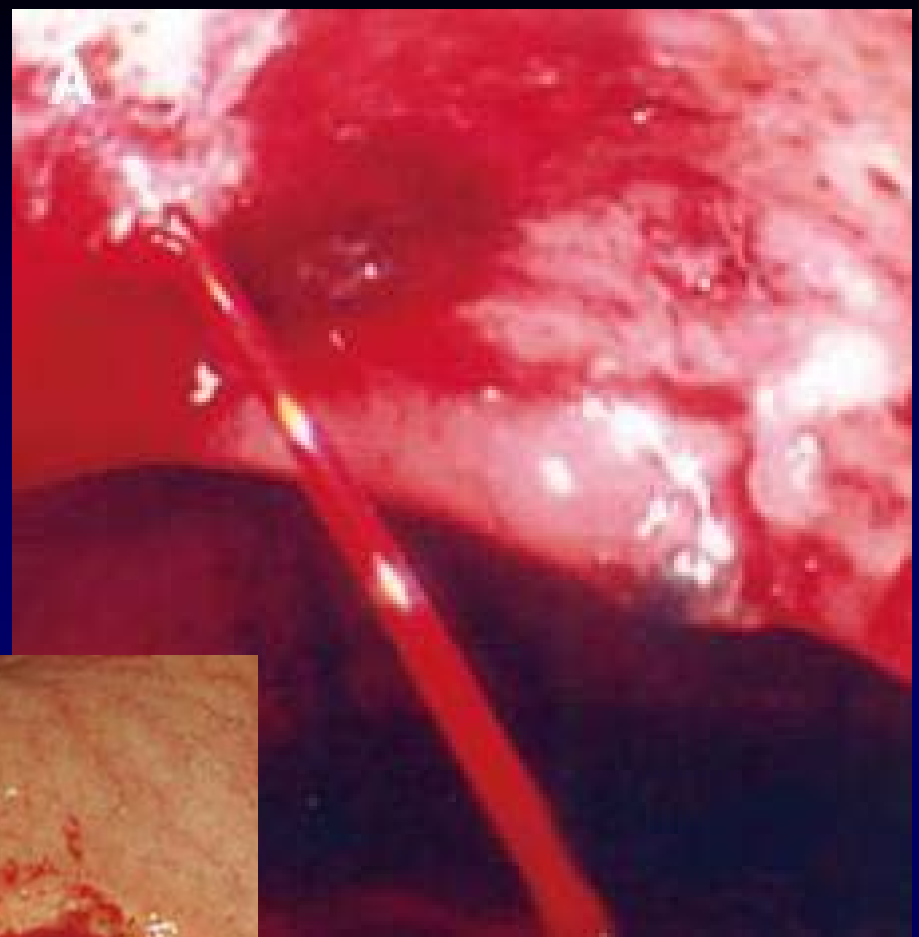
Lesions without active bleeding

- Forrest III (Lesions without signs of recent hemorrhage) <5

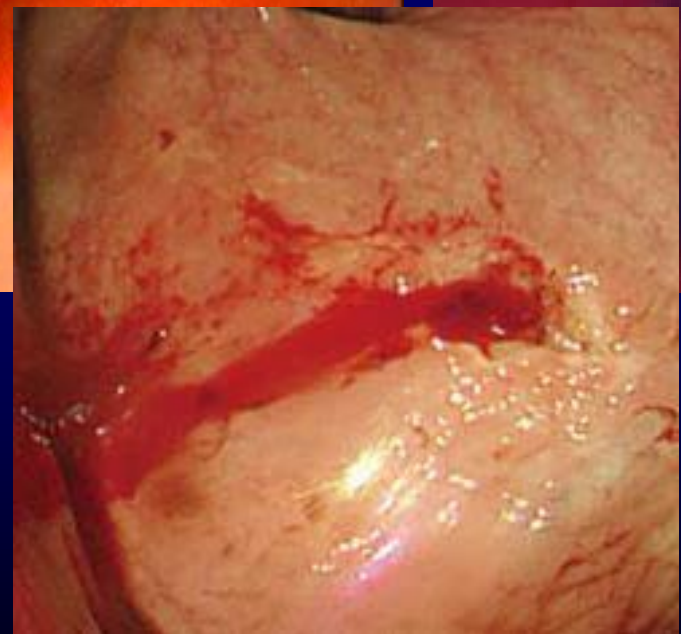Block B., Schachschal G., Schmidt H. Endoscopy of the upper GI tract: a training manual. 2004.
Kohler B, Riemann JF. Hepatogastroenterology 1991; 38: 198-200.
Heldwein W,. et al.: Endoscopy 1989; 21: 258-262.
Anjiki H,. et al.: World J Gastrointest Endosc 2010 ;2:54-60.



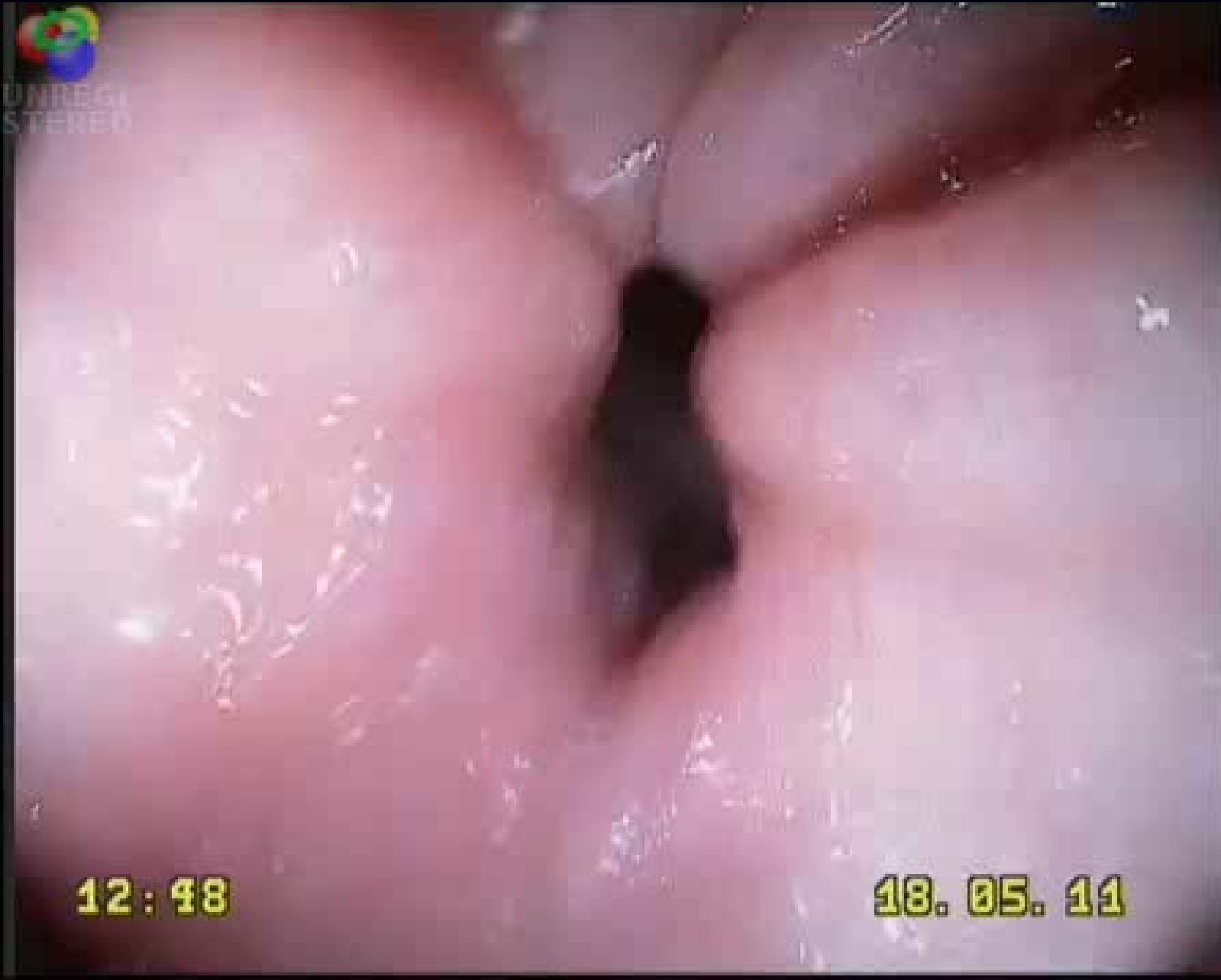Forrest Ia – duodenal bleeding ulcer



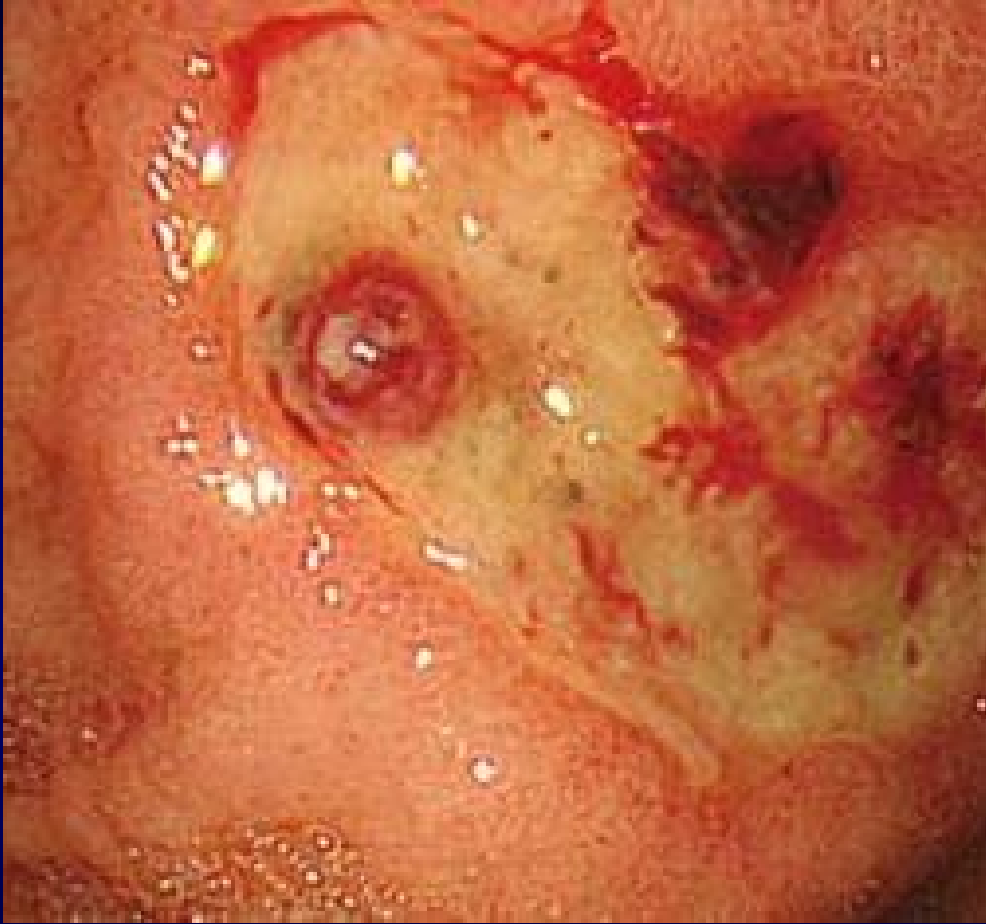
Forrest Ia – gastric bleeding ulcer



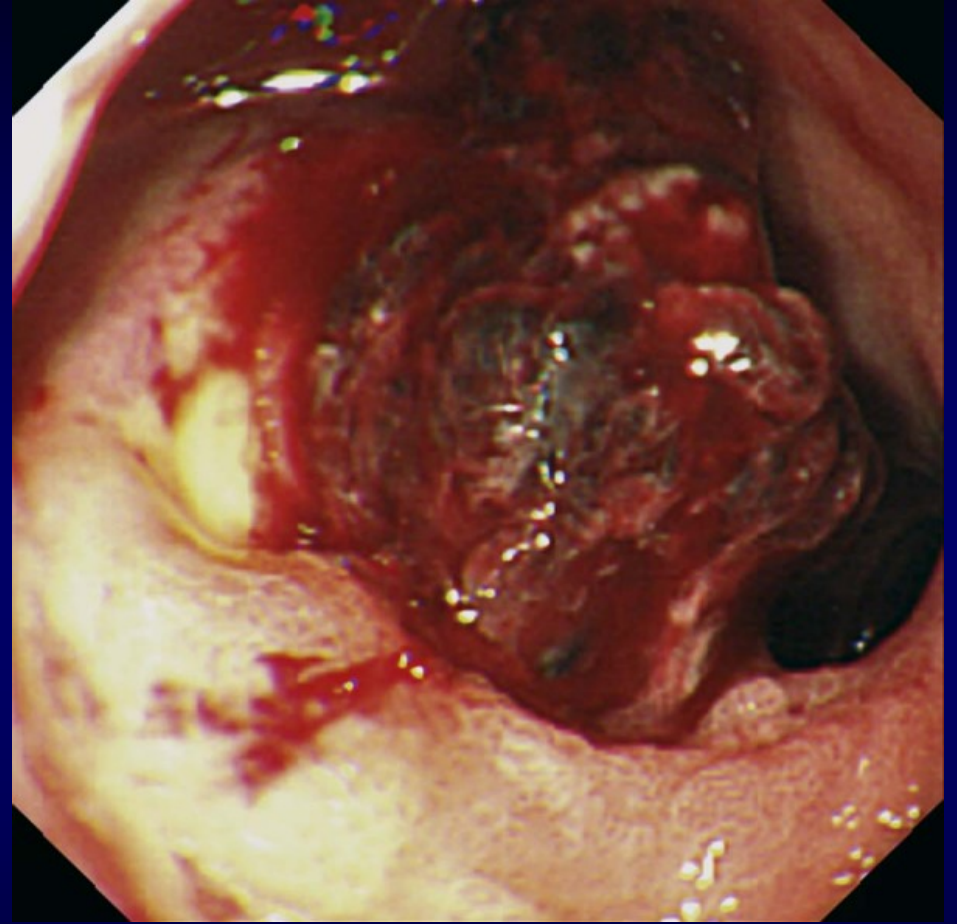
Forrest Ib – oozing bleeding of the gastric ulcer



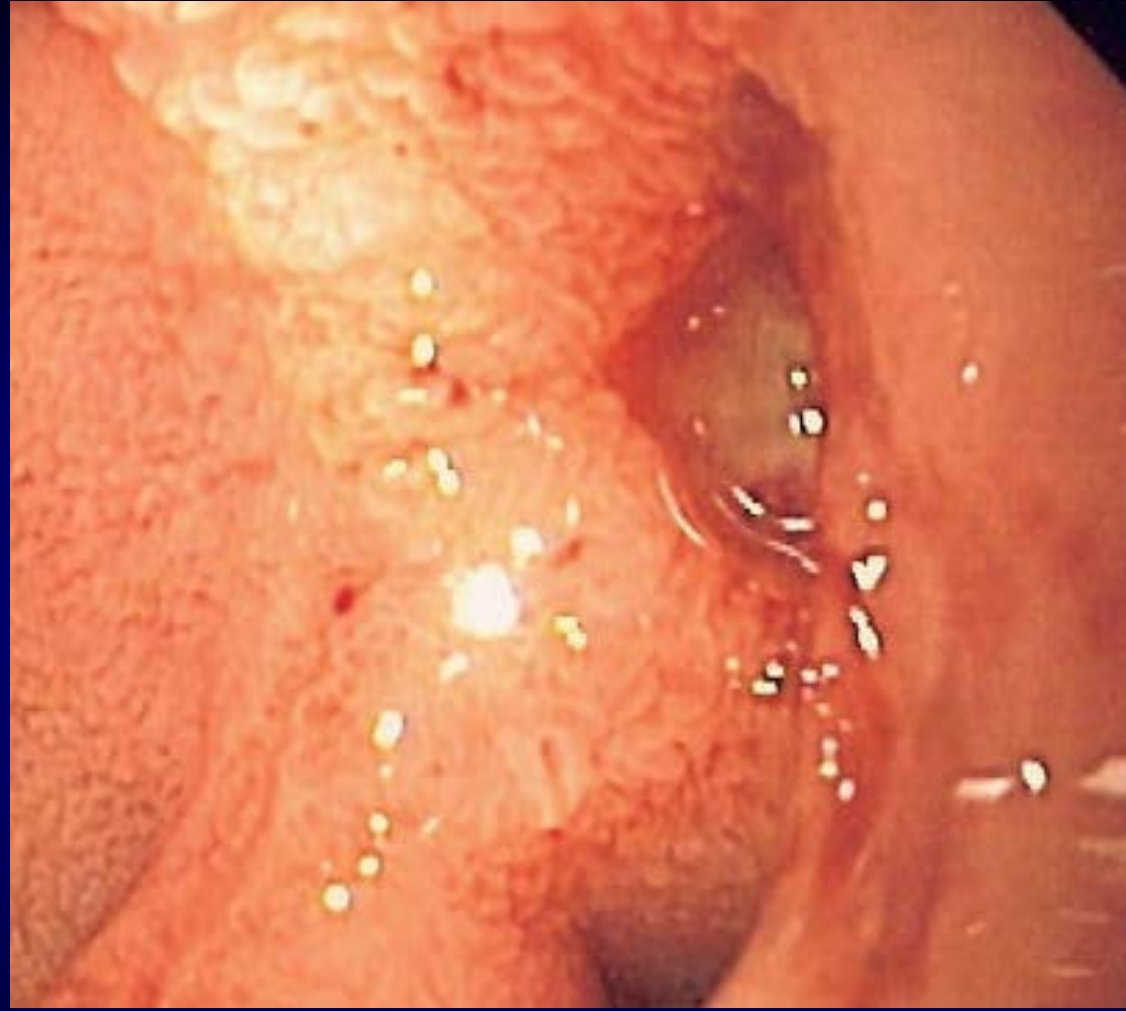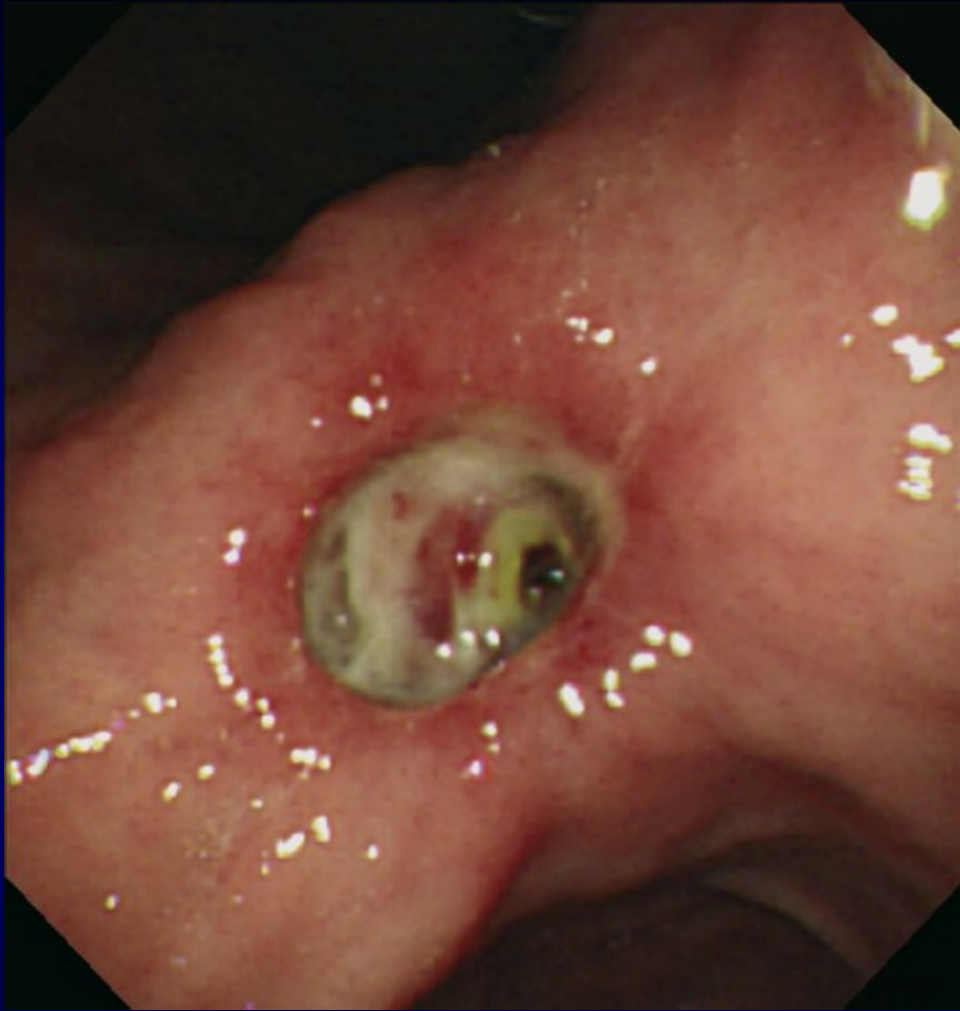Forrest Ib – oozing bleeding of the duodenal ulcer (upper GI endoscopy)



Forrest IIa – Non-bleeding visible vessel of the gastric ulcer.



Forrest IIb – Duodenal bulb ulcer with a fresh adherent clot.



Forreest type IIc – Endoscopic appearance (black ulcer base) of a gastric ulcer at the angularis with a flat spot.

Forreest III – Endoscopy image of a duodenal ulcer in the posterior part of the duodenal bulb without stigmata of recent hemorrhage.

GISCA T.

B 43

06/06/1964

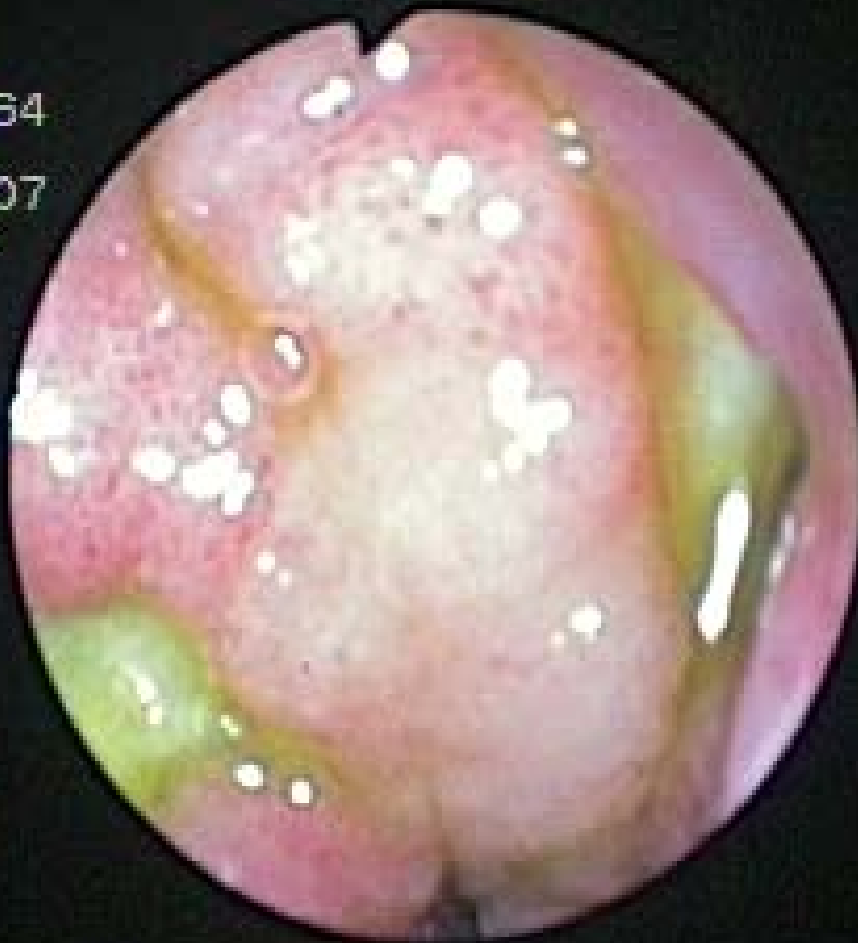10/10/2007

10:34:13

CVP:

D.F:

Er:5 G:L



Forrest IIc (posterior ulcer) – kissing duodenal ulcers (upper GI endoscopy)

Methods of endoscopic hemostasis for bleeding peptic ulcer bleeding

- **Injection therapies** (saline; vasoconstrictors; sclerosing agents (ethanolamine); tissue adhesives (fibrin glue))
- **Thermal therapies** (contact/non-contact)
- **Mechanical therapies**



The NEW ENGLAND
JOURNAL of MEDICINE

Methods of endoscopic hemostasis for bleeding GI ulcer

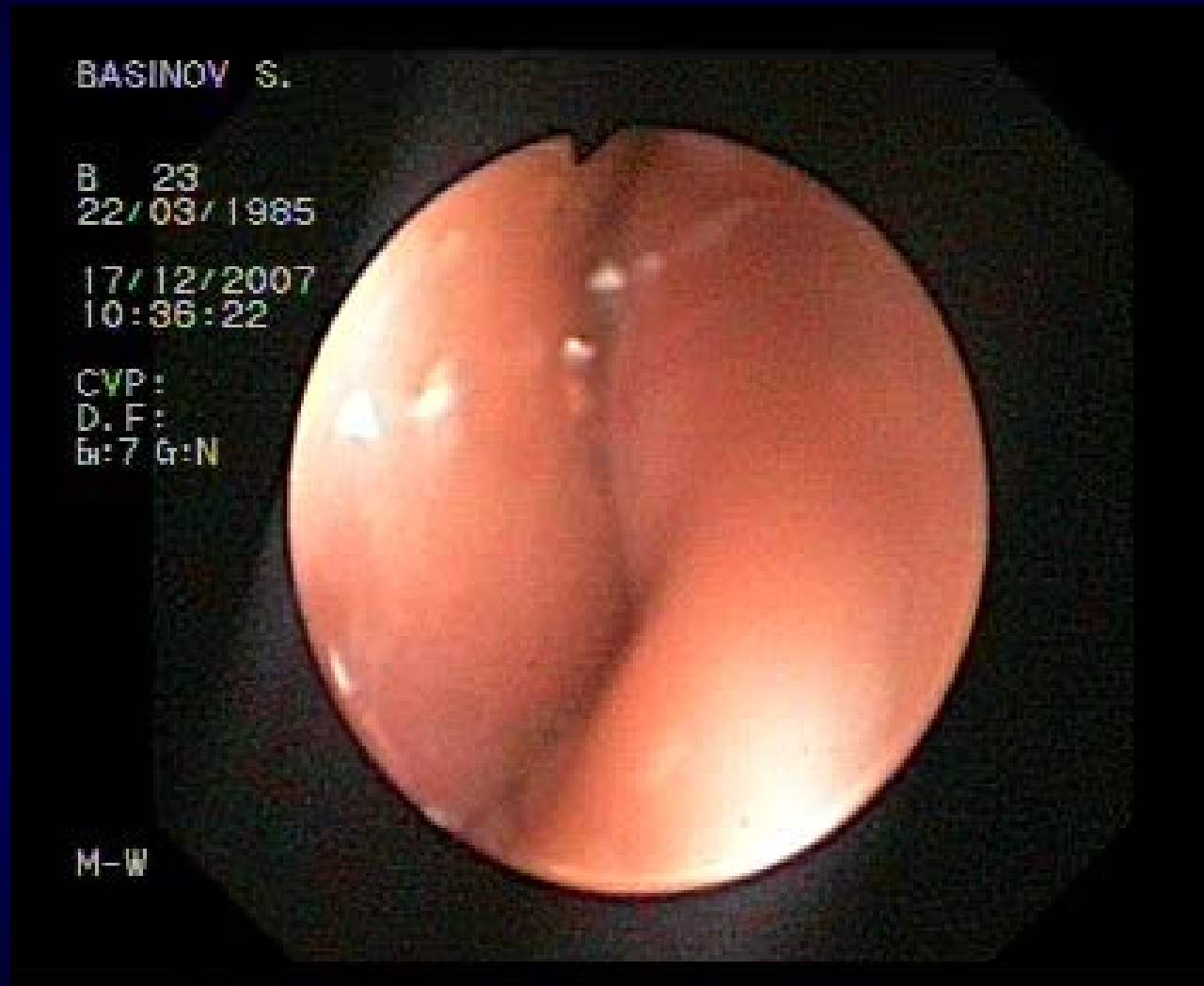Differential diagnosis

The Dieulafoy lesion is a vascular anomaly generally located in proximal stomach and consist of the presence of an artery of heavy caliber in the submucosa and mucosa.

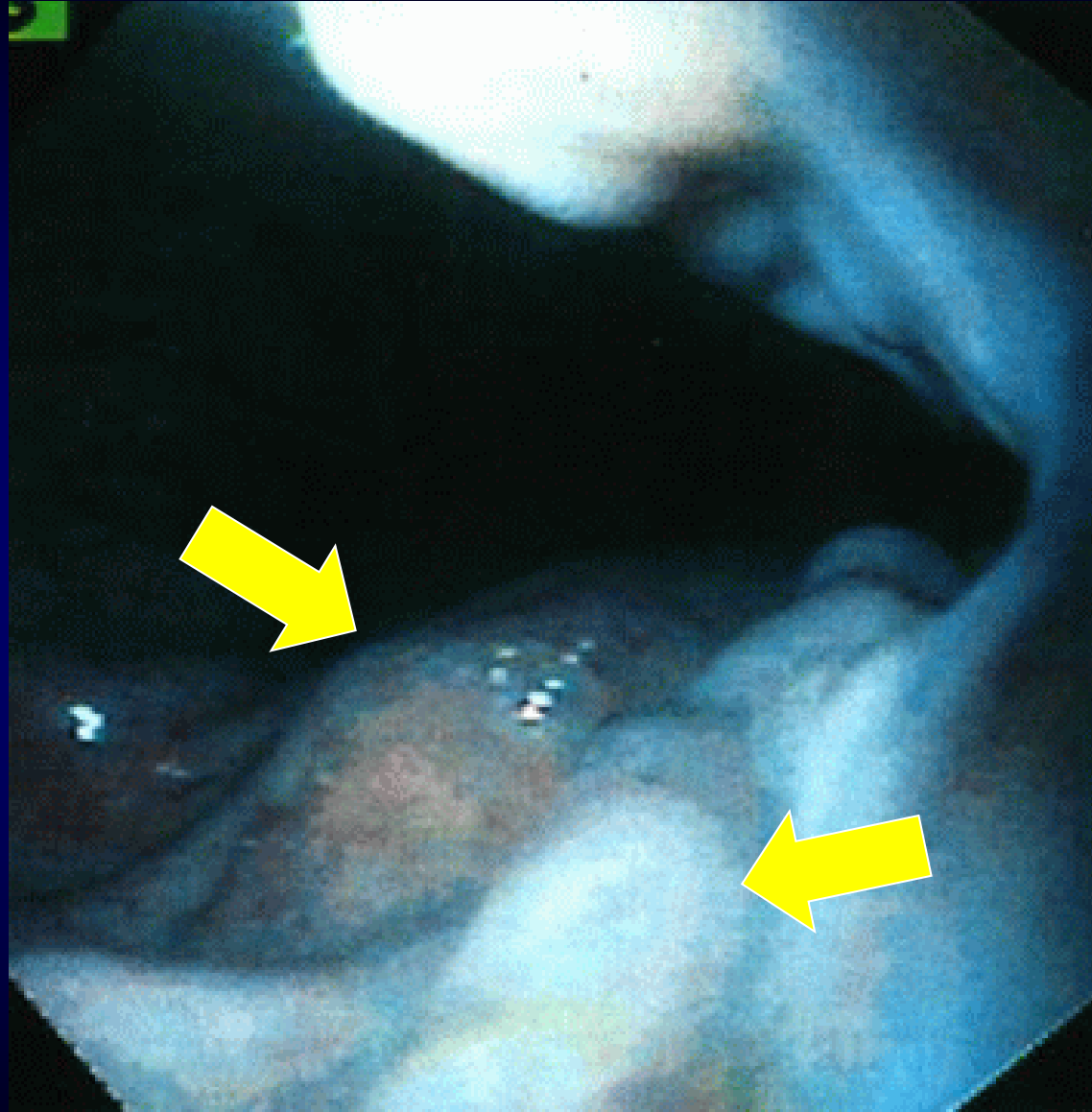
Is a rare cause of gastrointestinal bleeding although potentially fatal etiology of gastrointestinal hemorrhage.

It occurs in fewer than 2% of the episodes of acute digestive hemorrhage.

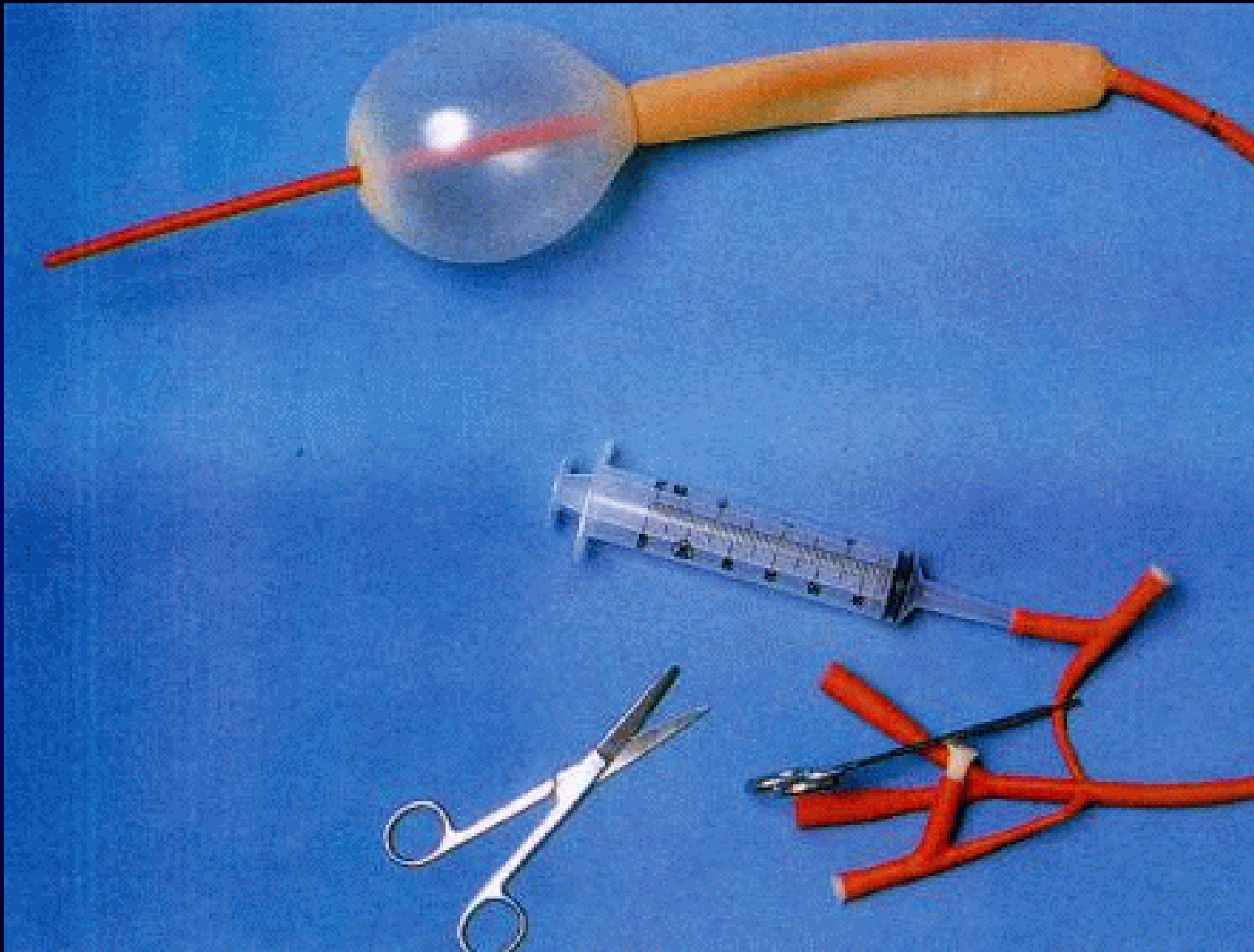
The injury of duodenal Dieulafoy has been communicated in a reduced number of cases and in some of them it has needed surgical treatment.



Differential diagnosis



Esophageal varices



Sengstaken-Blakemore tube

Differential diagnosis

Solcaneanu P/ra

69 ani

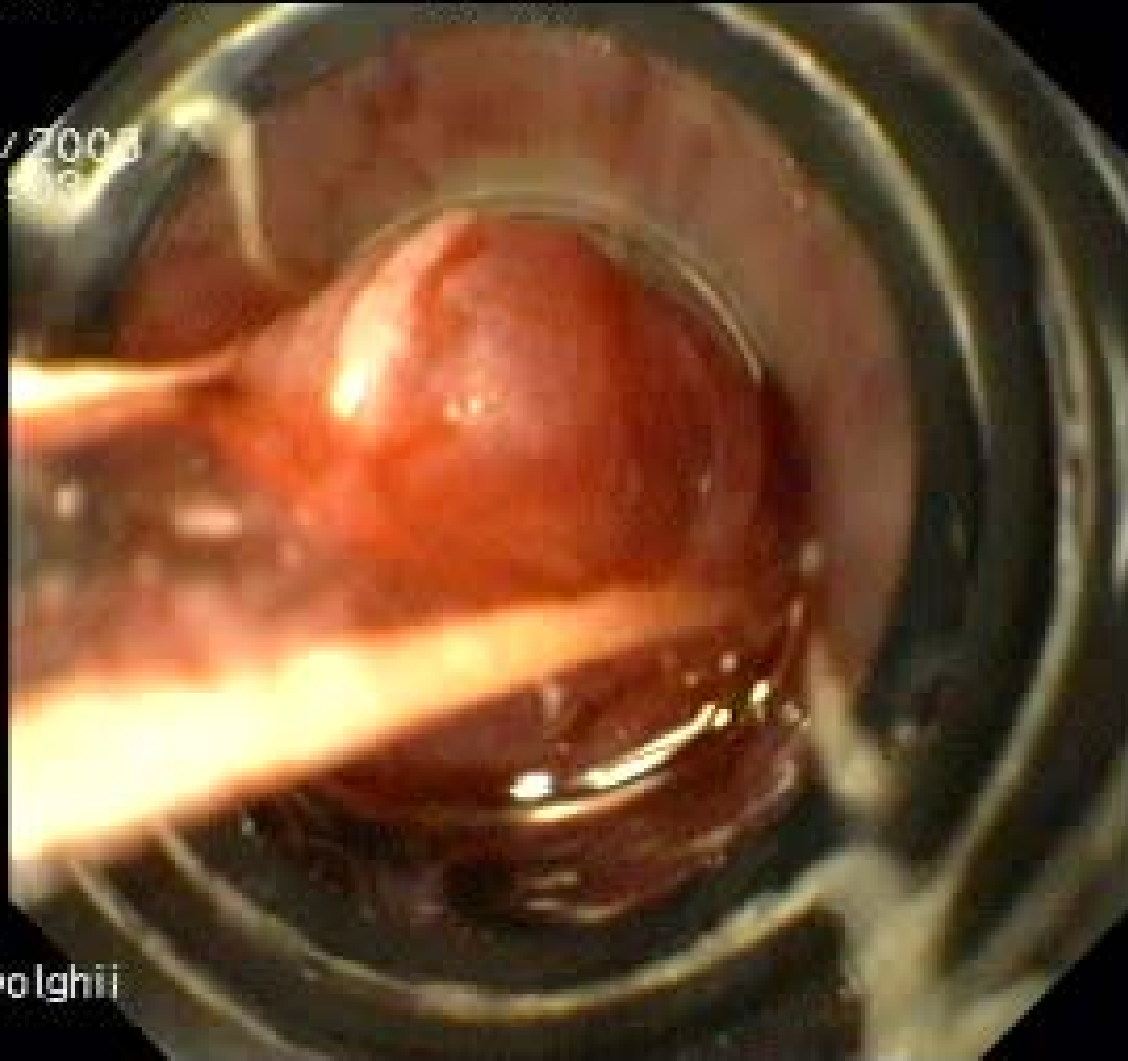28/03/2008

10:03:00

CVP:

D. F:

Et:L

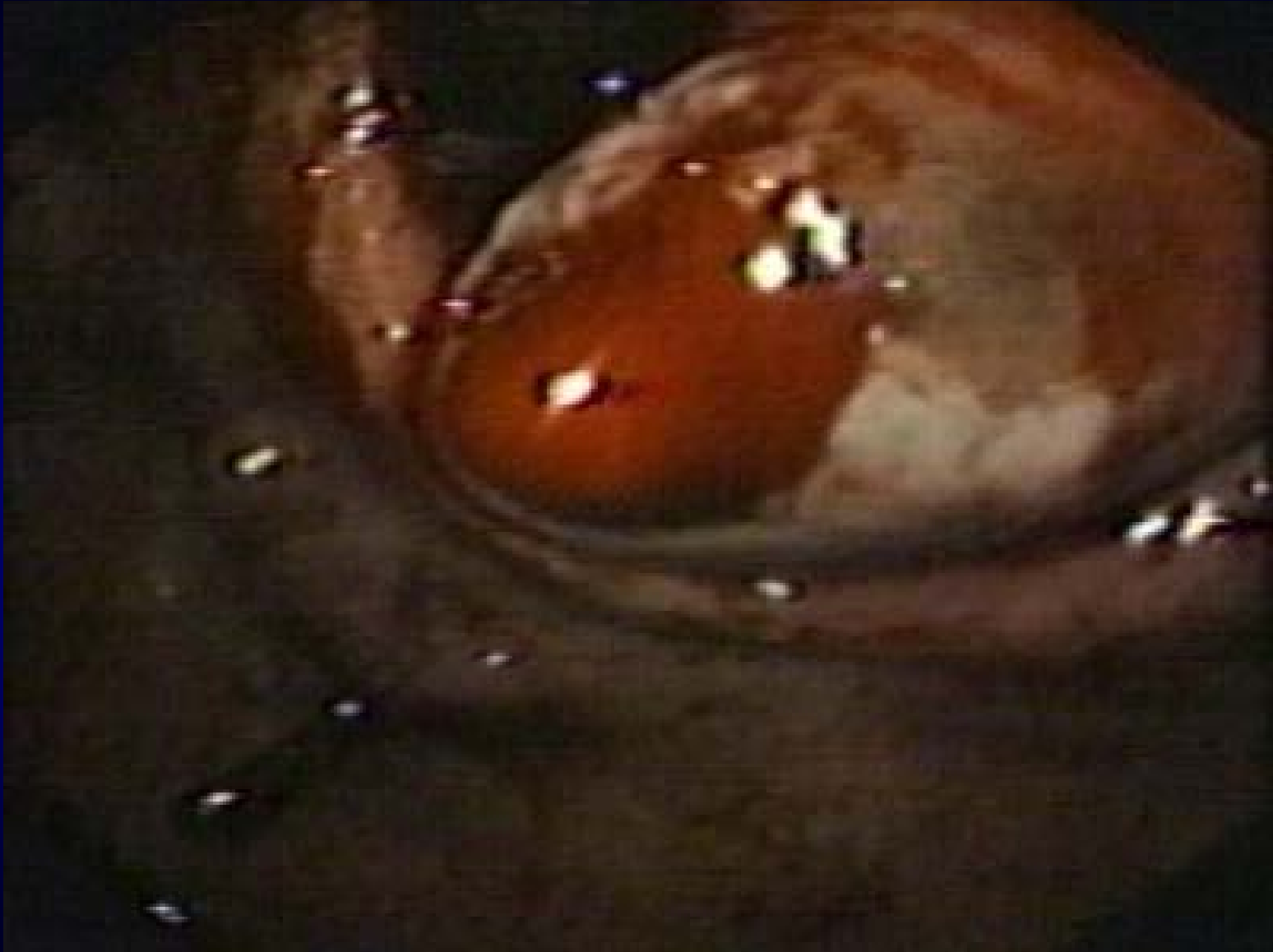

SCMU

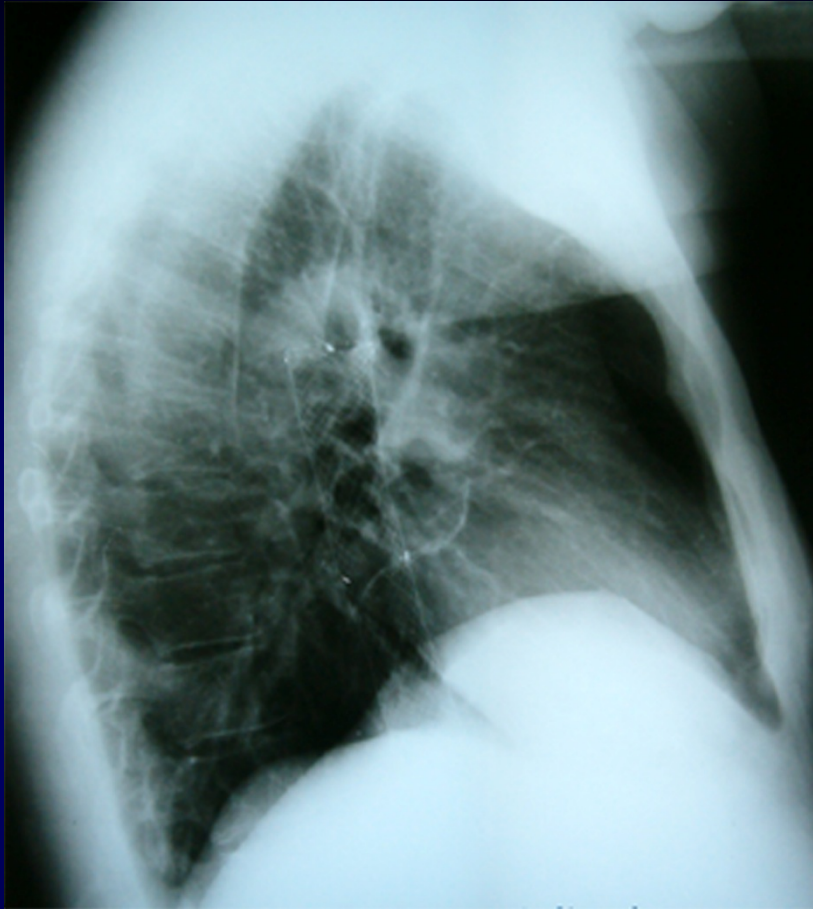
dr. A. Dolghii

Esophageal varices endoscopic band ligation (EBL)

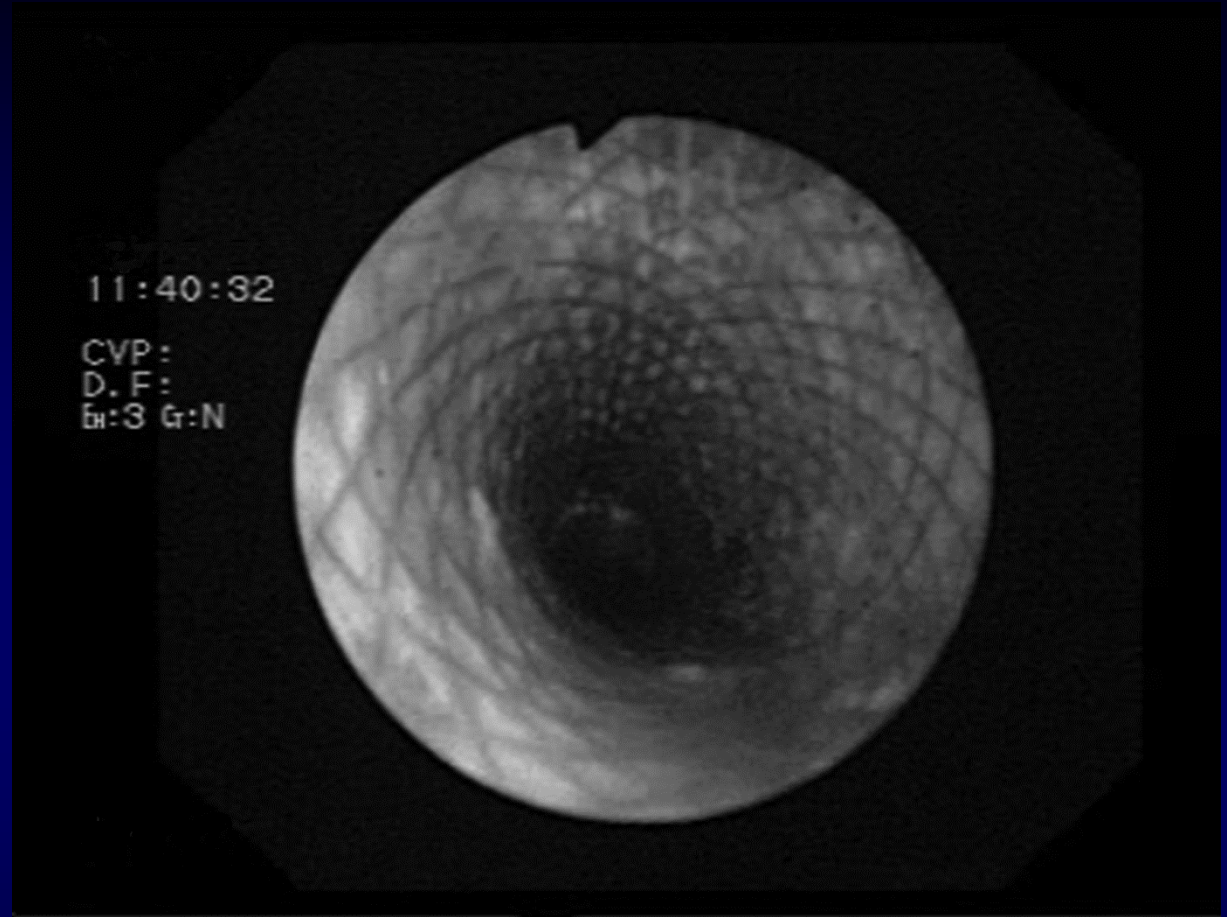
Differential diagnosis



Gastric bleeding varices endoscopic injectional hemostasis using cyanoacrylate glue



self-expanding metal stent in situ (chest x-ray)



self-expanding metal stent in situ (upper GI endoscopy)

A **Mallory-Weiss** tear occurs in the mucous membrane of the lower part of the esophagus or upper part of the stomach, near where they join.

Mallory-Weiss tears are usually caused by forceful or long-term vomiting or coughing. They may also be caused by epileptic convulsions, or anything else that increases the pressure inside the abdomen.

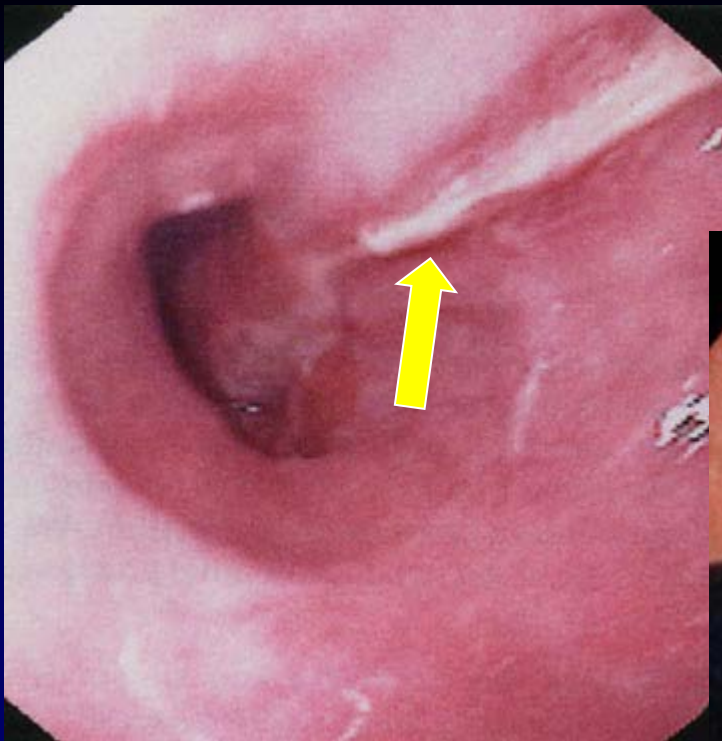
Any condition that leads to violent and lengthy bouts of coughing or vomiting can cause these tears.

It is often associated with alcoholism and eating disorders and there is some evidence that presence of a hiatal hernia is a predisposing condition. Forceful vomiting causes tear of the mucosa at the junction.

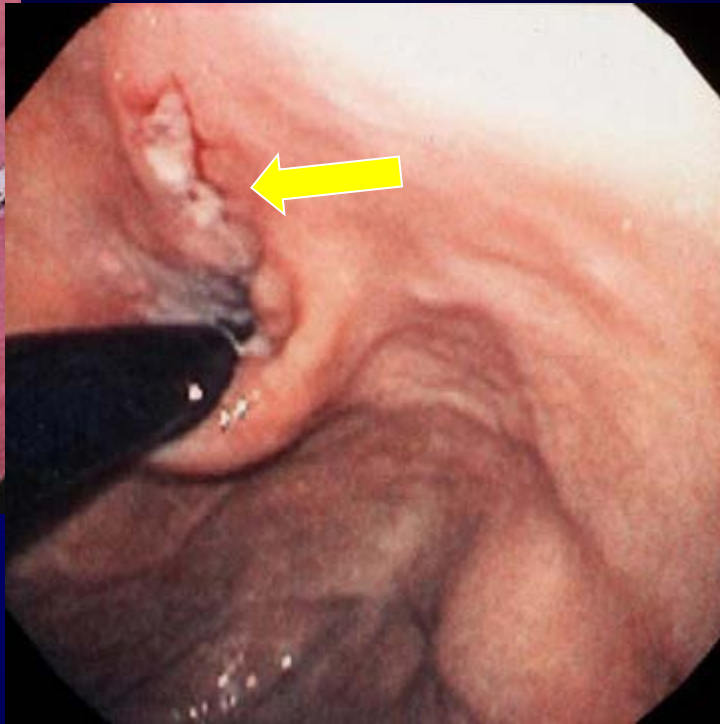
Caroli A., et al.: Minerva dietologica e gastroenterologica. 1989;35(1):7–12.

Symptoms:

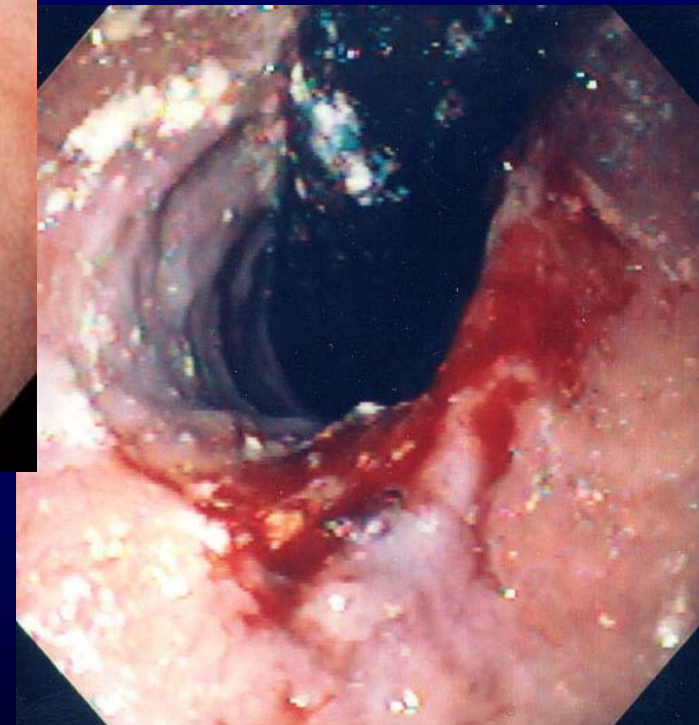
- **Bloody stools**
- **Hematemesis (bright red)**



Mallory-Weiss tear (arrow).
Typical longitudinal mucosal tear with overlying fibrinous exudate extending from the distal esophagus to the gastric cardia.



Mallory-Weiss tear (arrow).
Retroflexed view of the cardia showing the typical location of the tear with a clean base.



Mallory-Weiss tear with a pigmented protuberance and active oozing.



**Mallory-Weiss tear with active hemorrhage during upper GI endoscopy
(endoscopic hemostasis)**

Gastric outlet obstruction

Gastric outlet obstruction (GOO, also known as pyloric obstruction) is not a single entity; it is the clinical and pathophysiological consequence of any disease process that produces a mechanical impediment to gastric emptying.

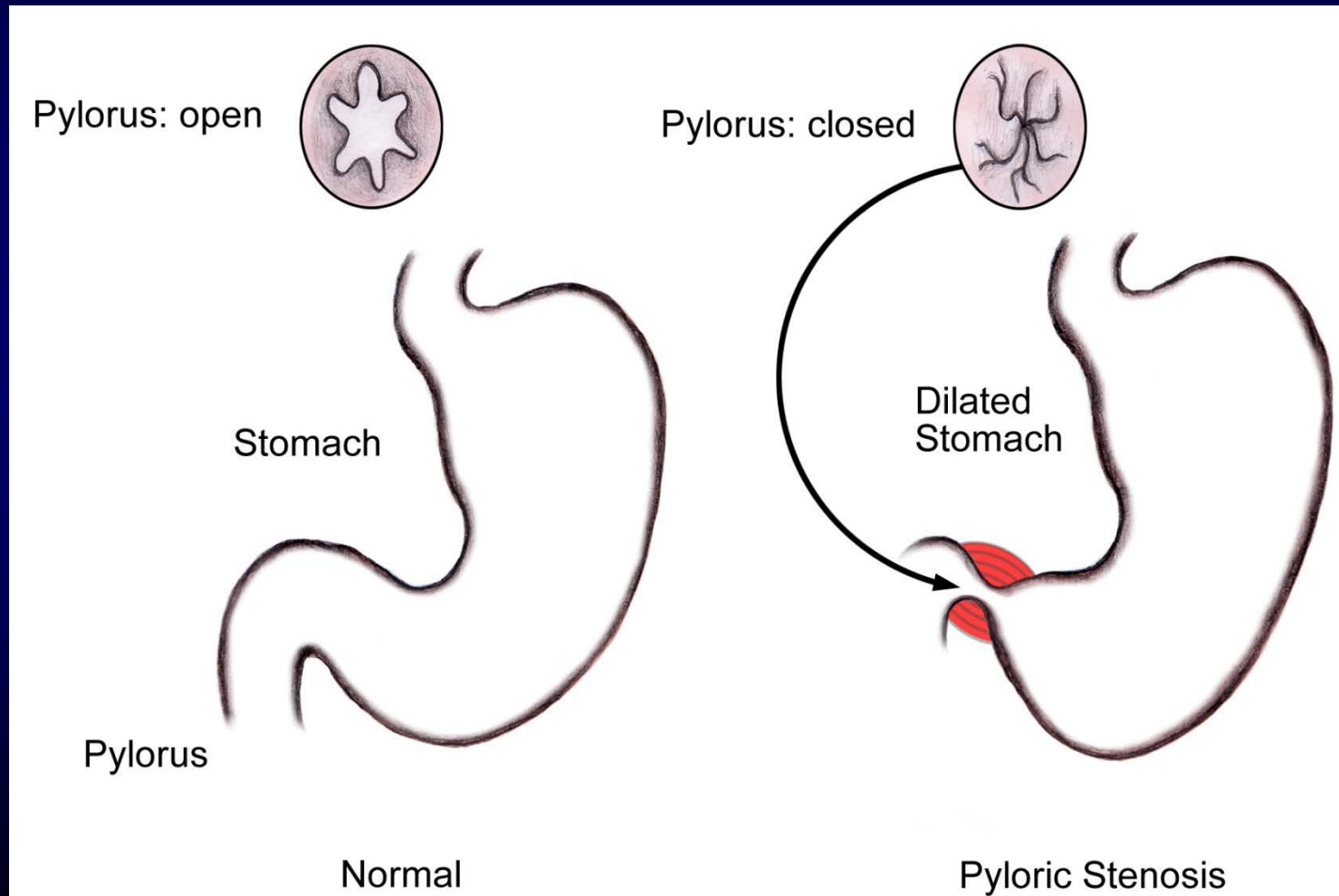
Clinical entities that can result in GOO generally are categorized into 2 well-defined groups of causes—benign and malignant.

This classification facilitates discussion of management and treatment. In the past, when PUD was more prevalent, benign causes were the most common; however, one review shows that only 37% of patients with GOO have benign disease and the remaining patients have obstruction secondary to malignancy.

Gibson JB., et al.: *J Am Coll Surg*.2000;191(1):32-7.

The incidence of GOO has been reported to be less than 5% in patients with PUD, which is the leading benign cause of the problem.

Gibson JB., et al.: *J Am Coll Surg.*2000;191(1):32-7.



TYPES OF STENOSIS

ANTROPYLORIC STENOSIS
STENOSIS OF THE PYLORIC CHANNEL
DUODENAL BULB STENOSIS
POSTBULBAR STENOSIS

PHASES OF STENOSIS

COMPENSATION
SUBCOMPENSATION
DECOMPENSATION

DELAY OF GASTRIC EMPTYING:

- 6-12 HOURS- I
- 12-24 HOURS - II
- MORE THEN 24 HOURS - III

Pathophysiology

Intrinsic or extrinsic obstruction of the pyloric channel or duodenum is the usual pathophysiology of gastric outlet obstruction; the mechanism of obstruction depends upon the underlying etiology.

Patients present with intermittent symptoms that progress until obstruction is complete. **Vomiting is the cardinal symptom.** Initially, patients may demonstrate better tolerance to liquids than solid food.

In a later stage, patients may develop significant weight loss due to poor caloric intake. Malnutrition is a late sign, but it may be very profound in patients with concomitant malignancy

In the acute or chronic phase of obstruction, continuous vomiting may lead to dehydration and electrolyte abnormalities.

When obstruction persists, patients may develop significant and progressive gastric dilatation. The stomach eventually loses its contractility. Undigested food accumulates and may represent a constant risk for aspiration pneumonia.

Presentation

Nausea and vomiting are the cardinal symptoms of gastric outlet obstruction. Vomiting usually is described as nonbilious, and it characteristically contains undigested food particles.

Patients with gastric outlet obstruction resulting from PUD or incomplete obstruction typically present with symptoms of gastric retention, including early satiety, bloating or epigastric fullness, indigestion, anorexia, nausea, vomiting, epigastric pain, and weight loss. They are frequently malnourished and dehydrated and have a metabolic insufficiency. Weight loss is frequent when the condition approaches chronicity and is most significant in patients with malignant disease.

Physical examination often demonstrates the presence of chronic dehydration and malnutrition. A dilated stomach may be appreciated as a tympanitic mass in the epigastric area and/or left upper quadrant.

KUSSMAUL'S SIGN - DISTENDED STOMACH MAY BE SEEN THROUGH ANTERIOR ABDOMINAL WALL WITH VISIBLE PERISTALSIS MOVEMENTS

- **Dehydration and electrolyte abnormalities can be demonstrated by routine laboratory examinations.**
- **Increases in BUN and creatinine are late features of dehydration.**
- **Prolonged vomiting causes loss of hydrochloric (HCl) acid and produces an increase of bicarbonate in the plasma to compensate for the lost chloride and sodium.**
- **The result is a hypokalemic hypochloremic metabolic alkalosis. Alkalosis shifts the intracellular potassium to the extracellular compartment, and the serum positive potassium is increased.**
- **With continued vomiting, the renal excretion of potassium increases in order to preserve sodium. The adrenocortical response to hypovolemia intensifies the exchange of potassium for sodium at the distal tubule, with subsequent aggravation of the hypokalemia.**

SYNDROME OF DARROW INCLUDES:

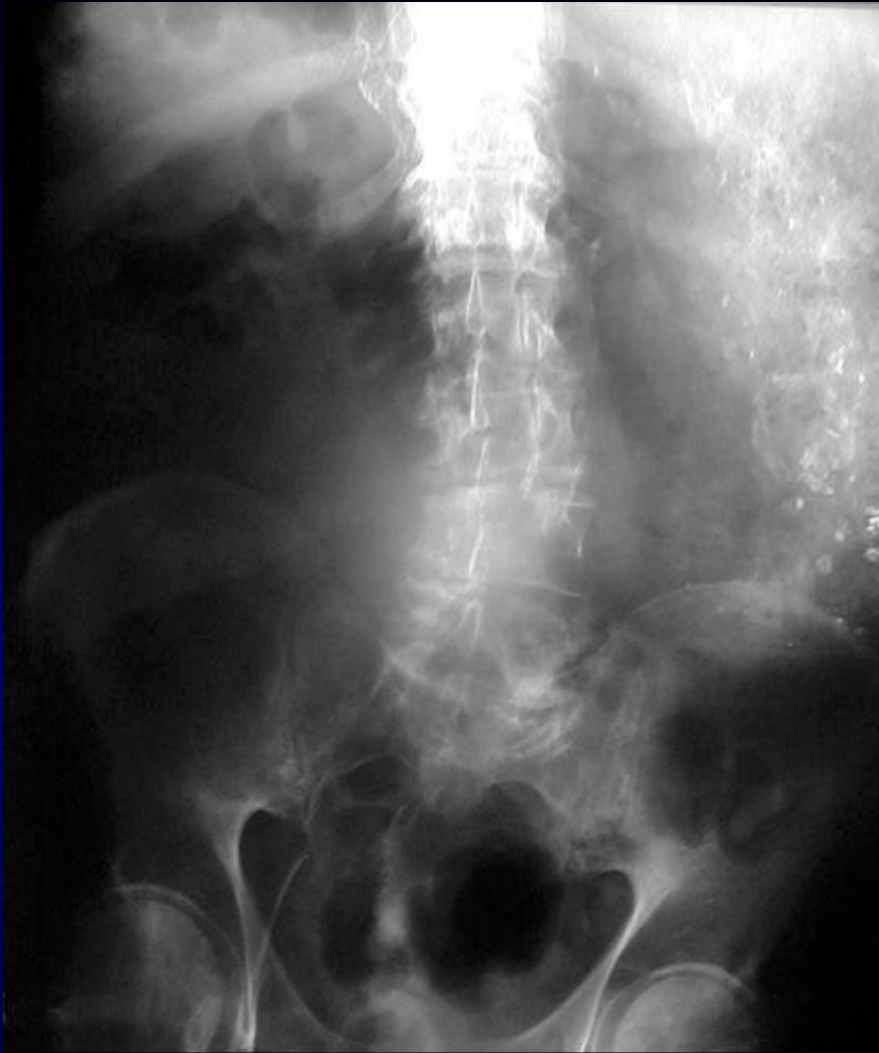HYPOCHLOREMIA,

HYPOKALEMIA,

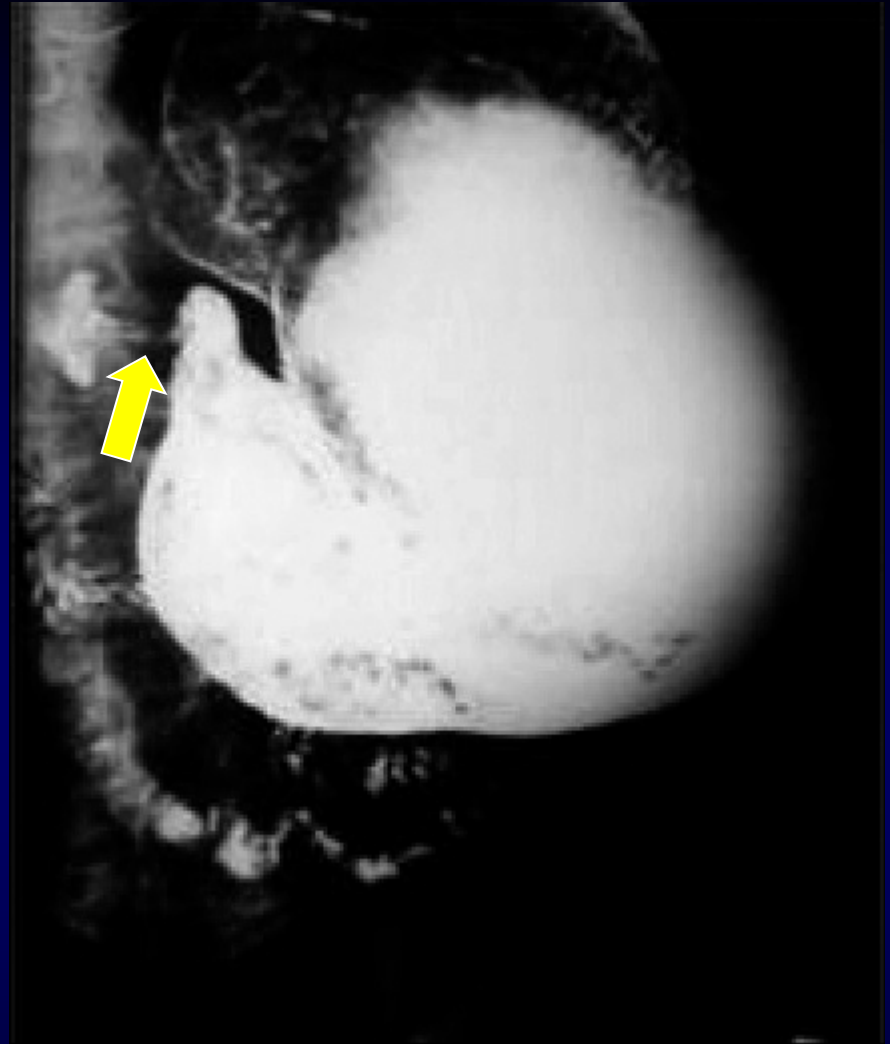
HYPOCALCEMIA,

ALKALOSIS

Darrow DC., et al.: Clin Invest. 1948;27(2):198-208.

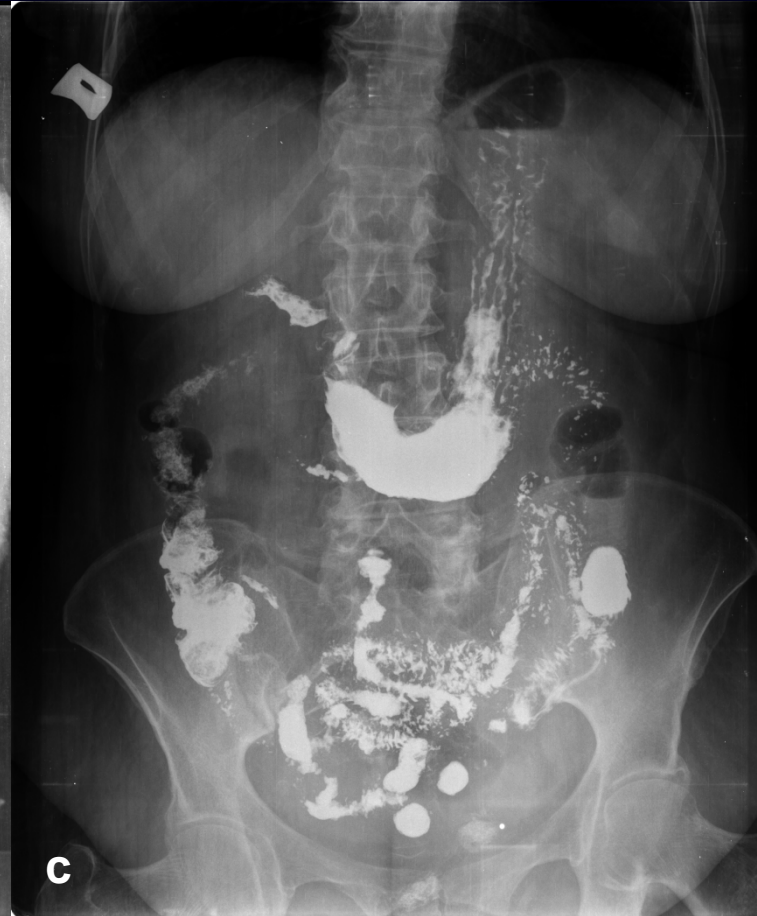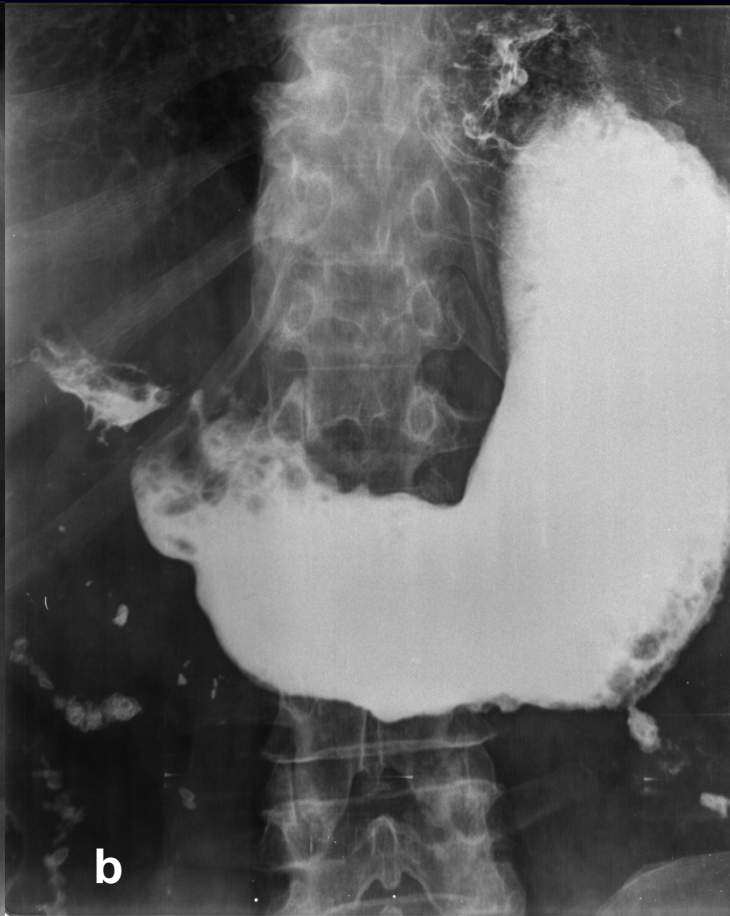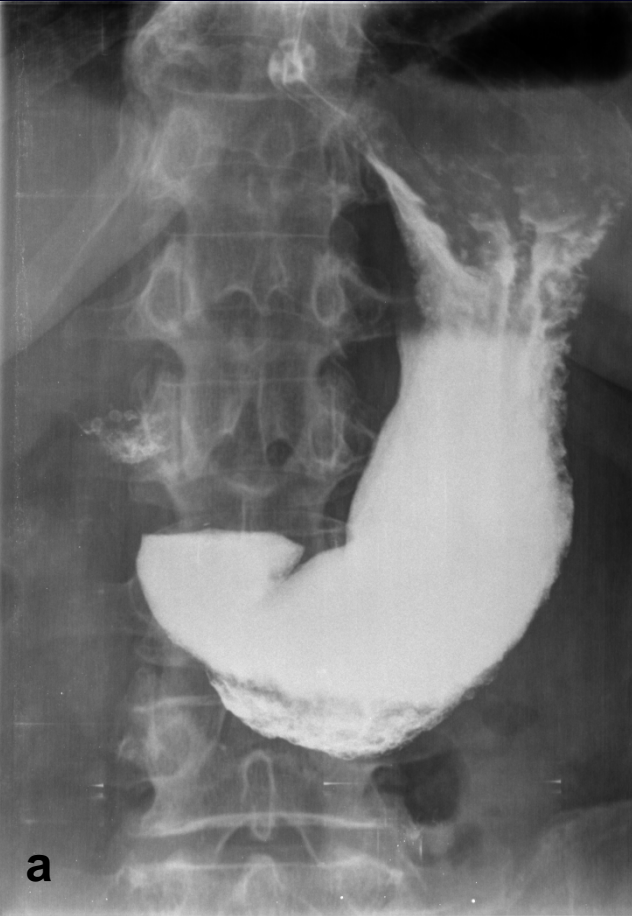


Plain radiograph of the abdomen. Enlarged stomach with calcified content.



Contrast study demonstrating an enlarged stomach. The point of obstruction is visualized at the pyloric-duodenal junction (string sign-arrow).

DELAY OF GASTRIC EMPTYING



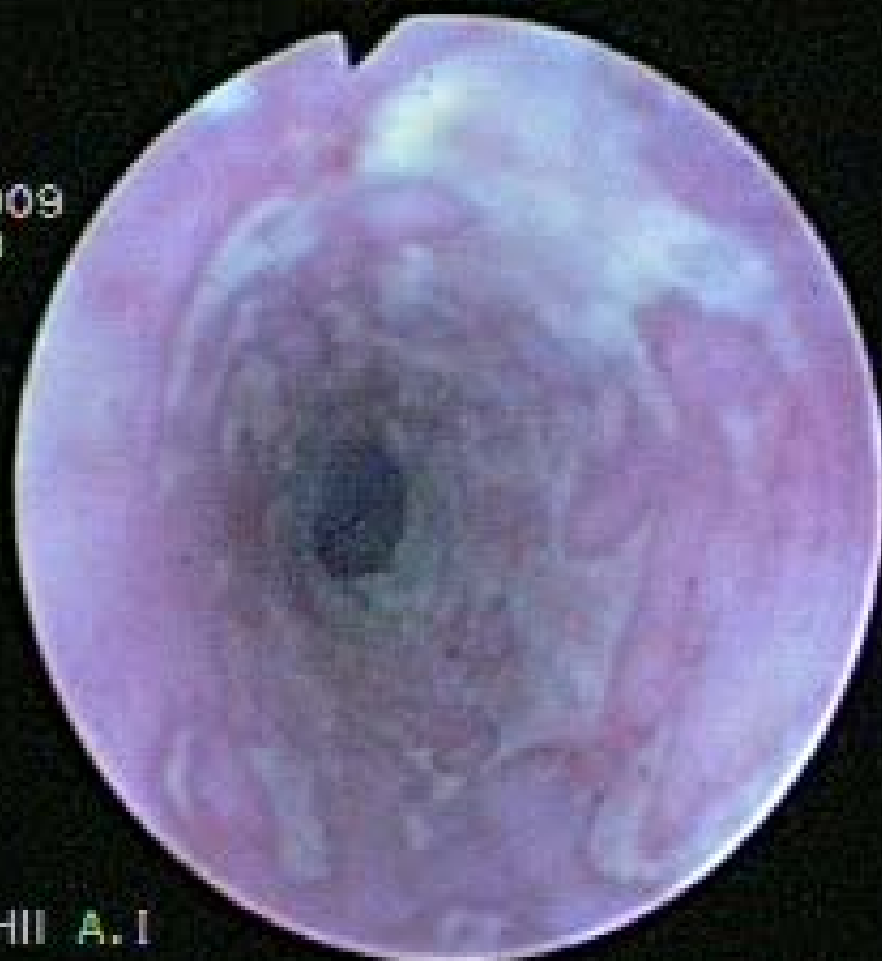Upper GI series (barium meal):
A – upon administration
B – 6 hours after administration
C – 24 hours after administration

ROSCA V.

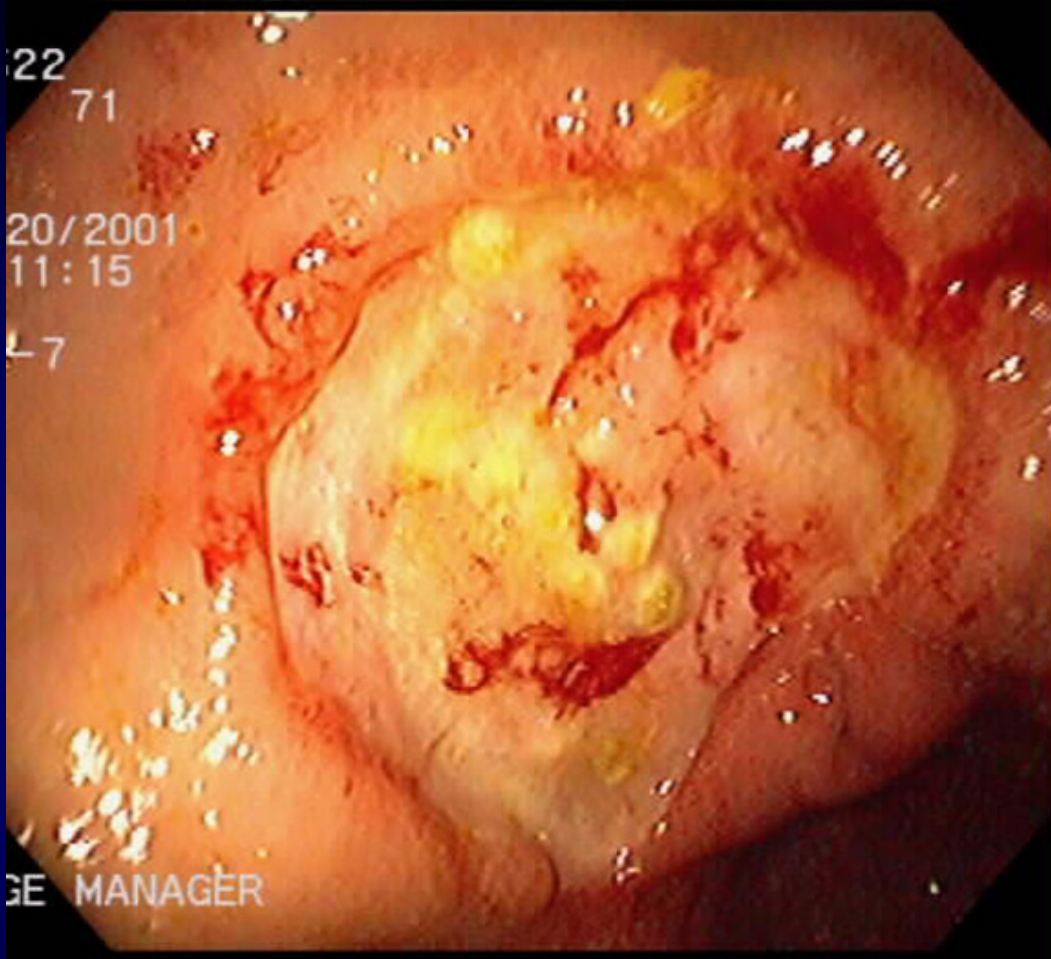
B 52

24/02/2009
15:41:19

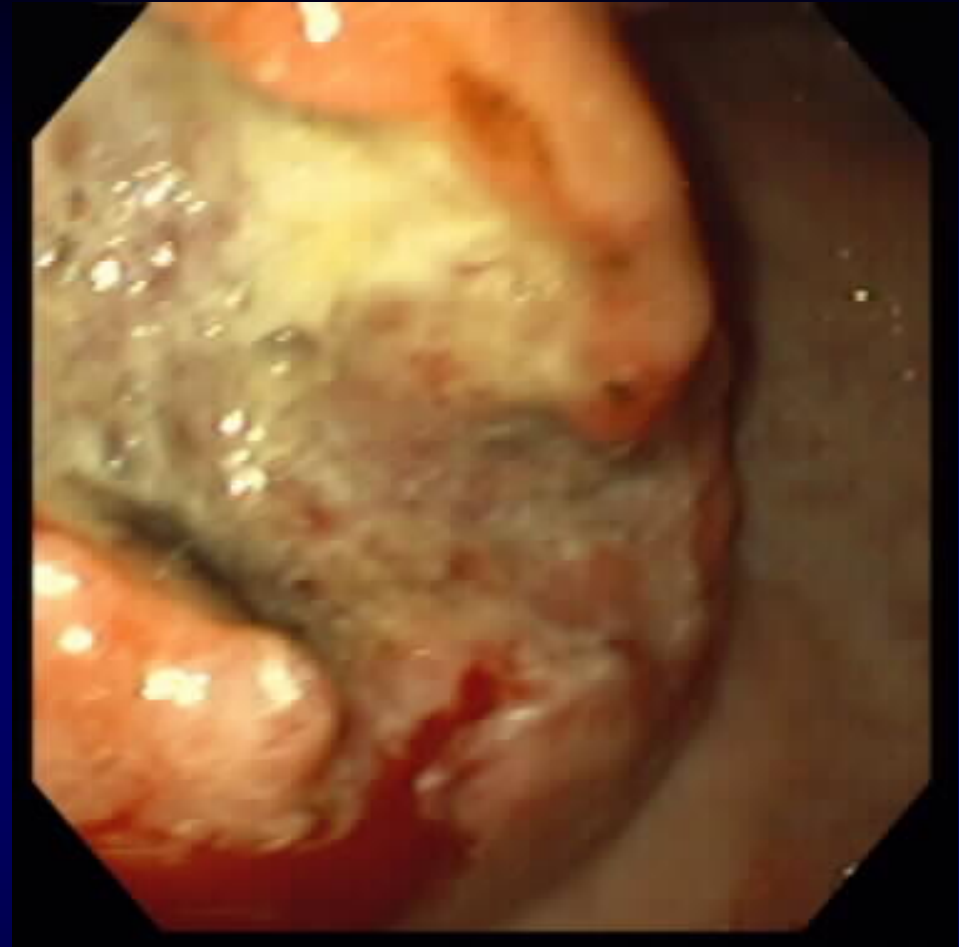CVP:
D.F:
Et: 7 Gr:L



D-r DOLGHII A.I



Gastric ulcer with punched-out ulcer base with whitish fibrinoid exudates.



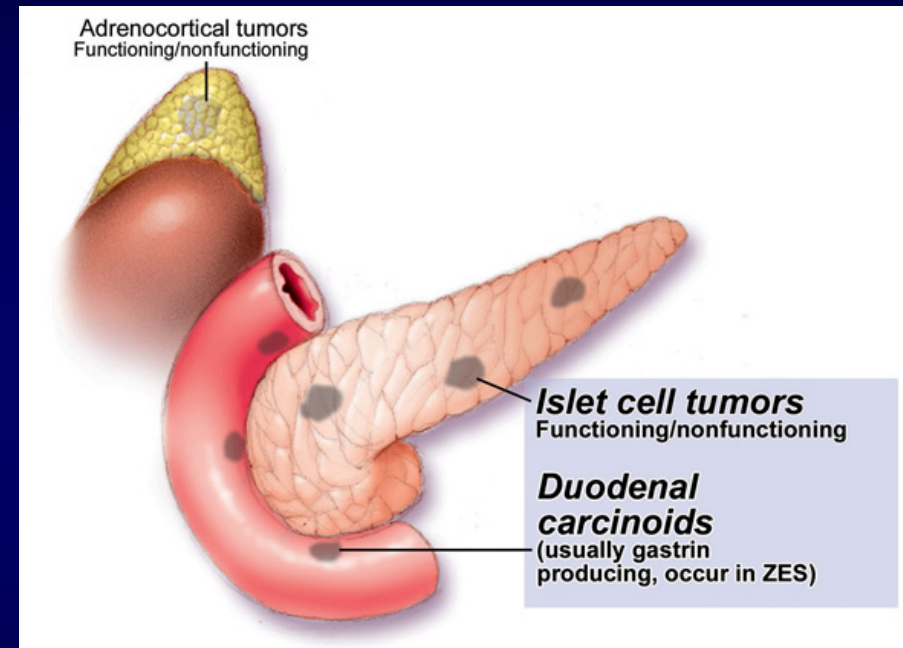
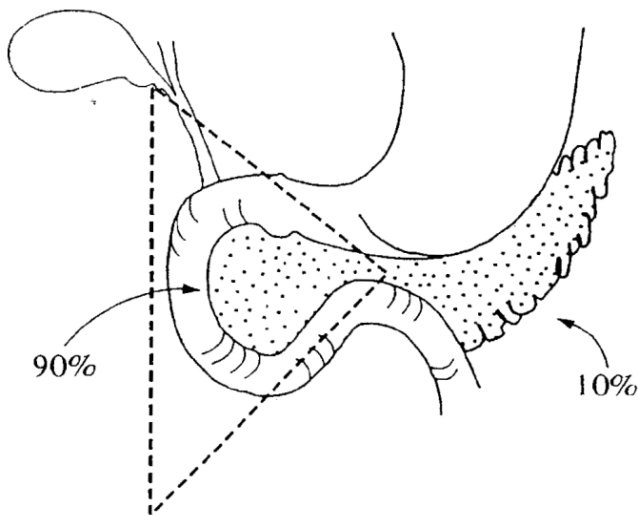
Gastric cancer. Note the irregular heaped up overhanging margins.

Zollinger-Ellison syndrome

Zollinger-Ellison syndrome (ZES) is caused by a non-beta islet cell, gastrin-secreting tumor of the pancreas that stimulates the acid-secreting cells of the stomach to maximal activity, with consequent gastrointestinal mucosal ulceration.

Alternative names: Z-E syndrome; Gastrinoma

ZES may occur sporadically or as part of an autosomal dominant familial syndrome called multiple endocrine neoplasia type 1 (MEN 1).

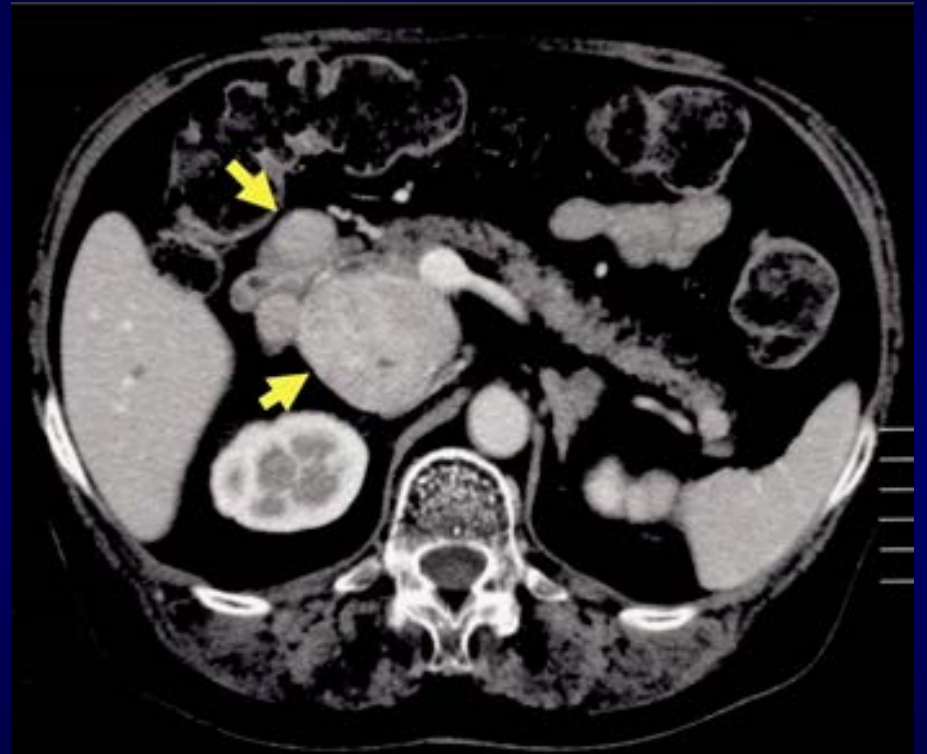
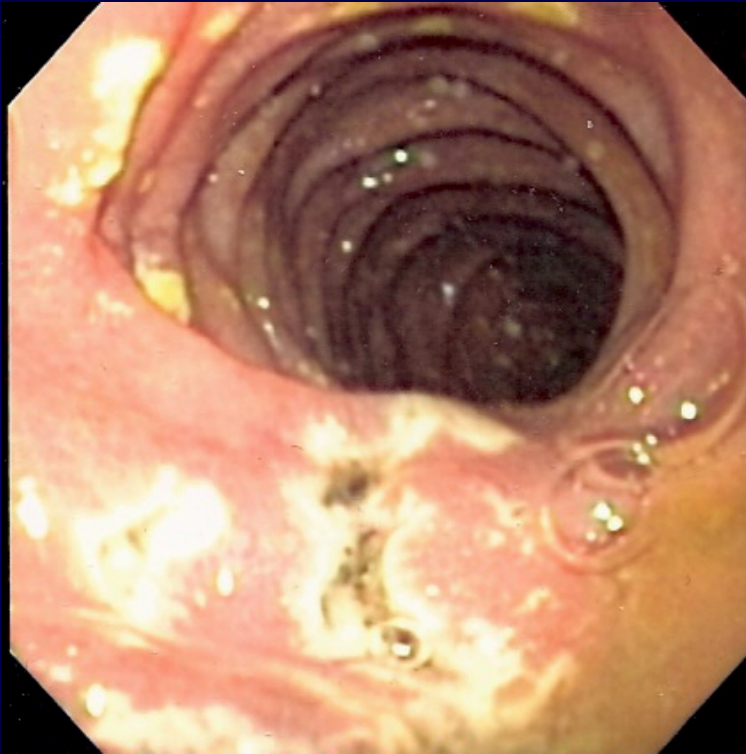

Gastrinoma triangle, over 90% of gastrinomas are found within in the limits of this anatomic triangle.

Stabile BE., et al.: Am J Surg. 1984;147(1):25-31.

Incidence – 1 in 2.5 mln, 2/3 malignant

Symptoms:
Abdominal pain;
Diarrhea;
Hematemesis (occasional)



The primary tumor is usually located in the duodenum, the pancreas, and abdominal lymph nodes, but ectopic locations have also been described (eg, heart, ovary, gall bladder, liver, kidney).

Tests include:

Abdominal CT scan

Endoscopic ultrasound

Exploratory surgery

Gastrin blood level (normal values are generally **less than 100 pg/mL**)

Octreotide scan

Secretin simulation test (normal value depends on laboratory Gastrin >110 pg/mL).

The secretin test is preferred over the calcium test because of its greater sensitivity and simplicity.

The recommended criteria are a 200 pg/mL increase for the secretin test and a 395 pg/mL increase for the calcium test.

Frucht H., et al.: Ann Intern Med. 1989;111(9):713-22.

Berna MJ., et al.: Medicine (Baltimore). 2006;85(6):331-64.

Kuiper P., et al.: Pancreatology. 2010;10(1):14-8.

- Proton pump inhibitors (omeprazole, lansoprazole) are now the first choice for treating Zollinger-Ellison syndrome. These drugs reduce acid production by the stomach, and promote healing of ulcers in the stomach and small intestine. They also relieve abdominal pain and diarrhea.
- Surgery to remove a single gastrinoma may be done if there is no evidence that it has spread to other organs (such as lymph nodes or the liver).
- Surgery on the stomach (gastrectomy) to control acid production is rarely needed today.

Even with early diagnosis and surgery to remove the tumor, the cure rate is relatively low. However, gastrinomas grow slowly, and patients may live for many years after the tumor is discovered. Acid-suppressing medications are very effective at controlling the symptoms of too much acid production.

QUESTIONS?

