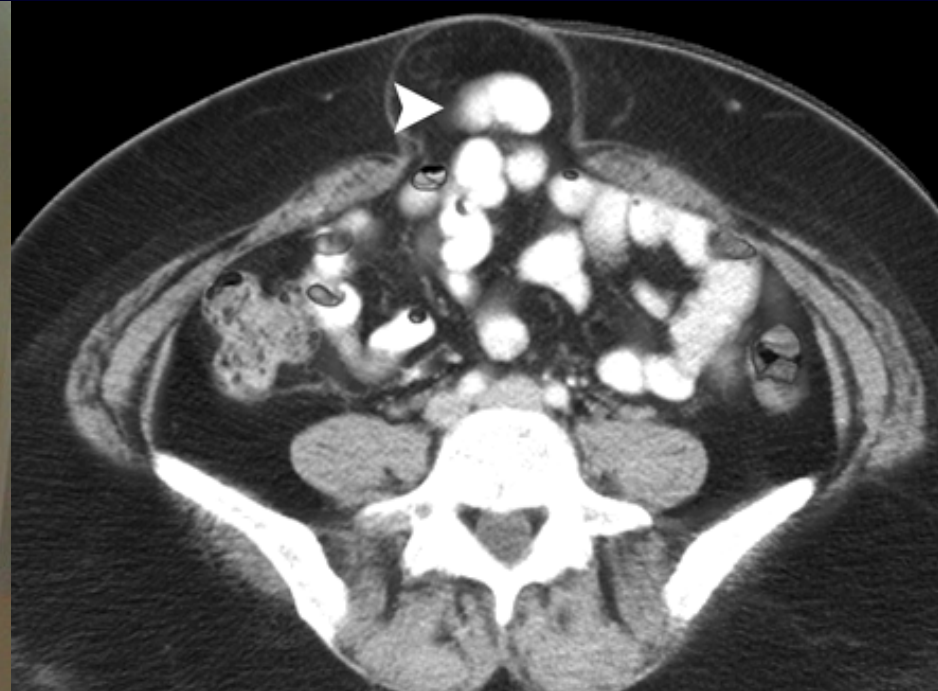
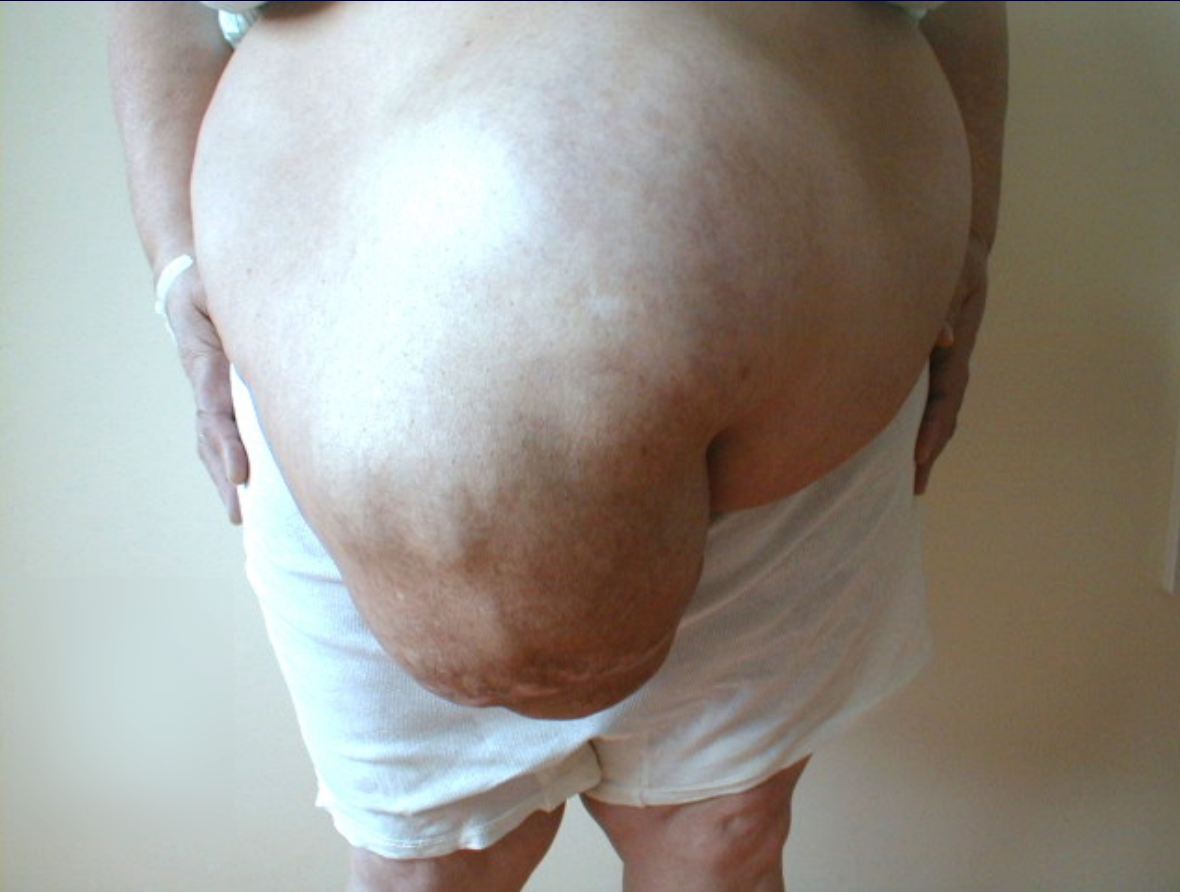
Hernia

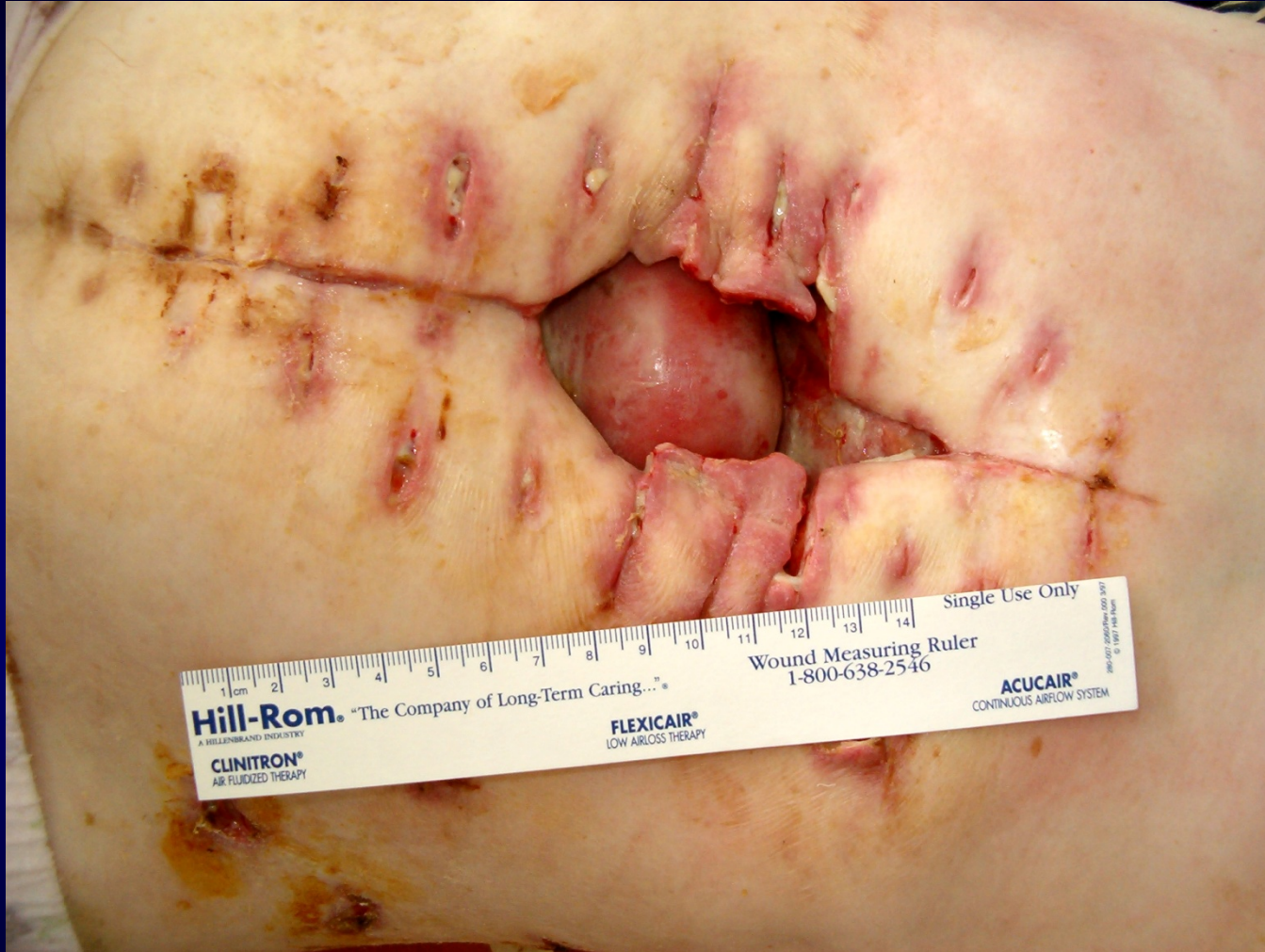Catedra de Chirurgie nr.1 „Nicolae Anestiadi”

Definition


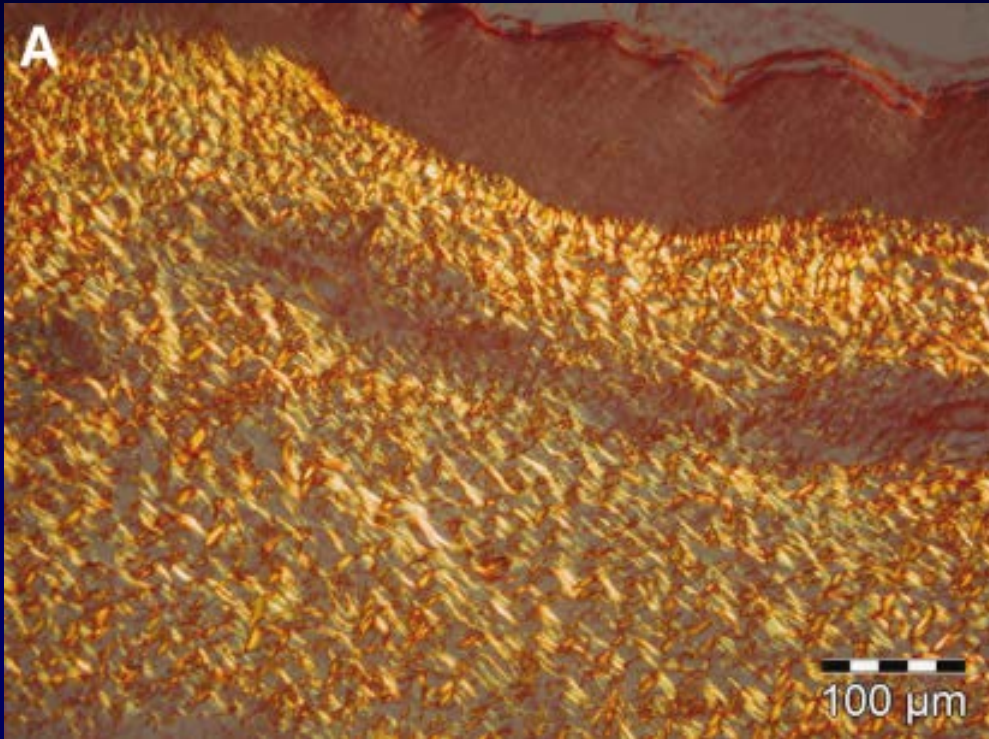


A **hernia** is a protrusion of abdominal contents (internal organs) through the fascia of the abdominal wall.

Definition



Hernia – A Collagen Disease?



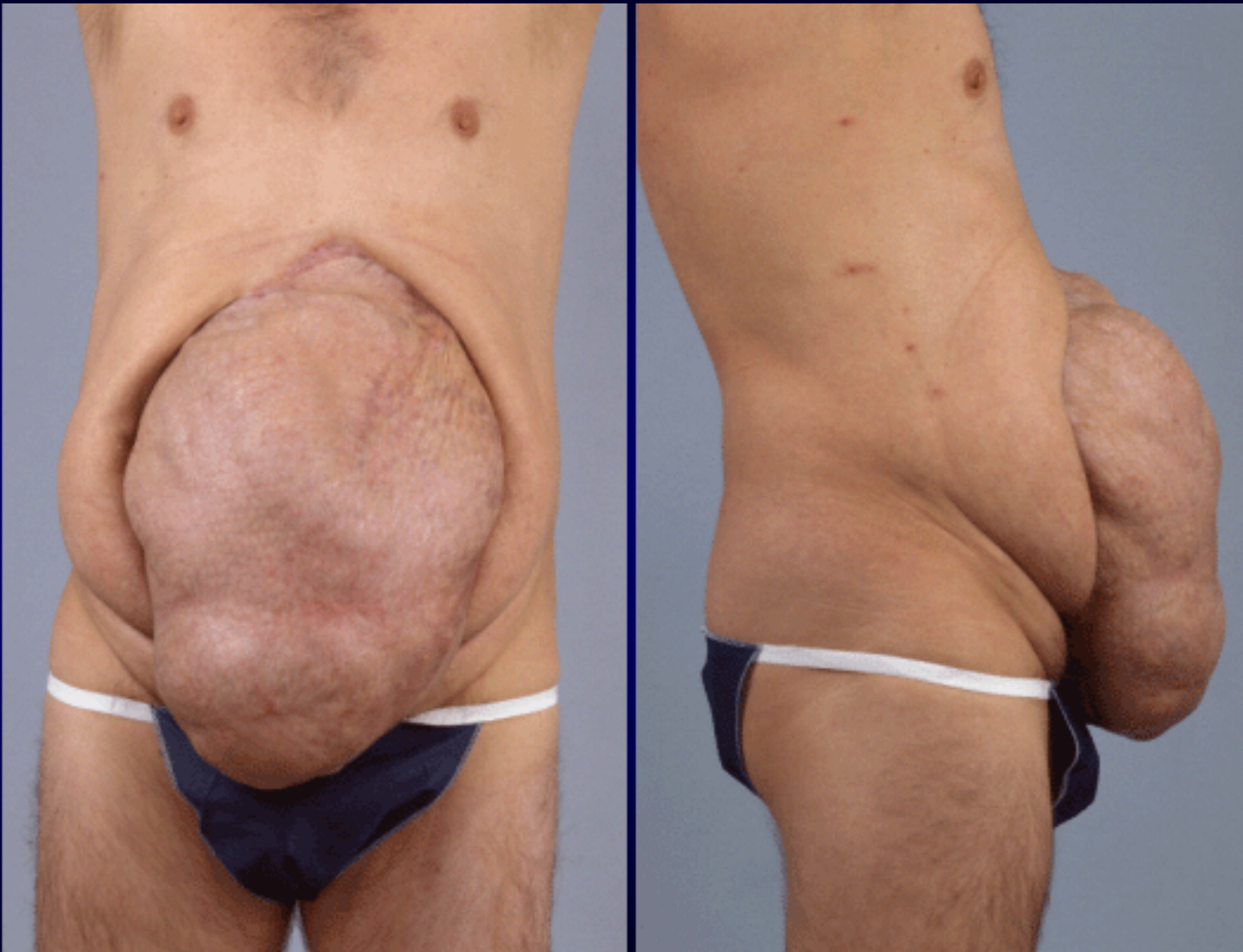Recurrent inguinal hernia

Decreased collagen type I/III ratio → recurrence

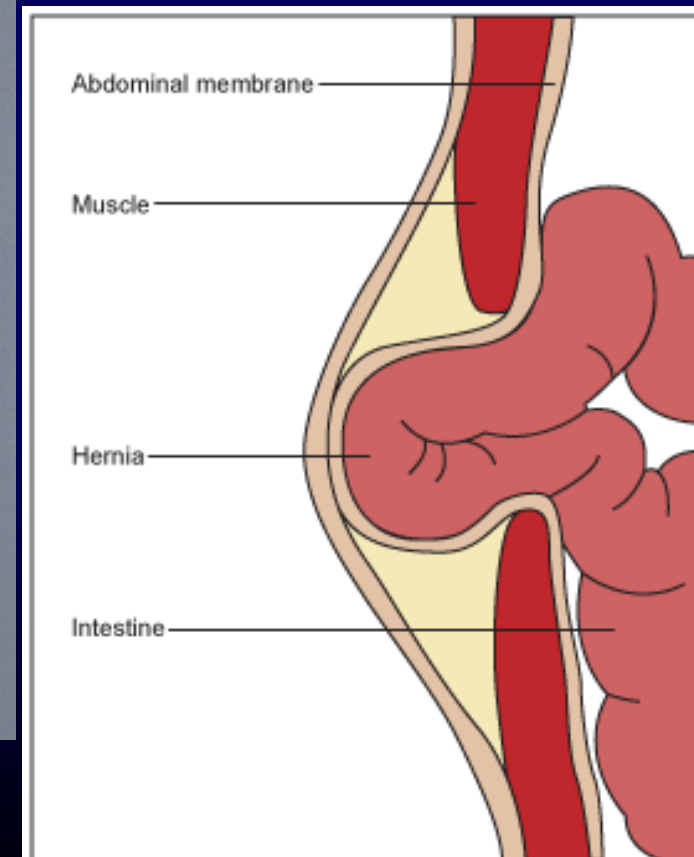
Collagen types I (red)

Collagen types III (pale green)

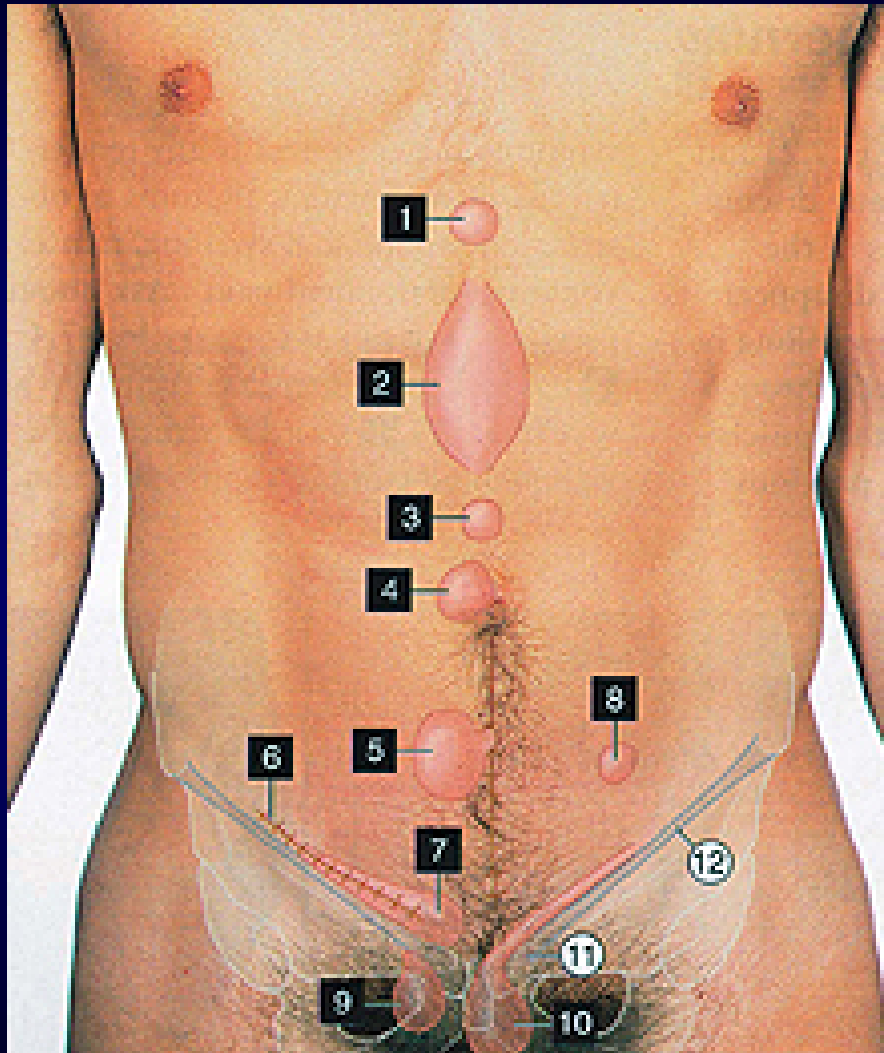
Components of Hernia



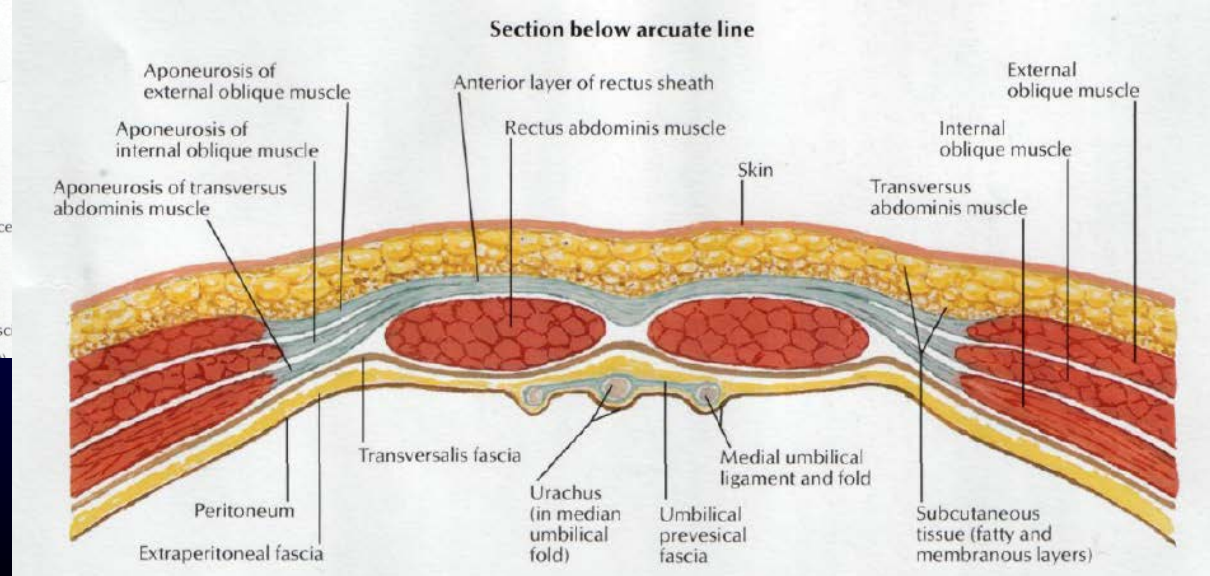
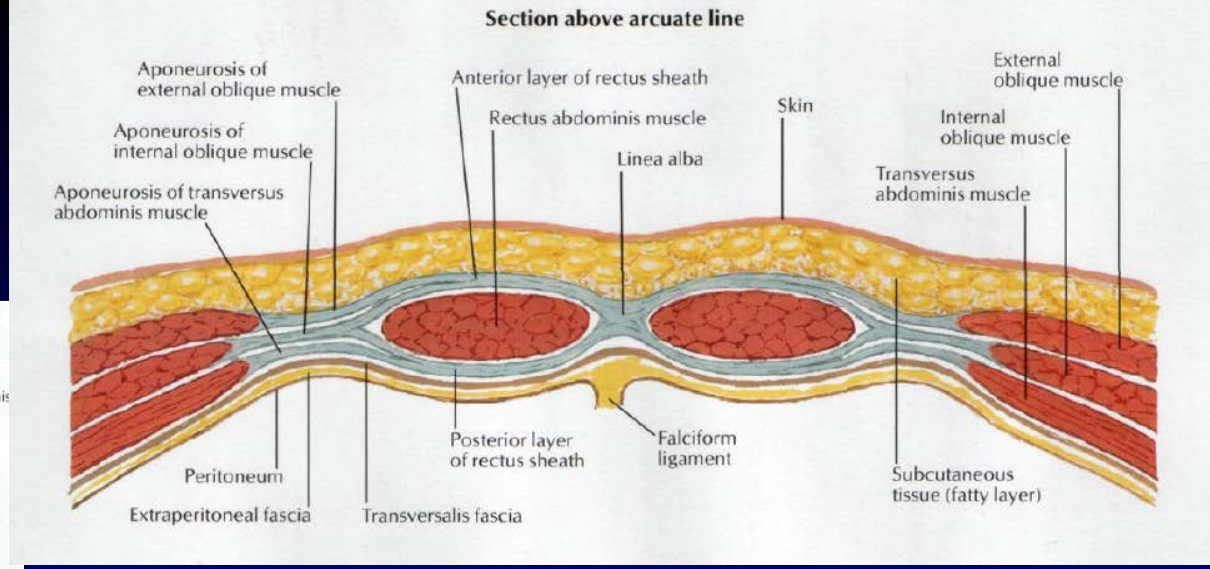
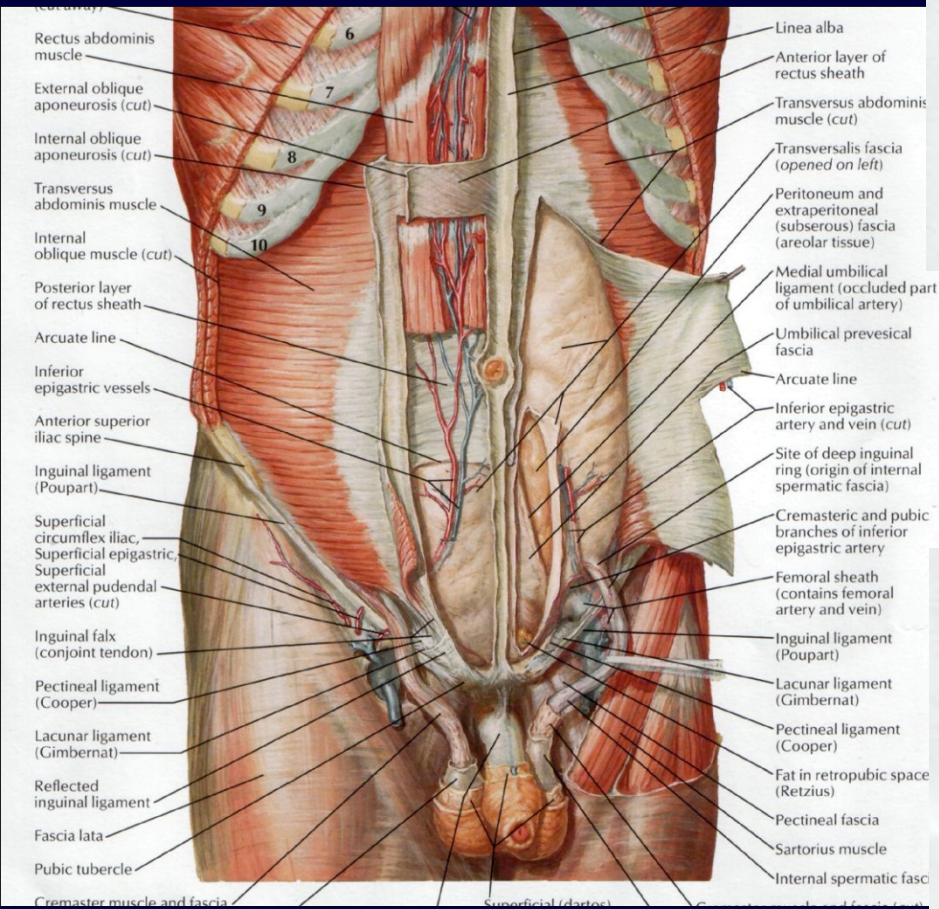
1. Defect of abdominal wall
2. Hernia sac
3. Contents of the hernial sac (visceral organs)

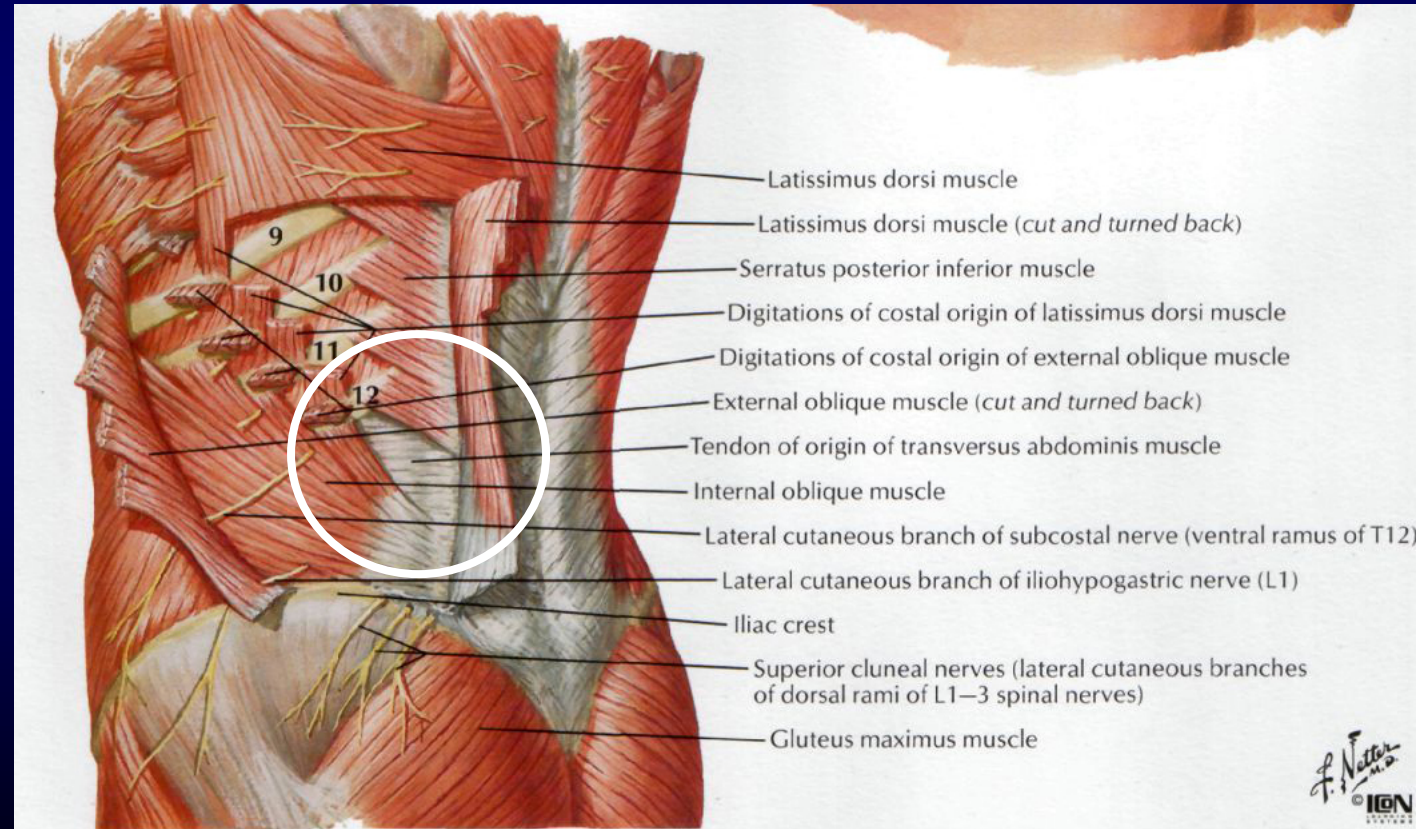
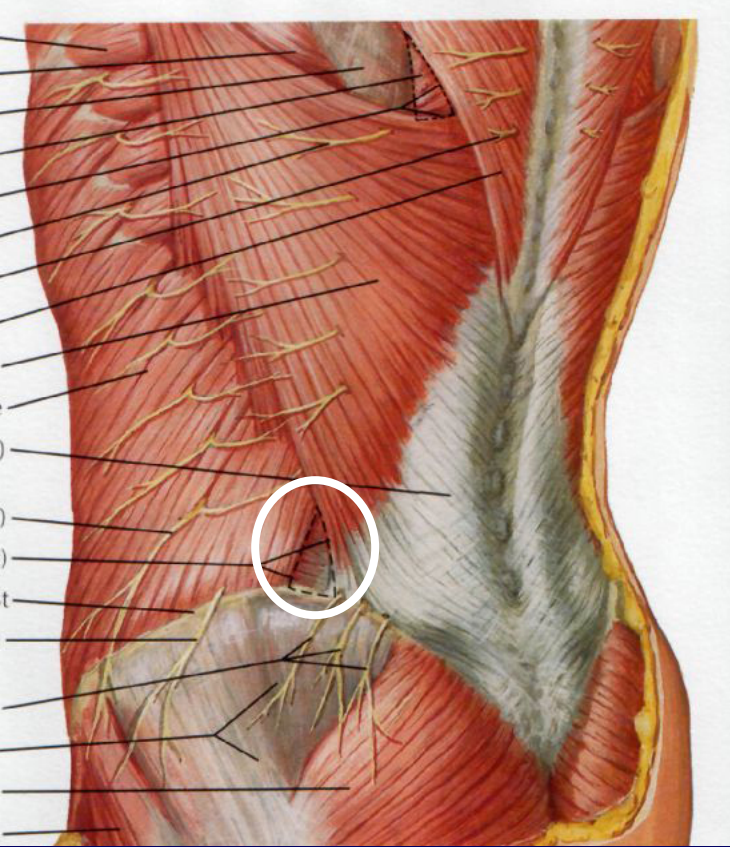


Common Types of Hernias

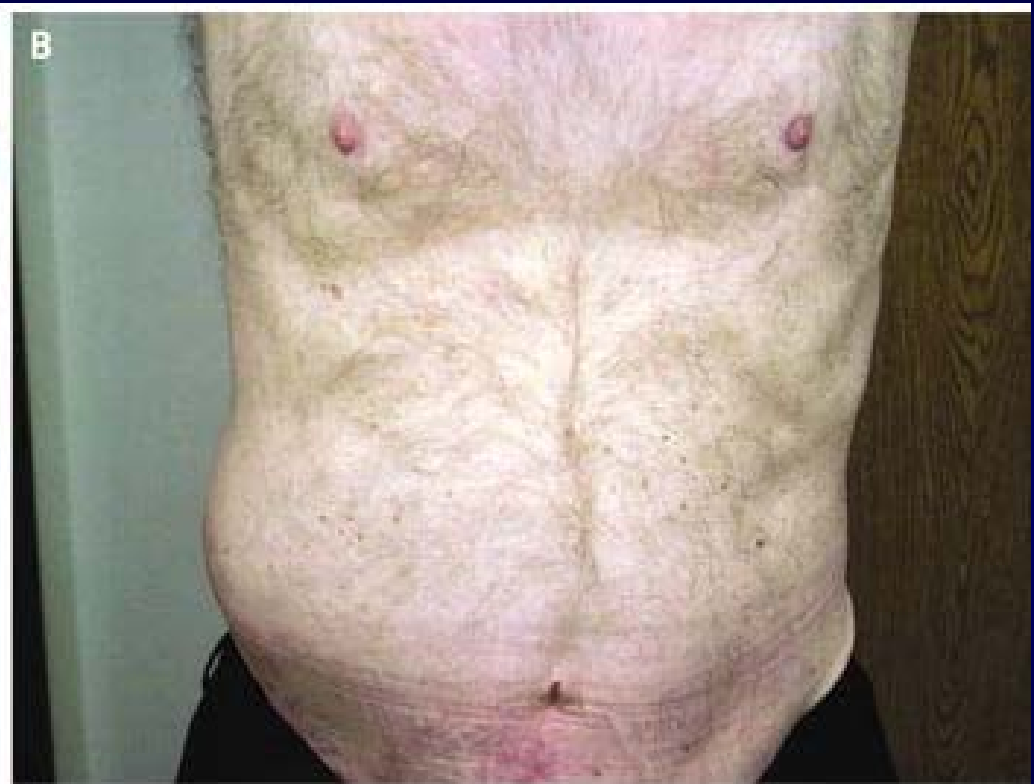
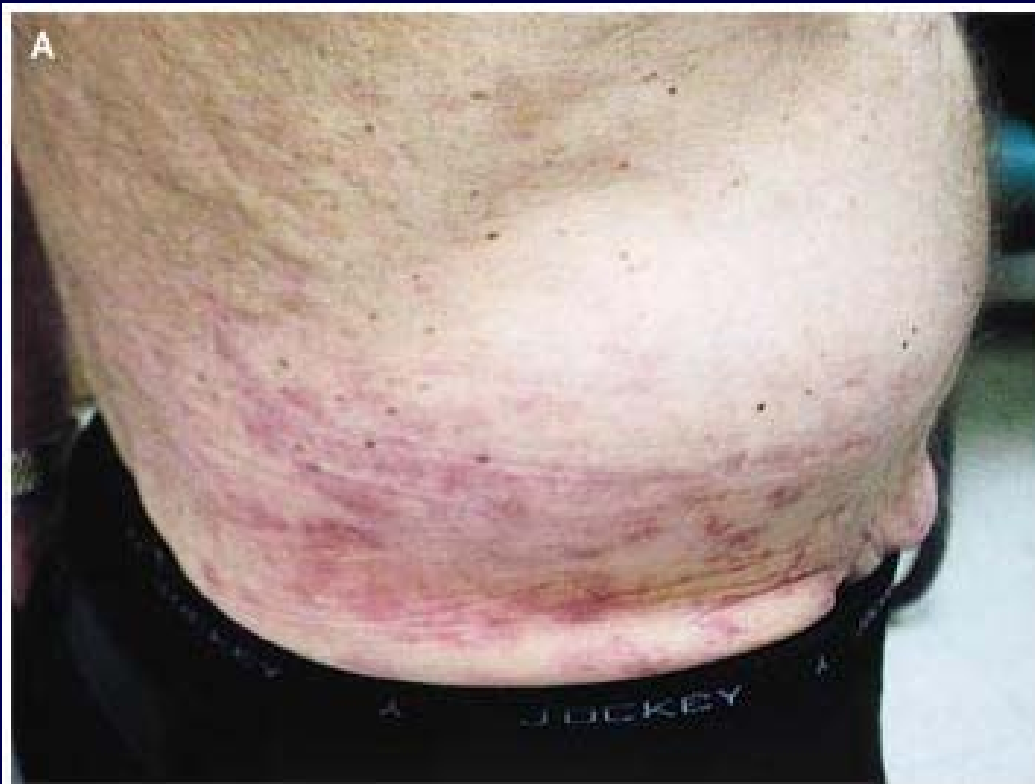
- | | |
|--|---------------|
| 1) Epigastric | 11% |
| 2) Diastasis (not a true hernia) | |
| 3) Supra-umbilical hernia | |
| 4) Umbilical hernia | 4% |
| 5) Incisional hernia | 8-10% |
| 6) Scar (previous inguinal hernia operation) | |
| 7) Recurrent inguinal hernia | |
| 8) Spigelian hernia (very rare) | |
| 9) Femoral hernia | 8% |
| 10) Inguinal hernia | 75-90% |

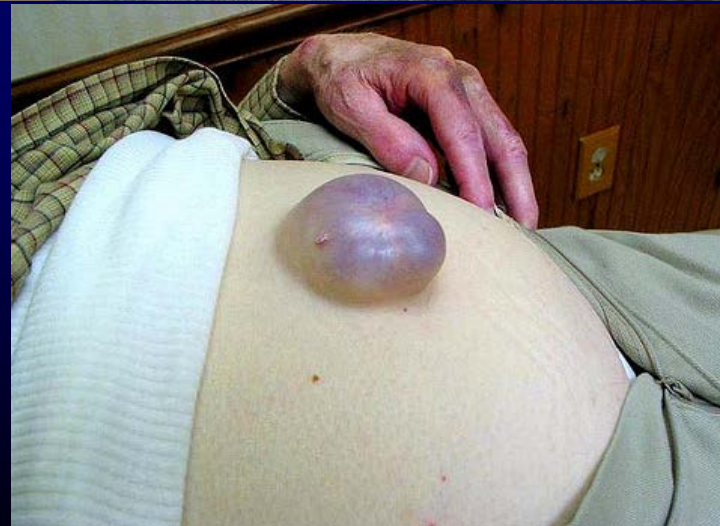
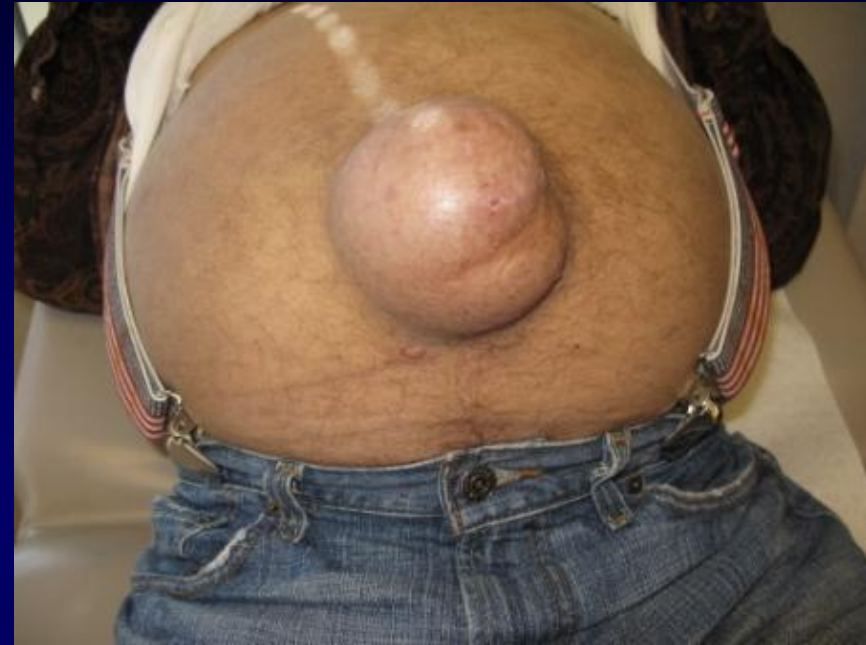
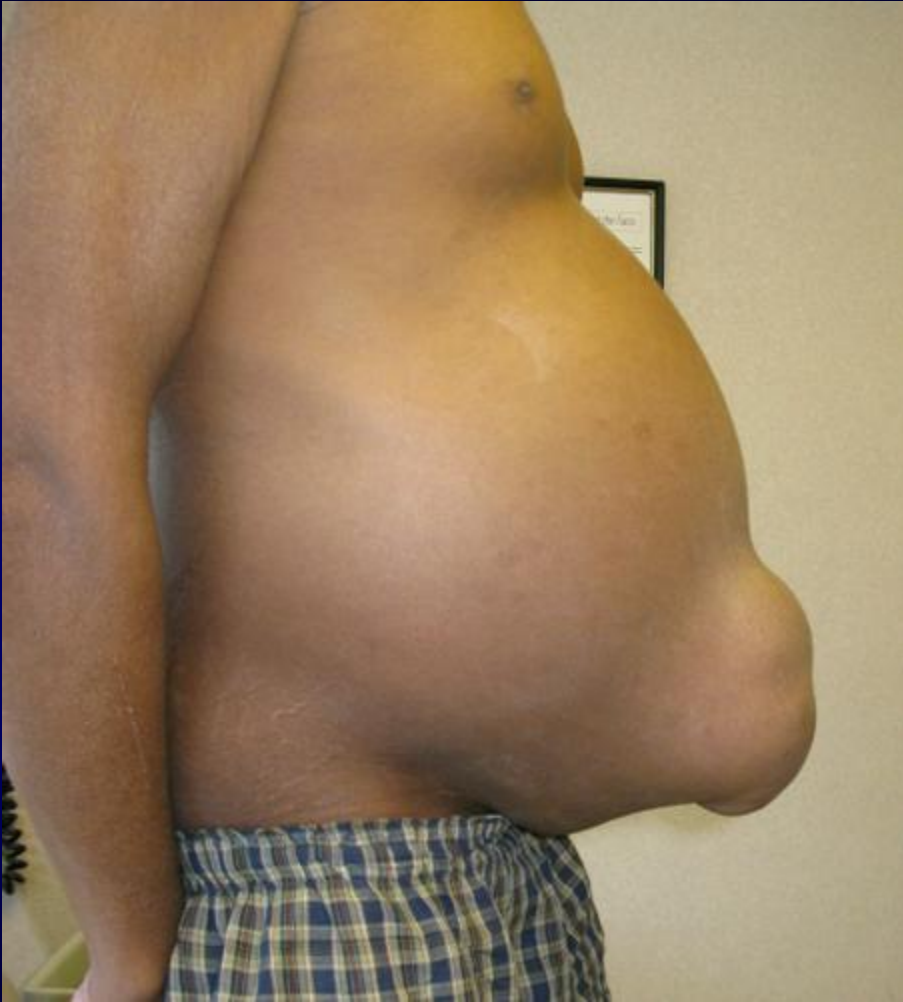

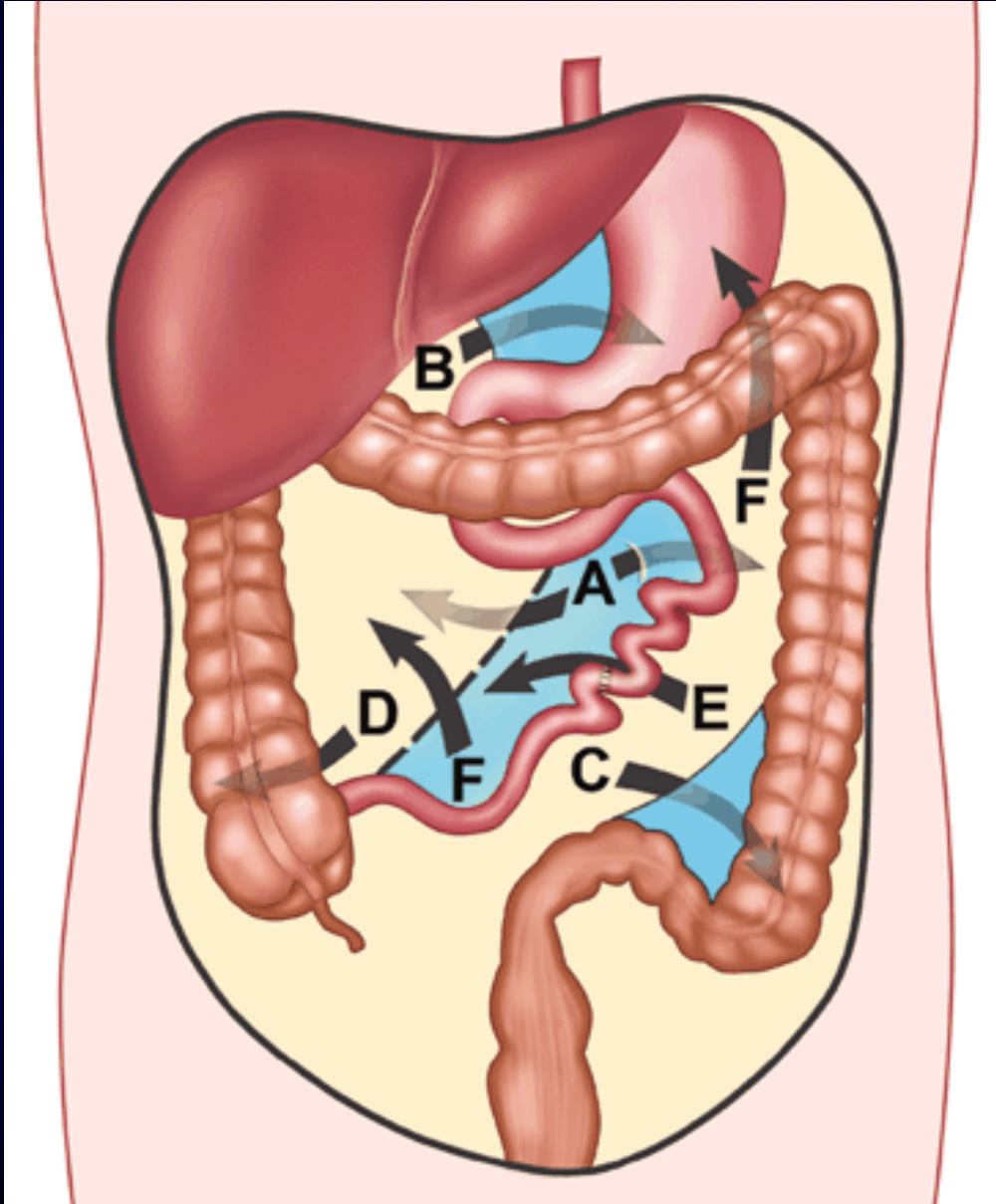
Abdominal Pseudohernia Due to Herpes Zoster



Umbilical Hernia in Cirrhosis



Internal Hernia

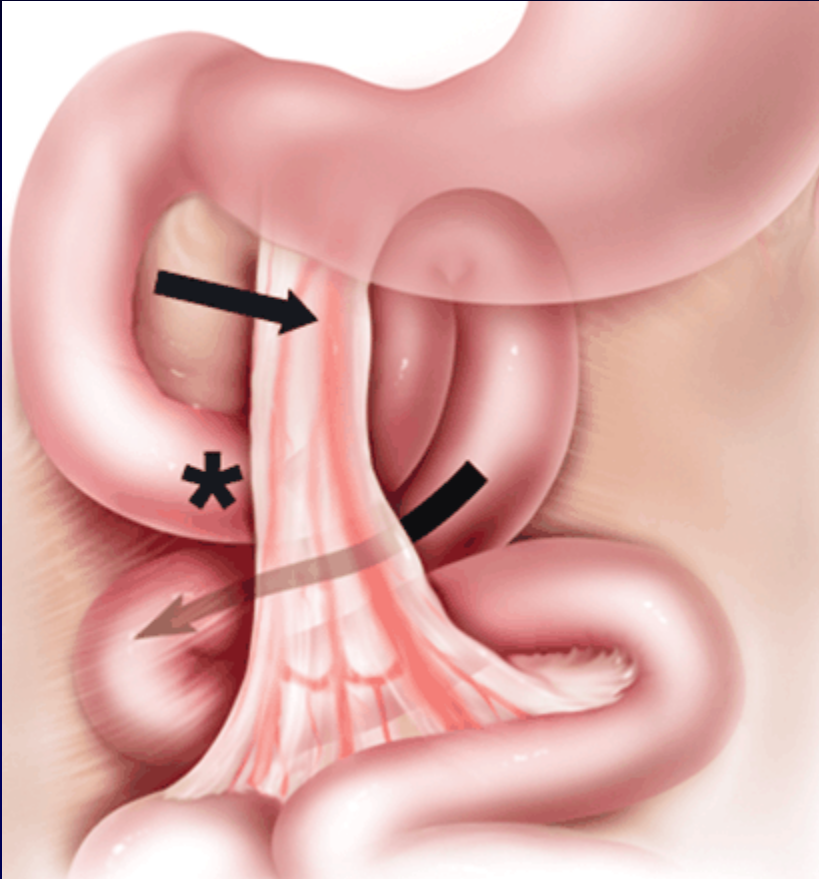


The overall incidence of internal hernias being 0.2-0.9%.

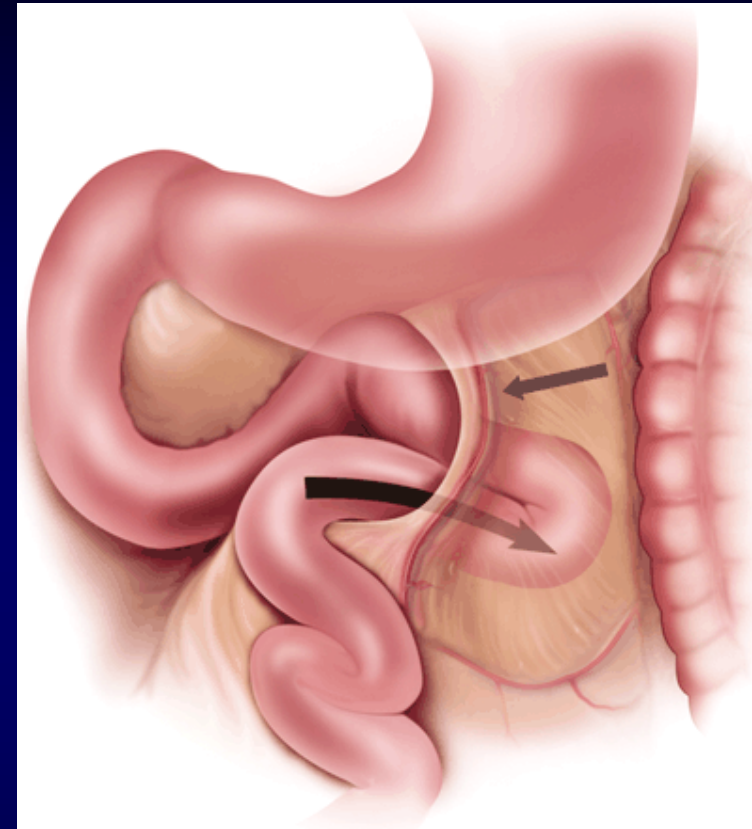
Various types of internal hernias:

A – paraduodenal	53%
B - foramen of Winslow	8%
C – intersigmoid	6%
D – pericecal	13%
E – transmesenteric and transmesocolic	8%
F – retroanastomotic	5%

Paraduodenal Hernia

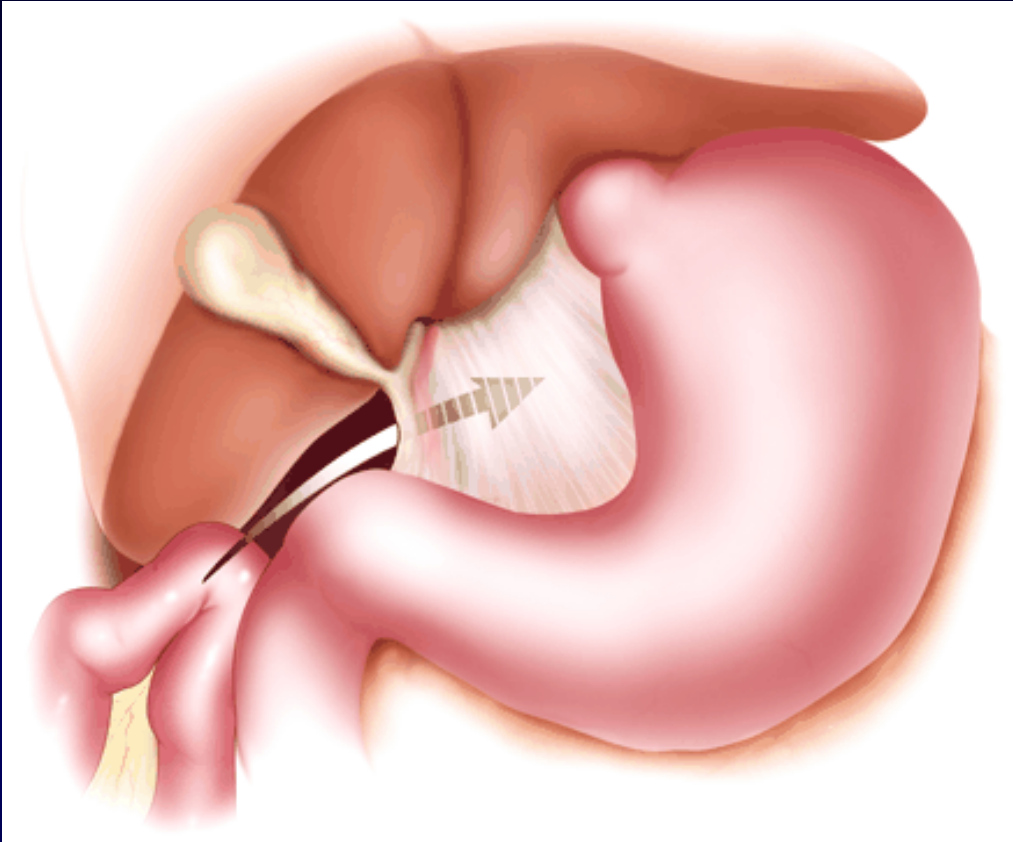


Right paraduodenal hernia shows loop of small bowel prolapsing (*curved arrow*) **through Waldeyer's fossa**, behind superior mesenteric artery (*straight arrow*) and inferior to third portion of duodenum (*asterisk*).

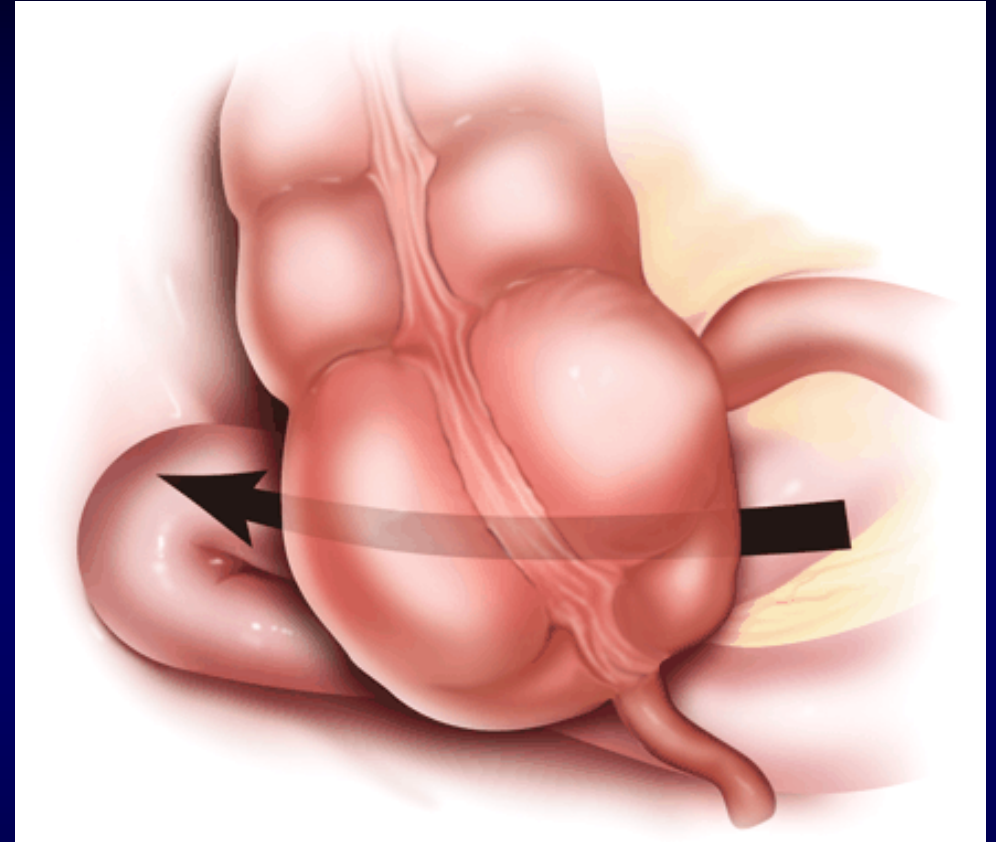


Left paraduodenal hernia depicts loop of small bowel prolapsing (*curved arrow*) **through Landzert's fossa**, located behind inferior mesenteric vein and ascending left colic artery (*straight arrow*). Herniated bowel loops are therefore located lateral to fourth portion of duodenum.

Internal Hernia

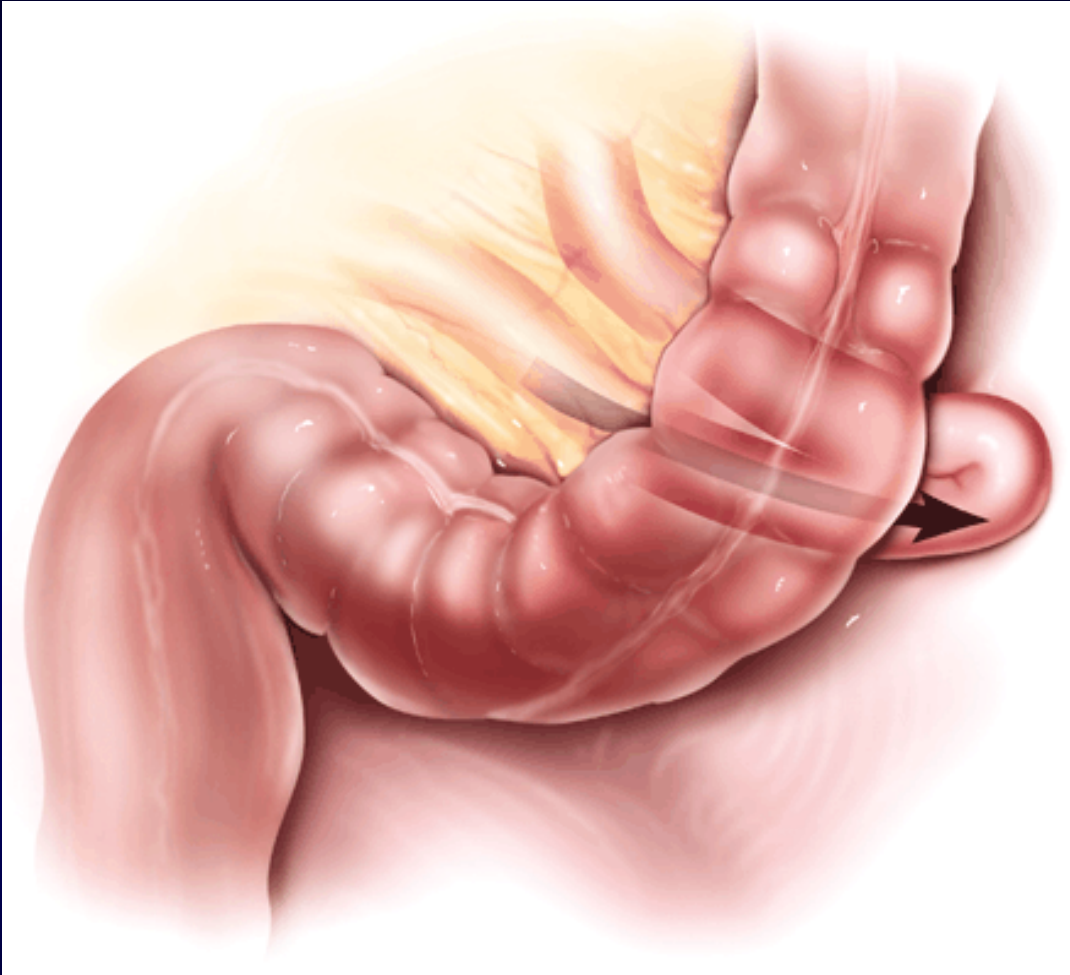


Graphic illustration of **foramen of Winslow hernia** shows bowel about to prolapse (*arrow*) into lesser sac, behind hepatoduodenal ligament, the free edge of the lesser omentum.

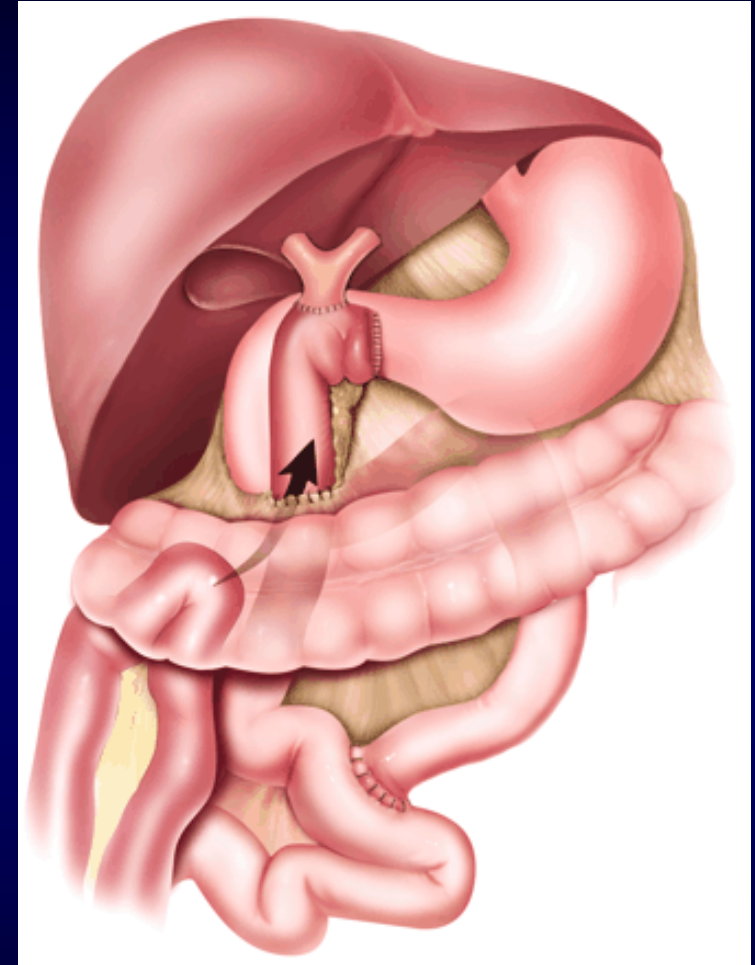


Pericecal hernia shows loop of ileum prolapsing (*arrow*) through cecal mesenteric defect, behind and lateral to cecum, into right paracolic gutter.

Internal Hernia

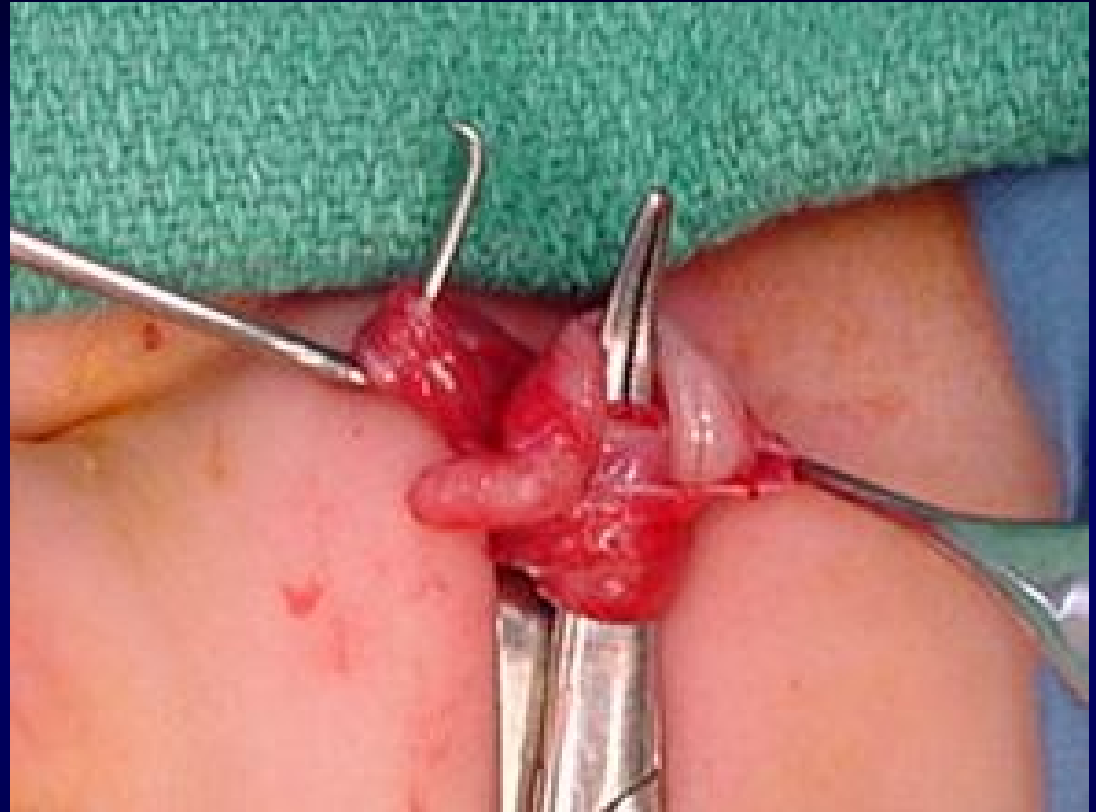
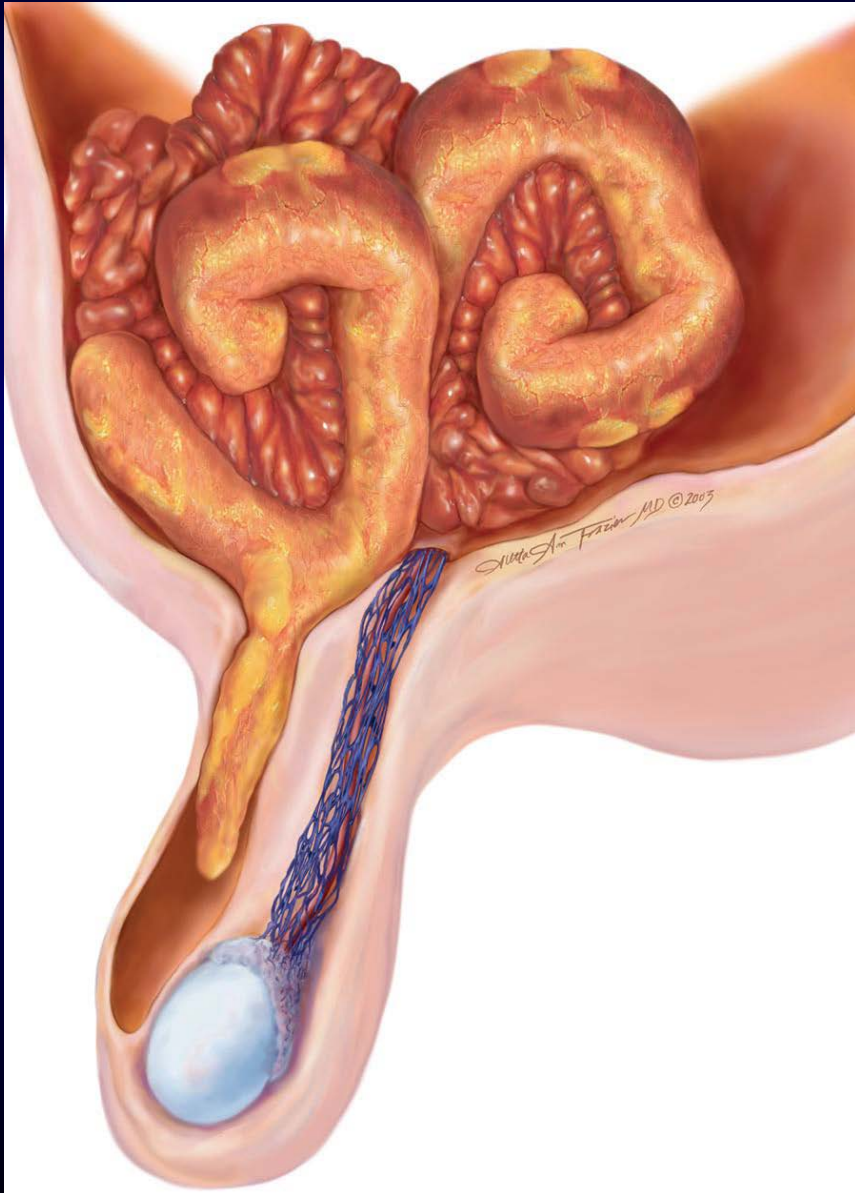


Intersigmoid hernia shows bowel protruding (*arrow*) through defect in sigmoid mesocolon to lie posterolateral to sigmoid colon itself.



Retrocolic Roux-en-Y procedure, with loop of small bowel about to herniate through transverse mesocolon (*arrow*) at surgically created defect, in keeping with transmesocolic internal hernia.

Littre Hernia



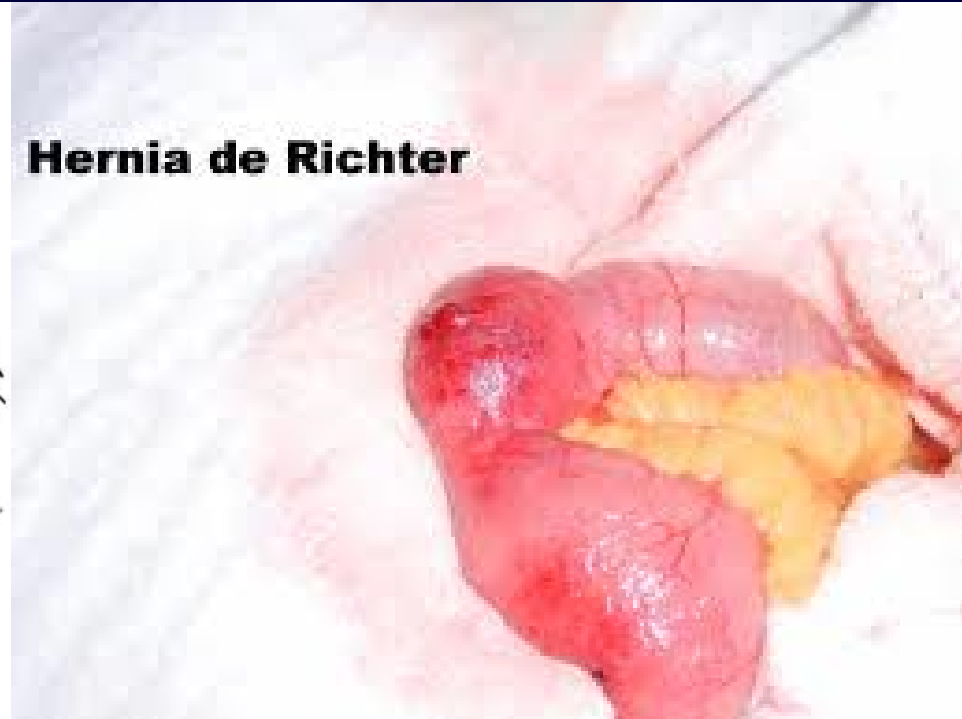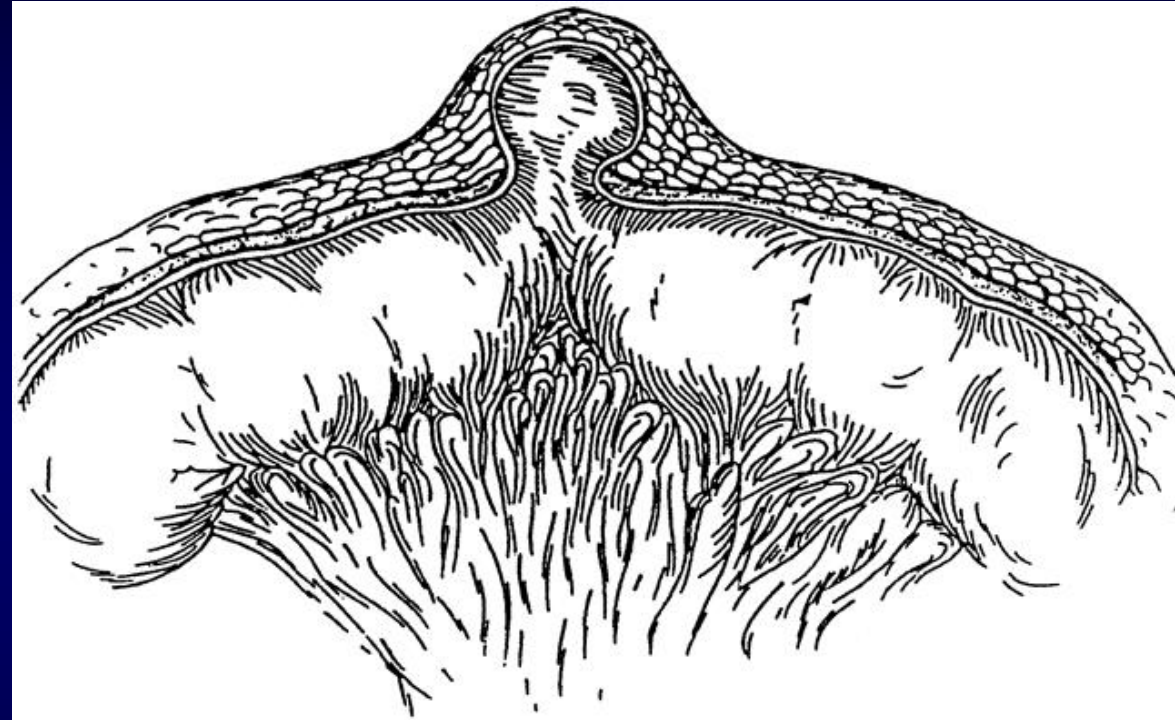
a hernia involving a Meckel's diverticulum

It is named after the French anatomist

Alexis Littre (1658–1726)

Richter's hernia

only the antimesenteric wall of the bowel has herniated without compromising the entire lumen (also called parietal hernia)

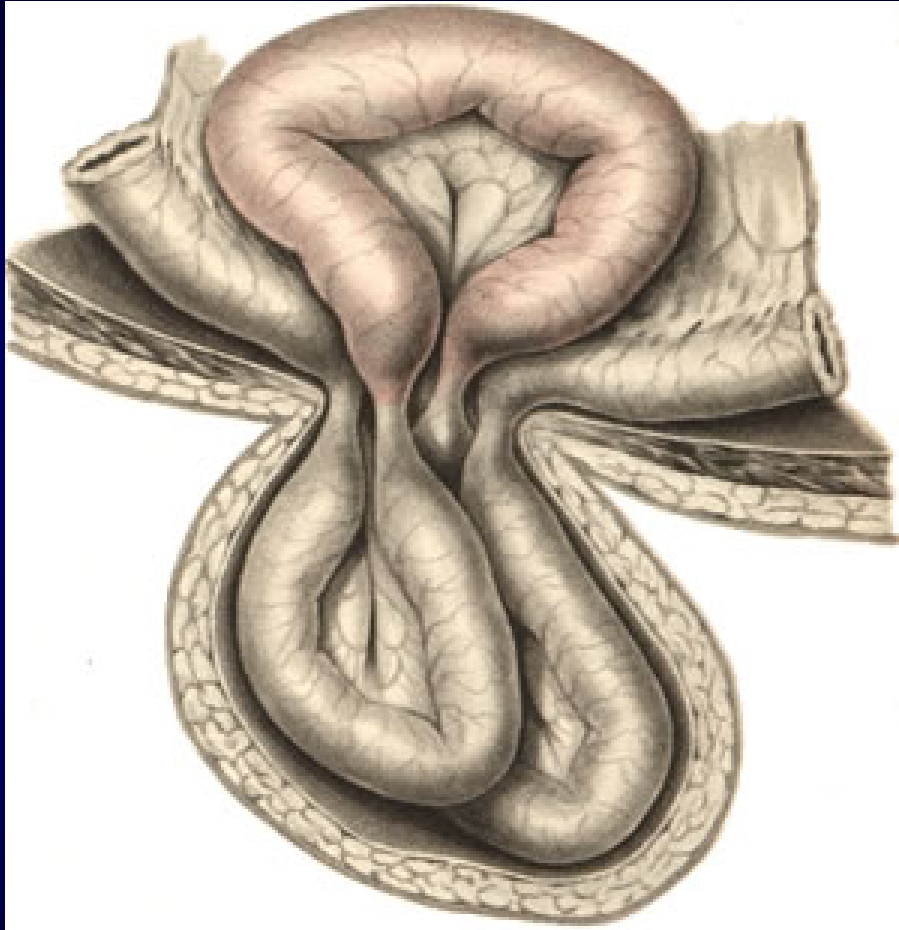


Hernia de Richter

The earliest known reported case of *Richter's hernia* occurred in 1598 and was described by **Fabricius Hildanus**. The first scientific description of this particular hernia was given by **August Gottlob Richter** in 1778, who presented it as “the small rupture.”

In 1887, **Sir Frederick Treves** gave an excellent overview on the topic and proposed the title “*Richter's hernia*”.

Maydl's hernia

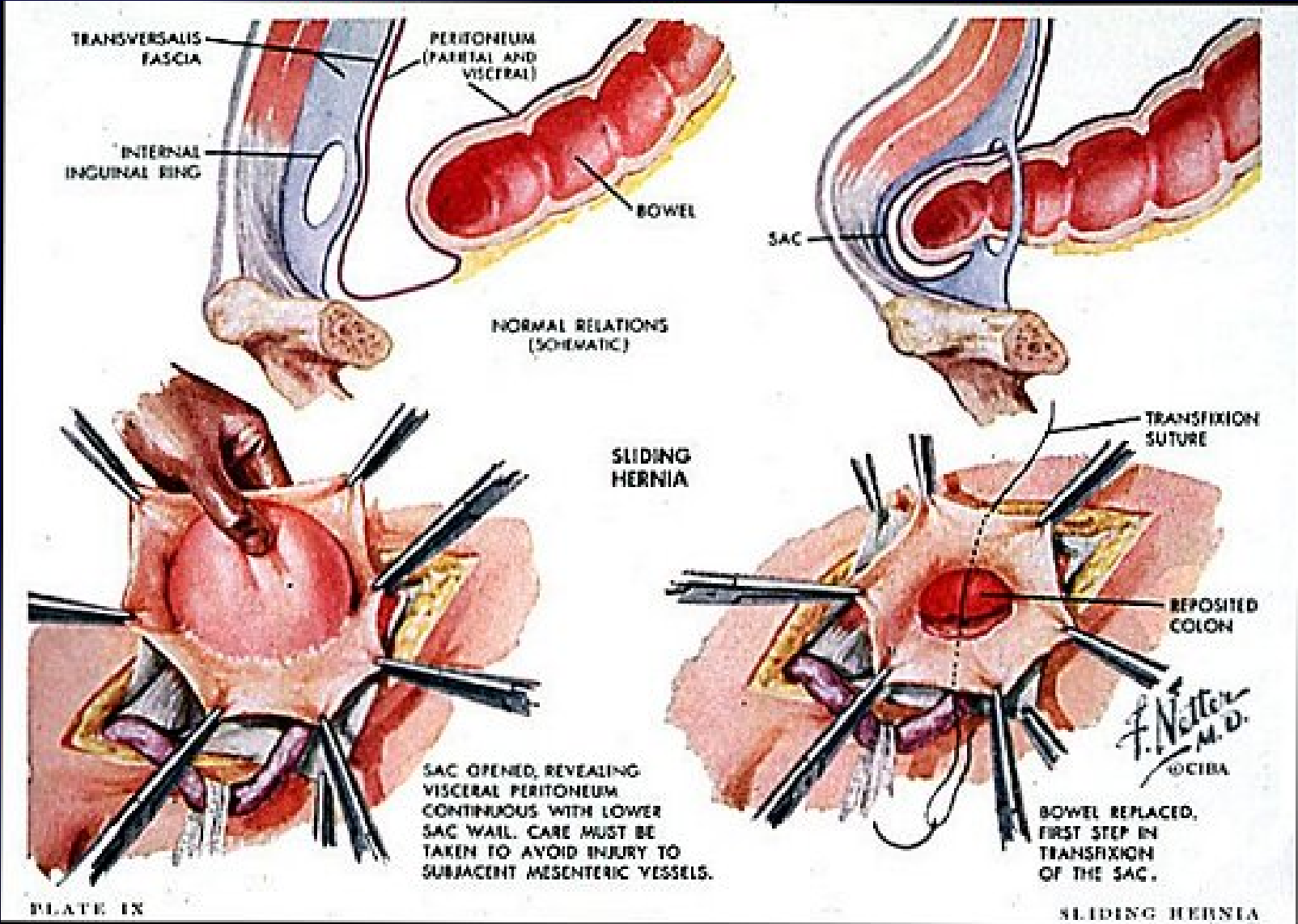


Maydl's hernia is a very rare hernia and sometimes presents as a perplexing situation which appears to be more common in strangulated sliding hernias.

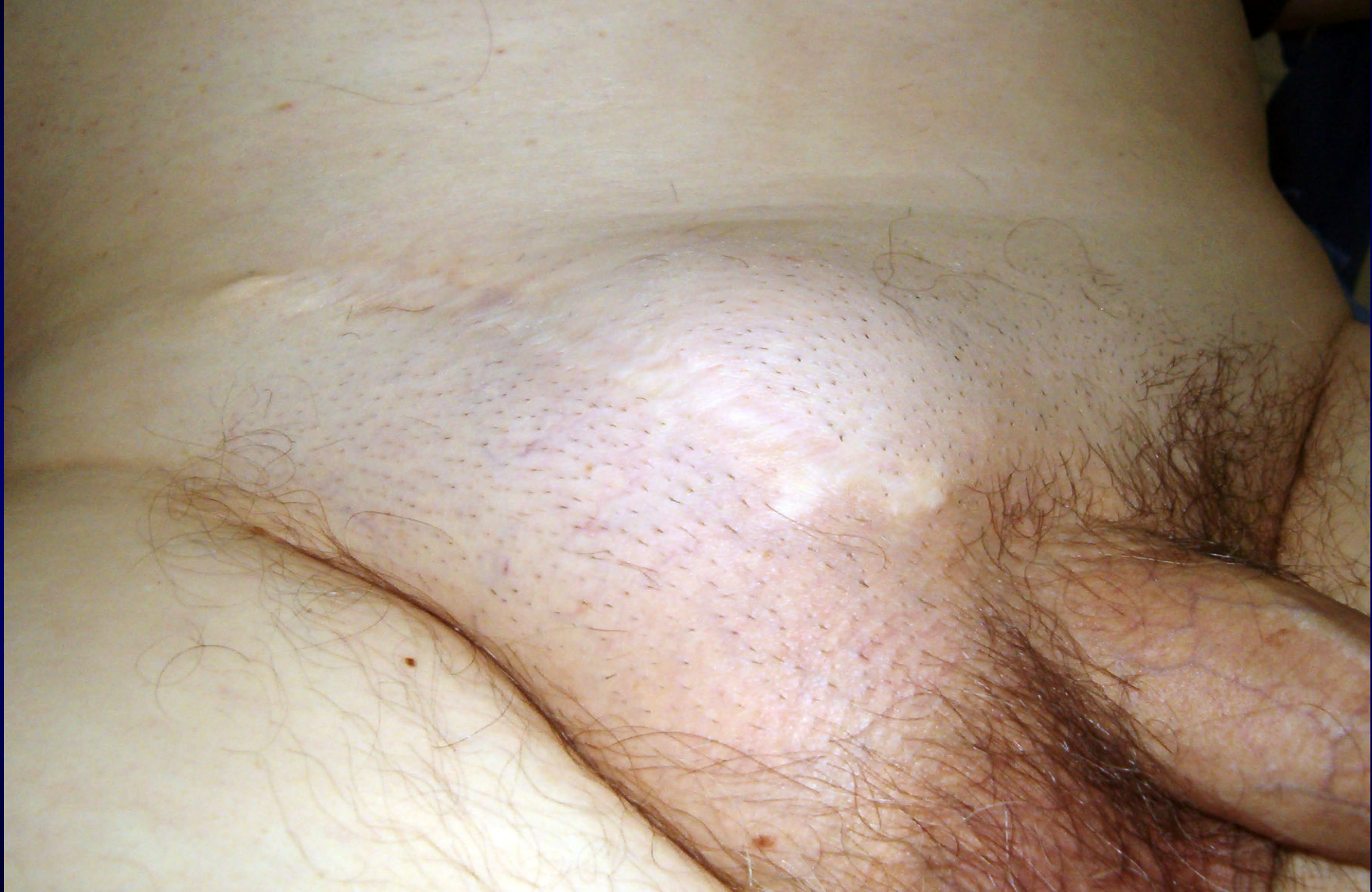The hernia contains two loops of bowel arranged like a 'W'.

The central loop of the 'W' lies free in the abdomen and is strangulated where as the two loops present in the sac are not.

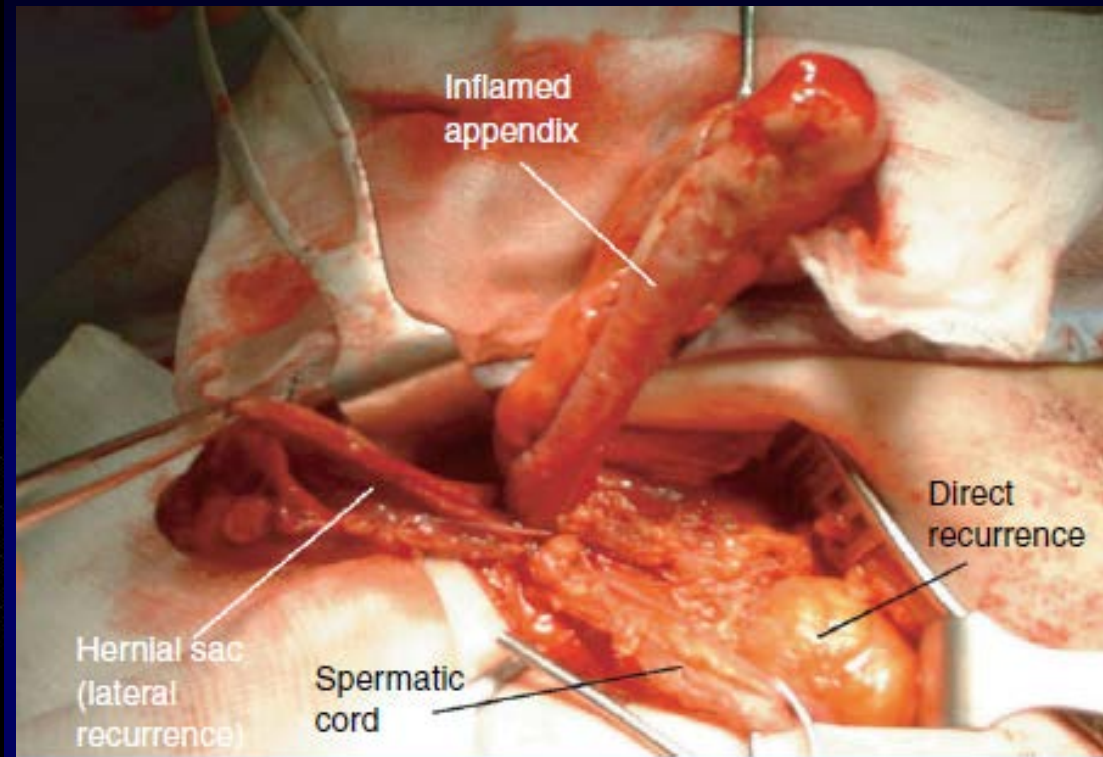
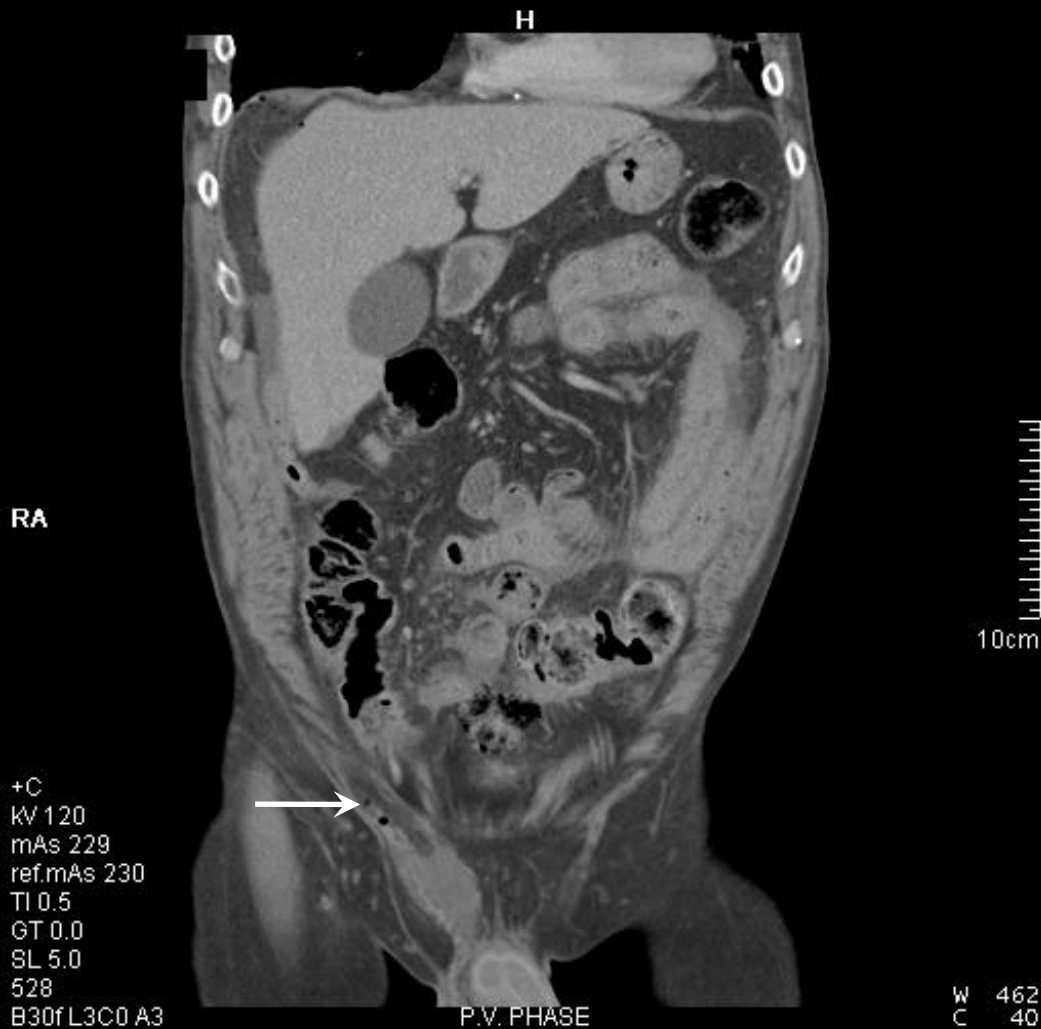Sliding Hernia



Recurrent Right-sided Strangulated Inguinal Hernia



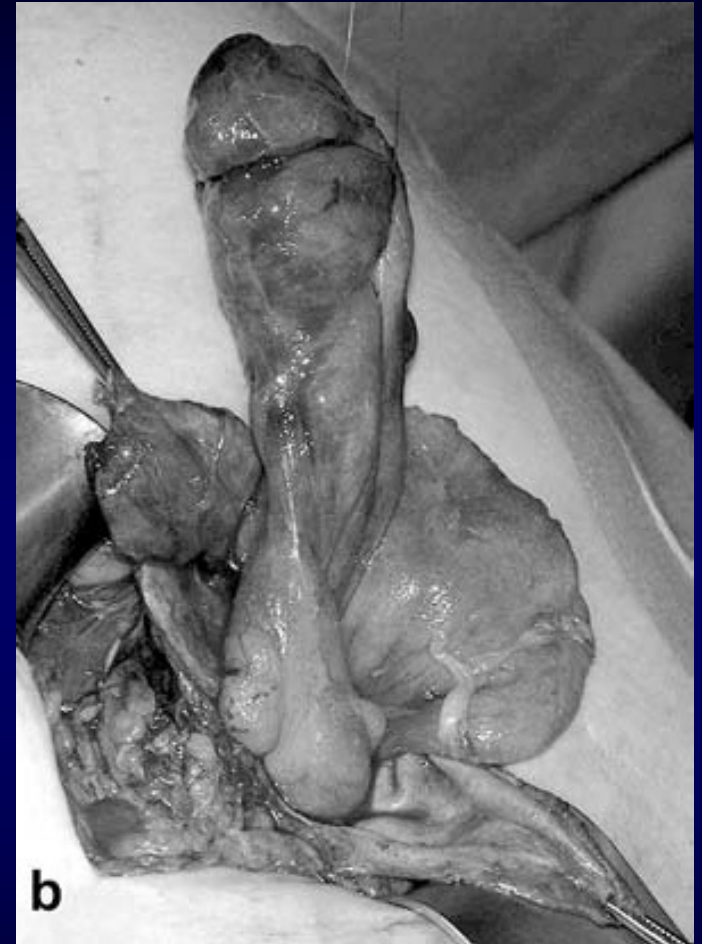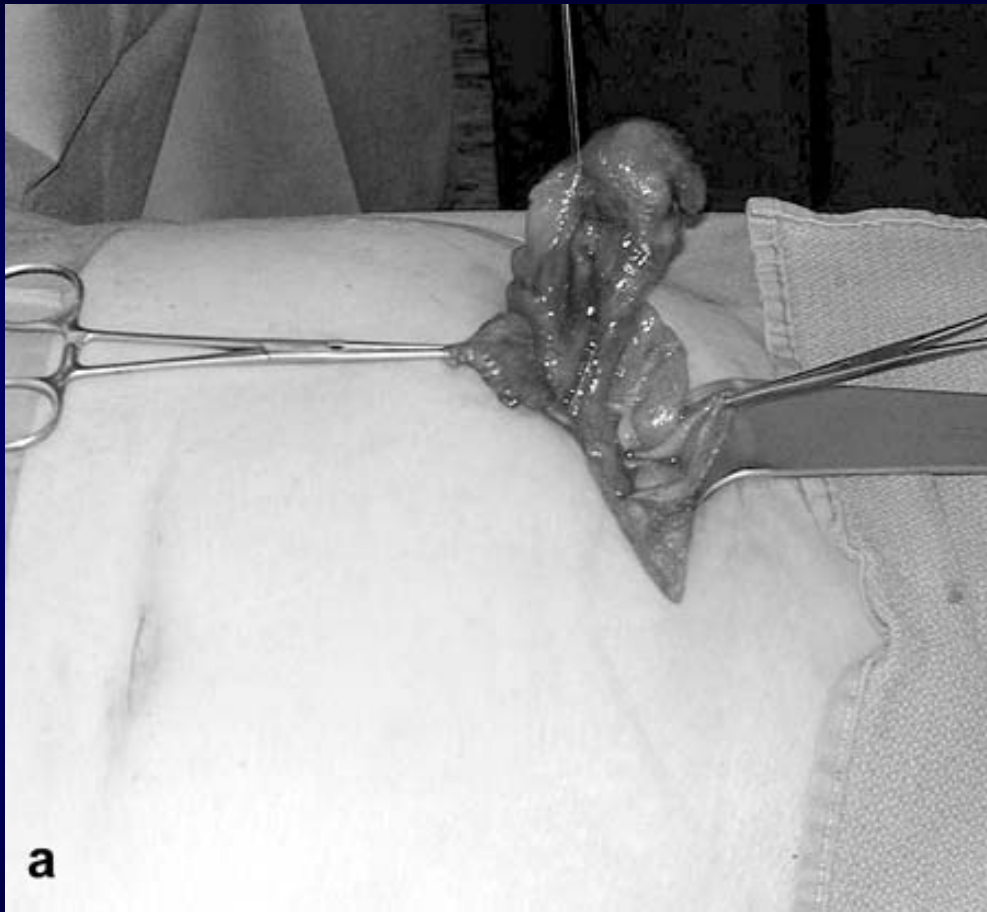Amyand's hernia (acute appendicitis in inguinal hernia)



Pathological types of Amyand's hernia

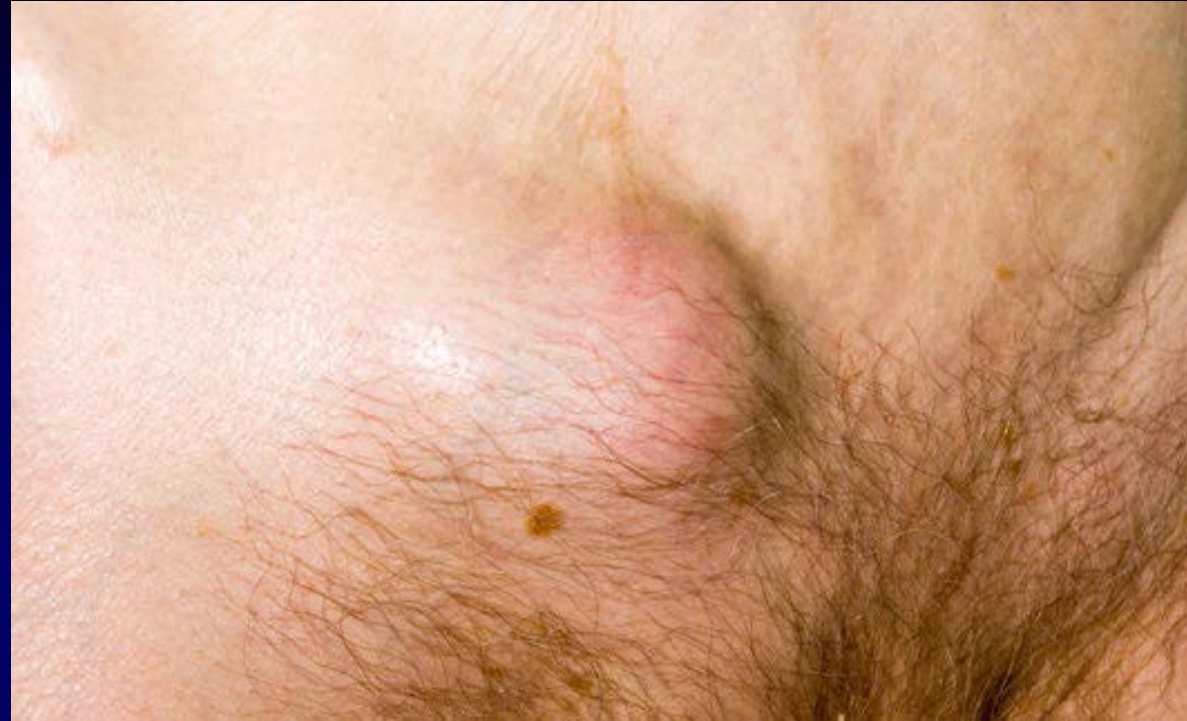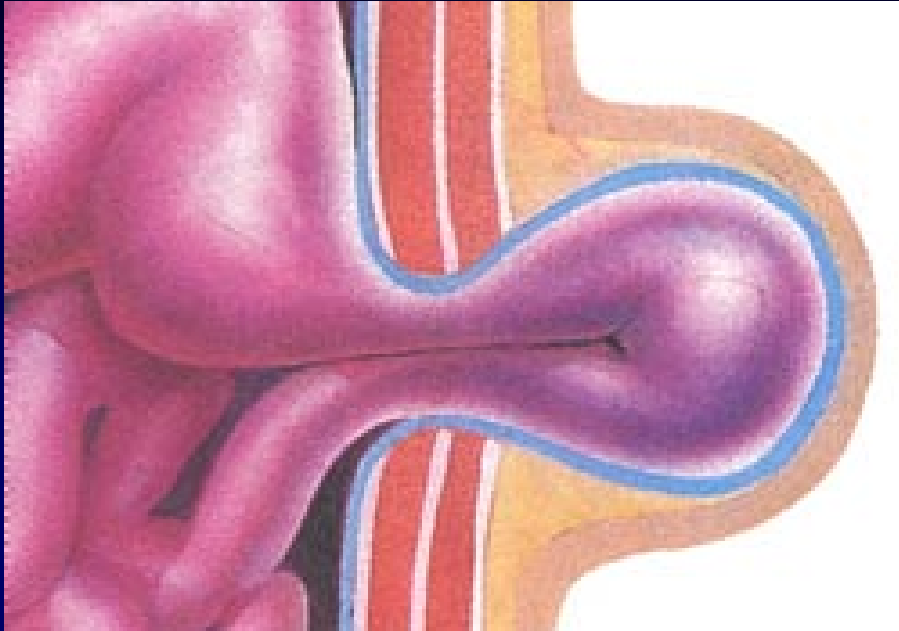
- I - normal appendix
- II - acute appendicitis localized in the sac
- III - acute appendicitis, peritonitis
- IV - acute appendicitis, other abdominal pathology

Incarcerated vermiform appendix in a left-sided inguinal hernia



A Left inguinal approach. **B** Situs. Note the appendix and parts of the coecum.

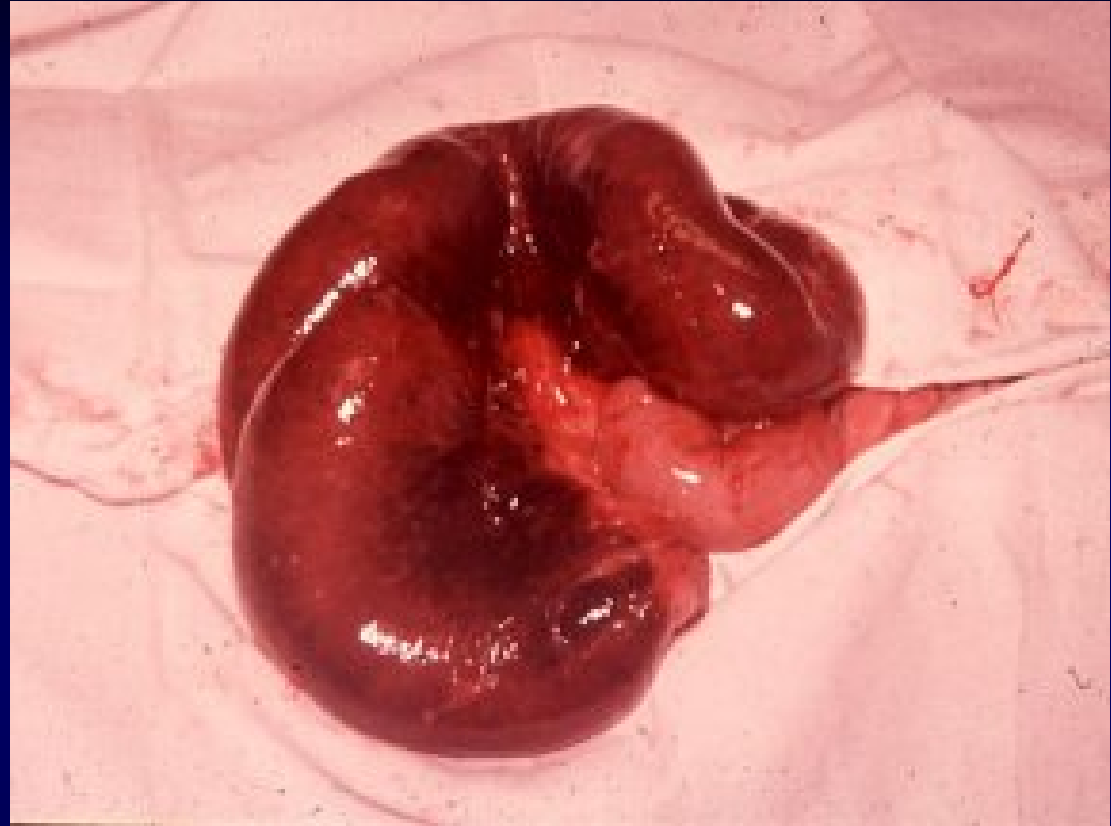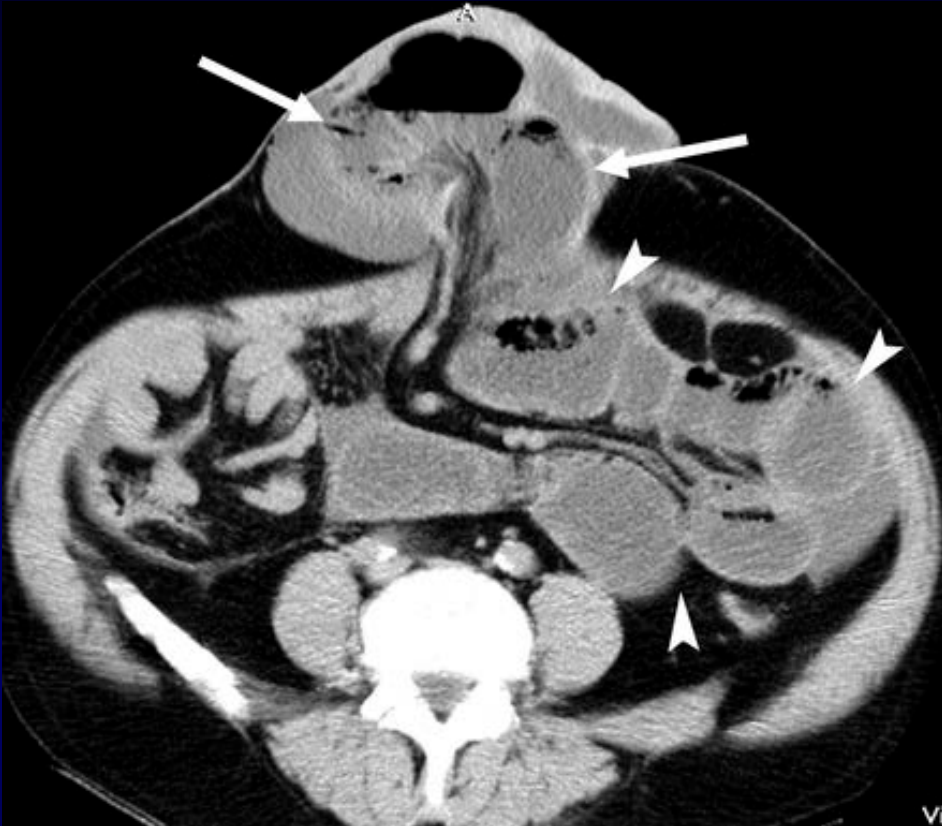
Strangulated Hernia



Two main mechanism of strangulation:

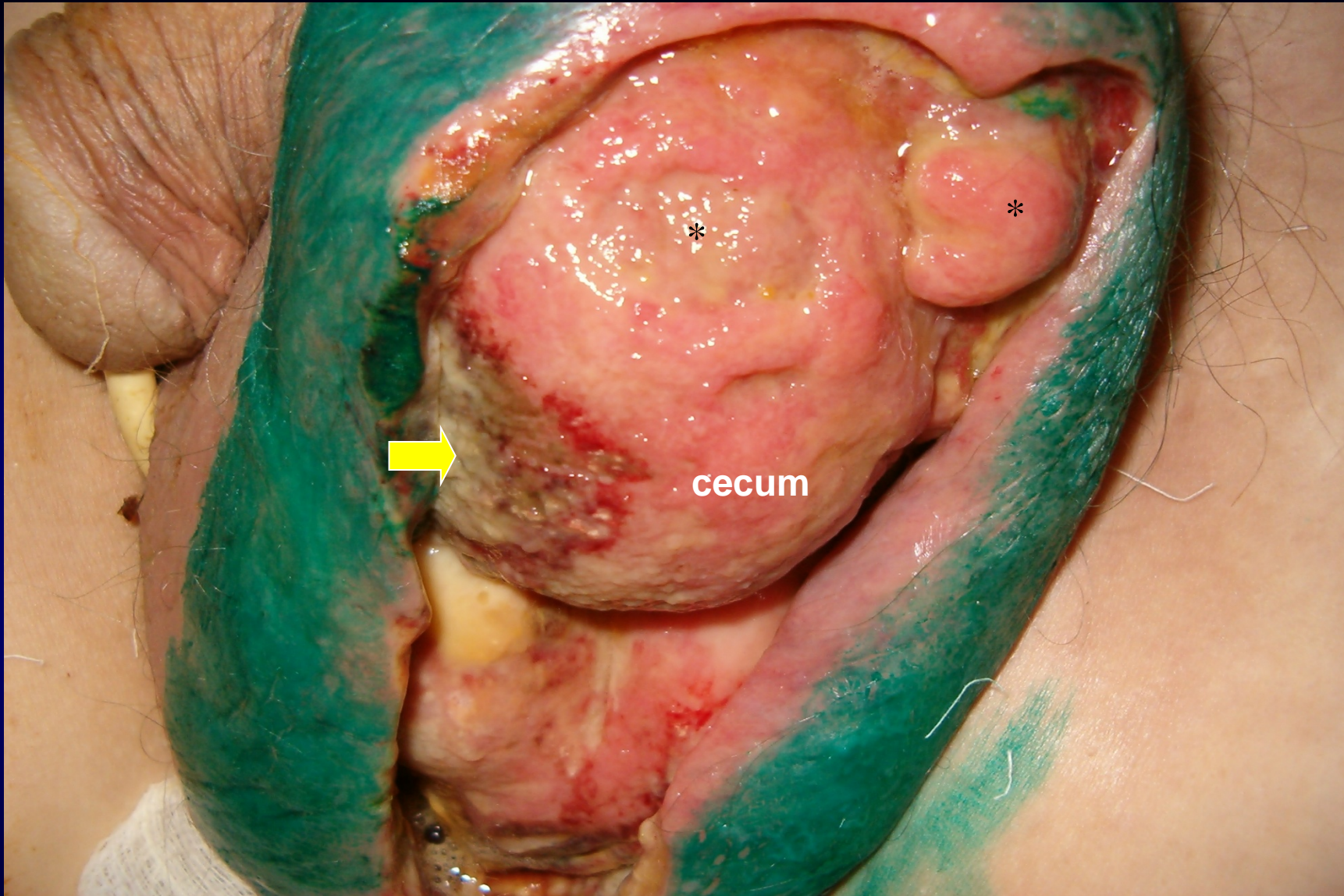
1. Elastic strangulation
2. Fecal-stasis strangulation

Strangulated Hernia

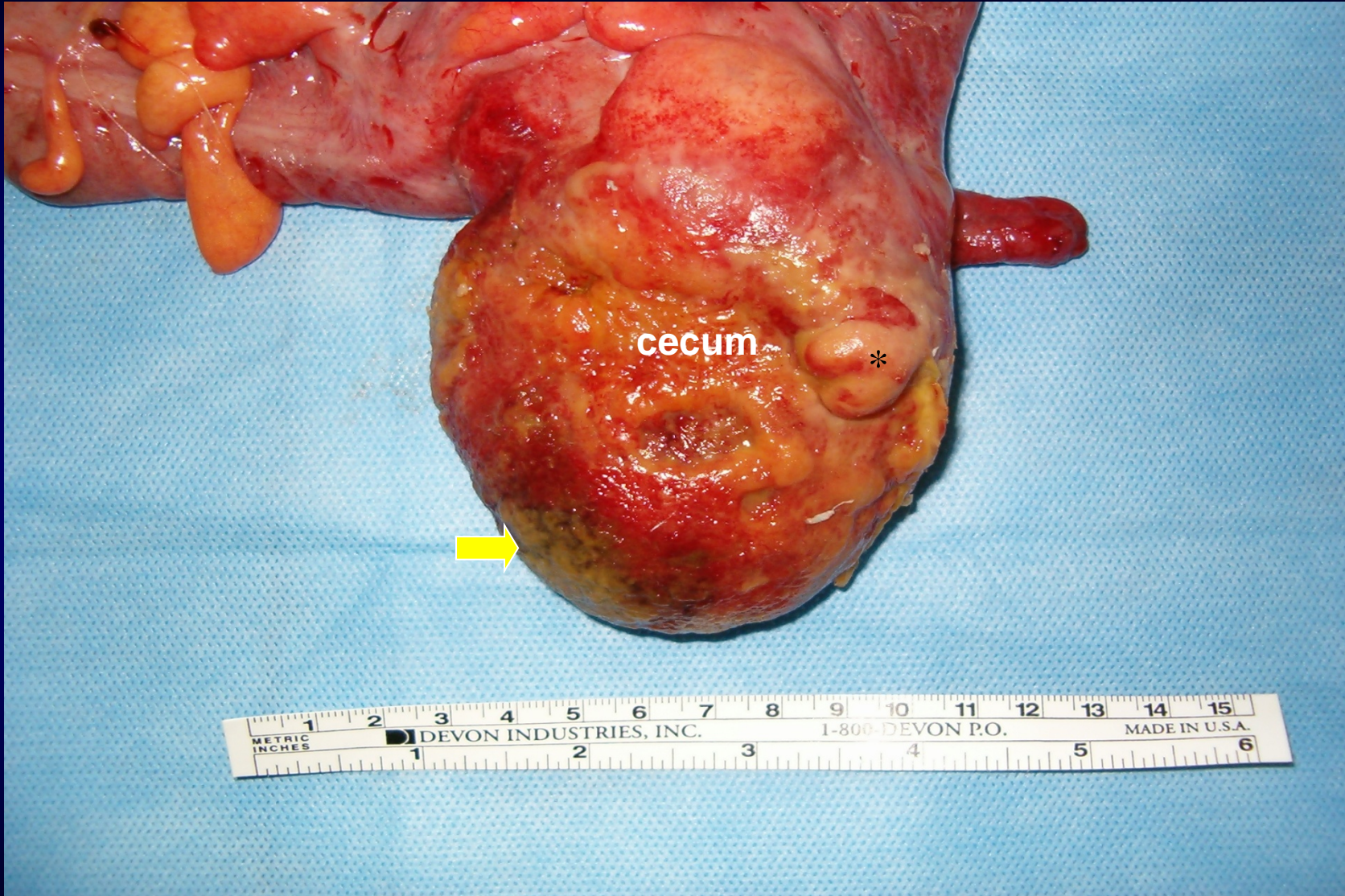


Three stages of ischaemic changes:

1. stage of congestion
2. ischaemic stage
3. gangrenous stage (with or without perforation)



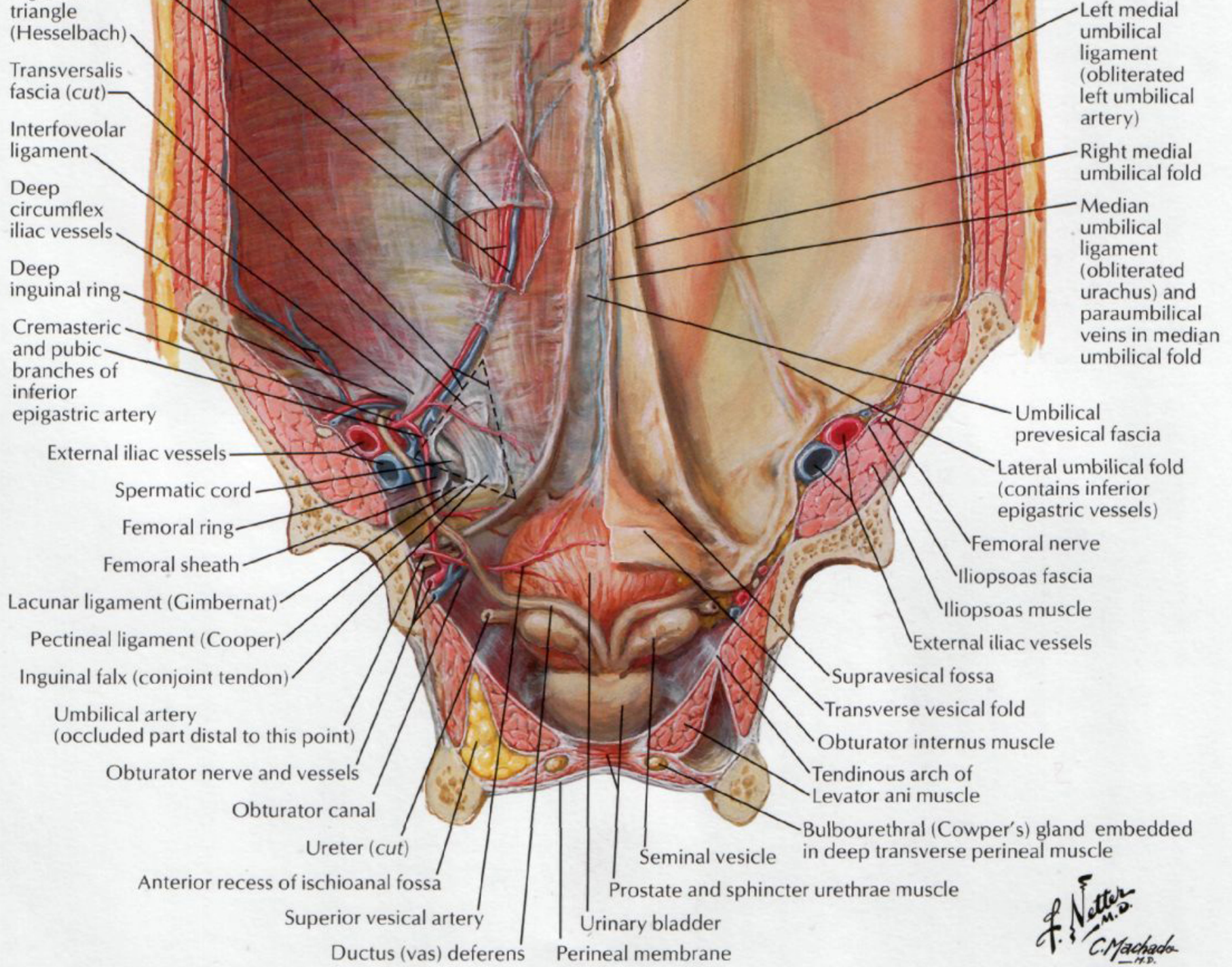
cecum



cecum

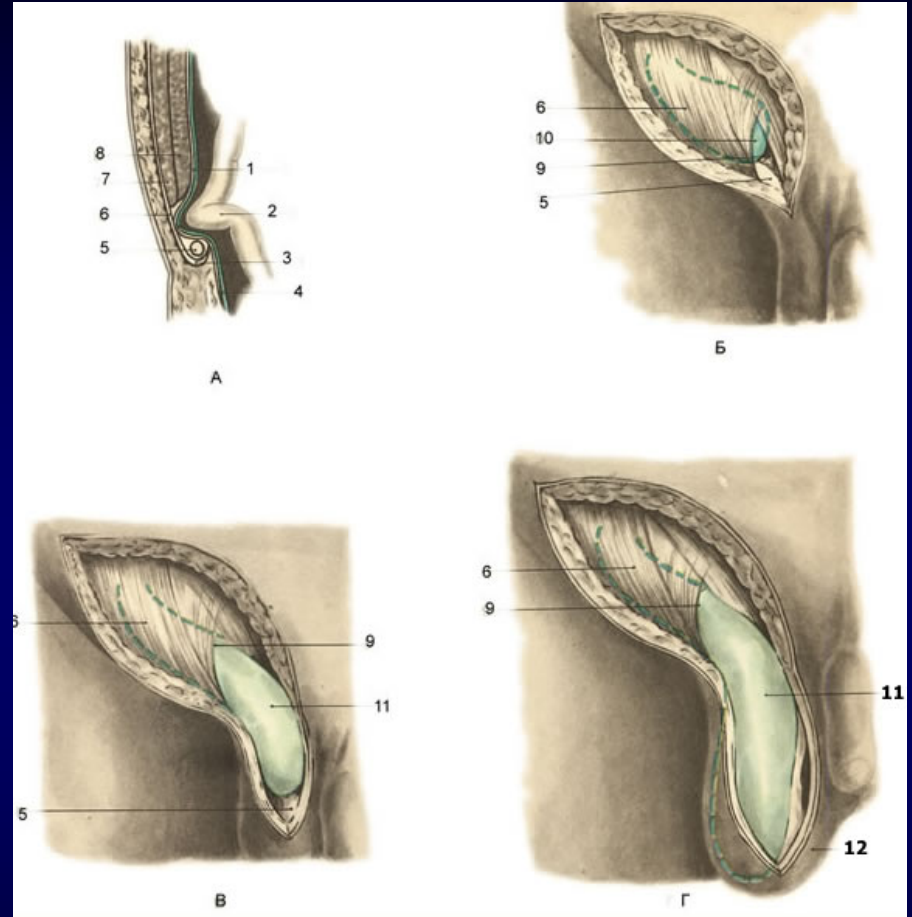
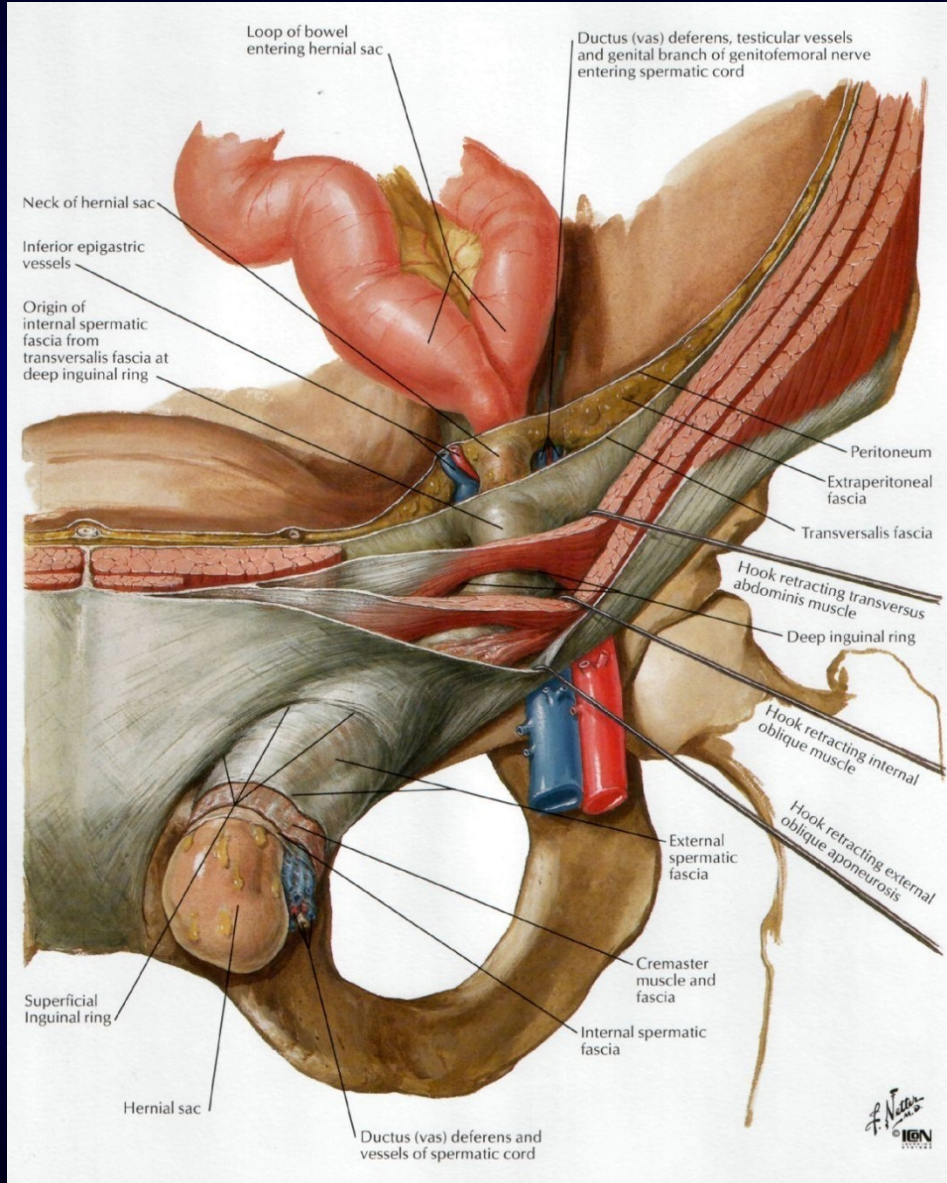
*

METRIC INCHES 1 2 3 4 5 6 7 8 9 10 11 12 13 14 15
DEVON INDUSTRIES, INC. 1-800-DEVON P.O. MADE IN U.S.A.
1 2 3 4 5 6

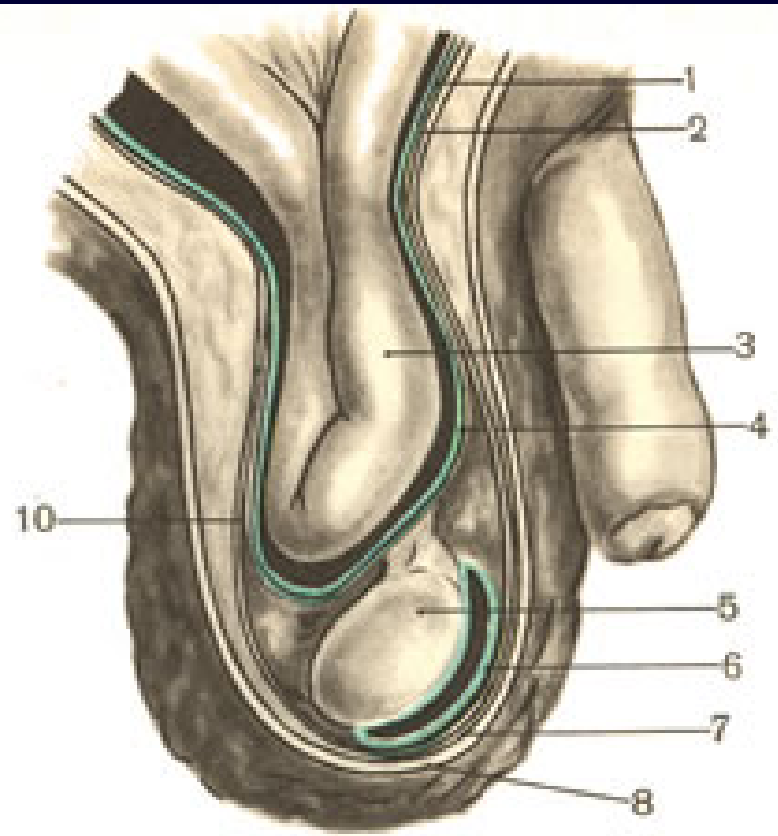
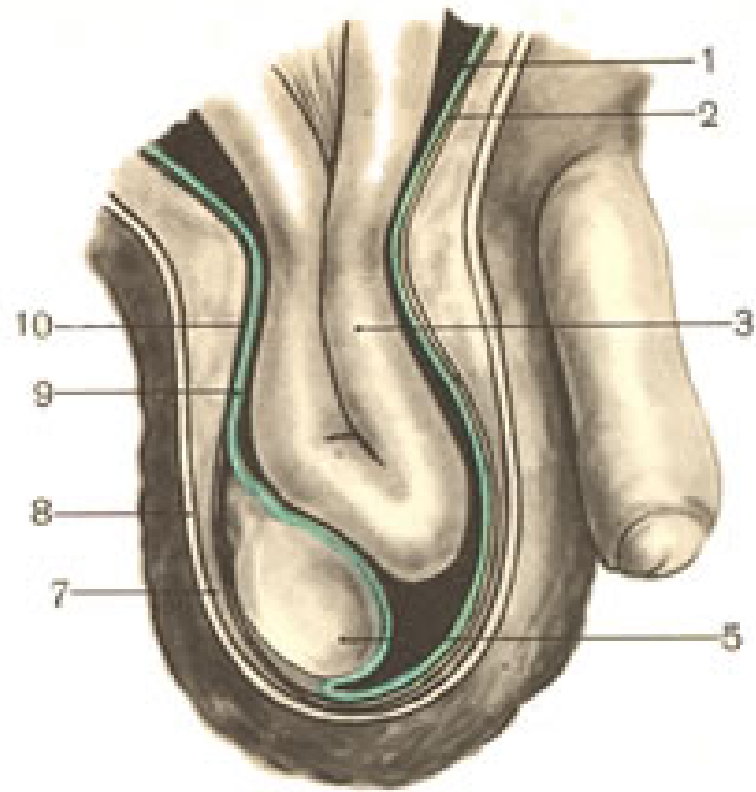


F. Netter M.D.
C. Machado M.D.
 © 1981

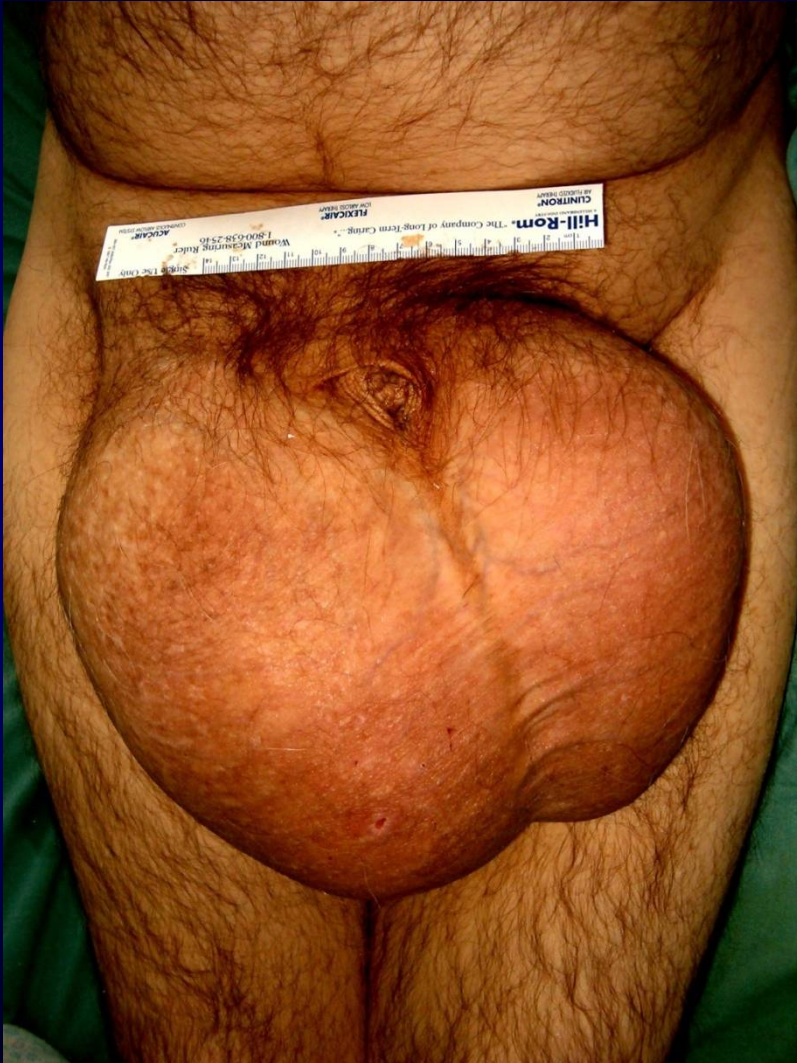Inguinal Hernia



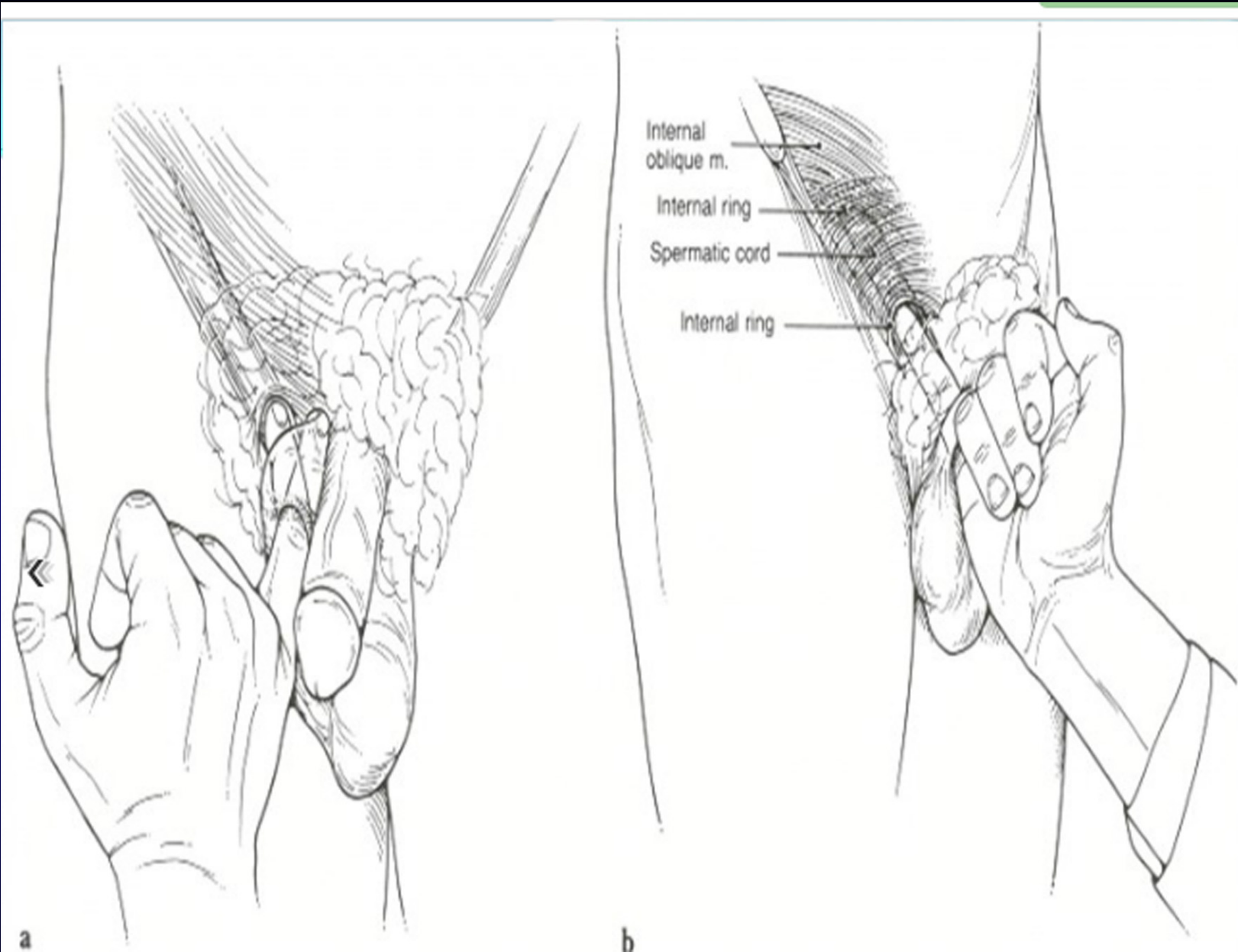
- Prehernial stage
- Intracanal hernia
- Completed hernia
- Inguino-scrotal hernia



Inguinal Hernia



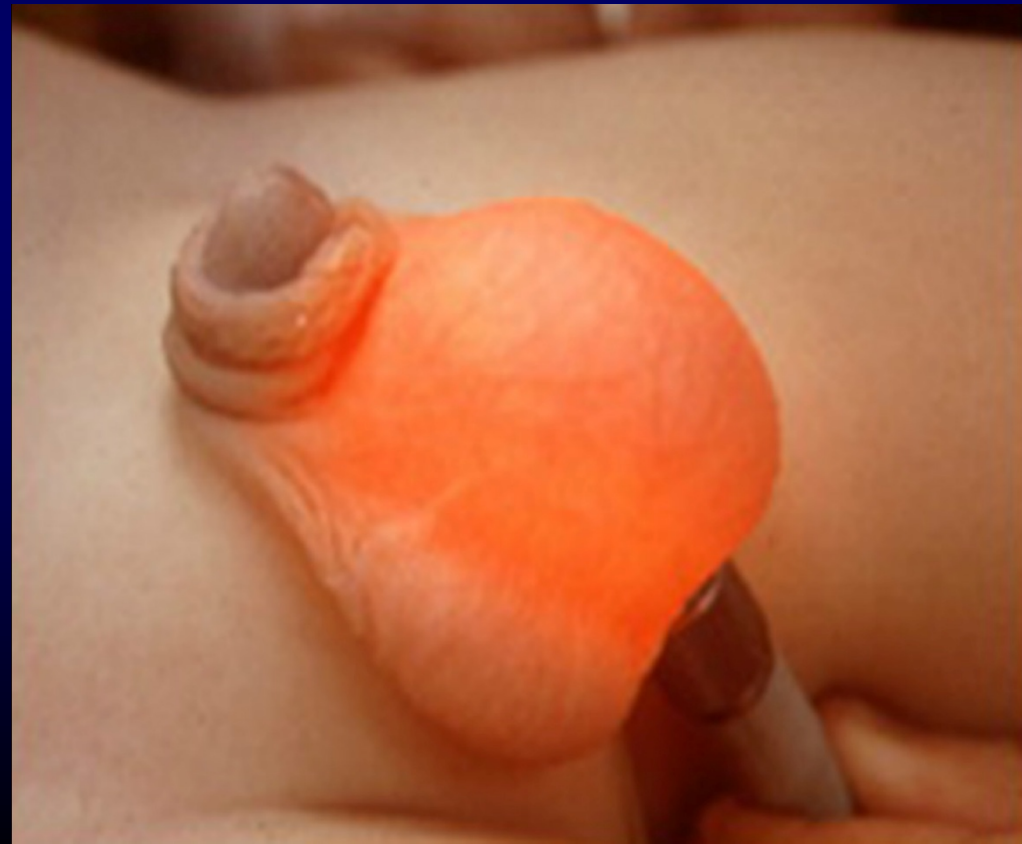- **Commonest external hernia**
- **Male preponderance**
- **Infant / adult**
- **Direct / indirect / combined**
- **Weakness / increased pressure**
- **Cause pain / discomfort**
- **Carry risk of complications**



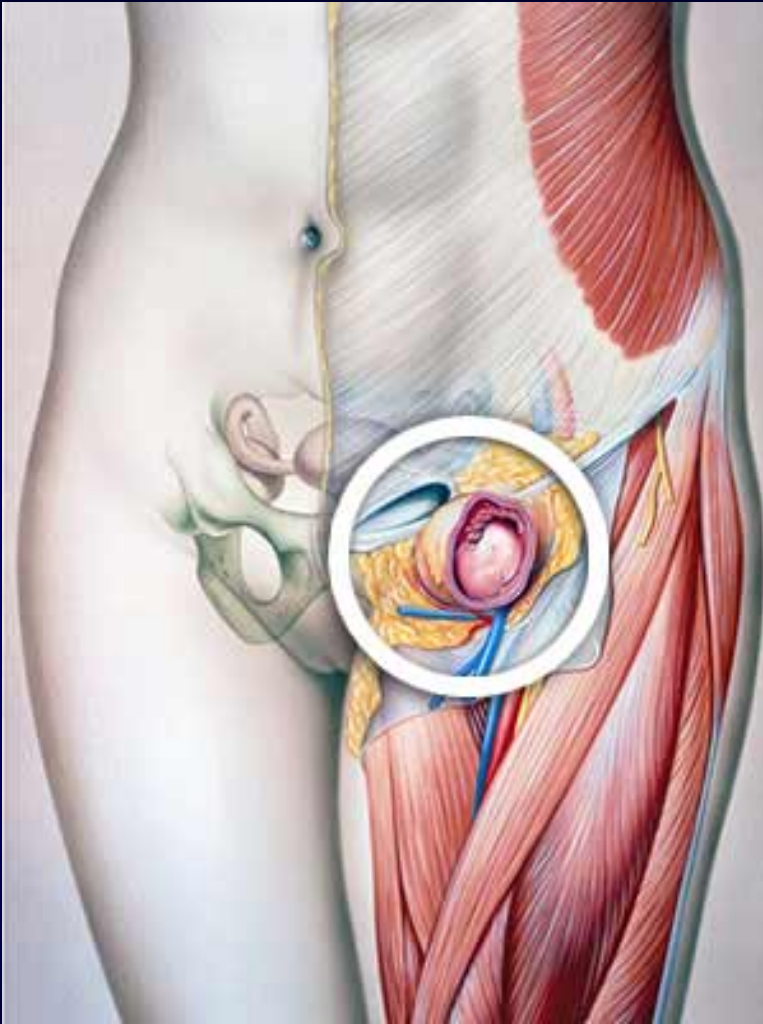Assessment of the superficial inguinal ring

Direct vs. Indirect

- Direct
- Post wall
- Less common
- Older
- Smaller
- Hesselbachs
- Medial
- Lower risk
- Indirect
- Deep ring
- 70%
- Congenital
- Scrotal
- Superficial ring
- Lateral
- Strangulate

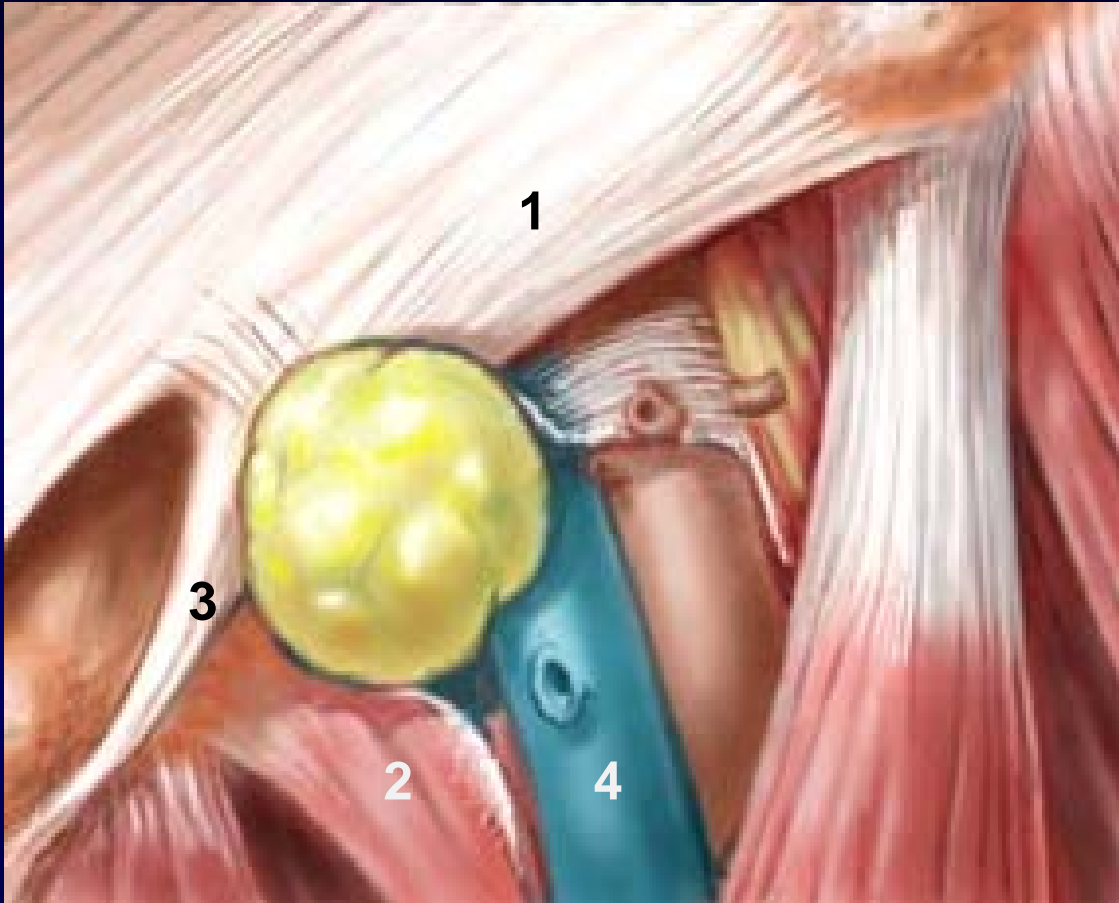


Femoral Hernia



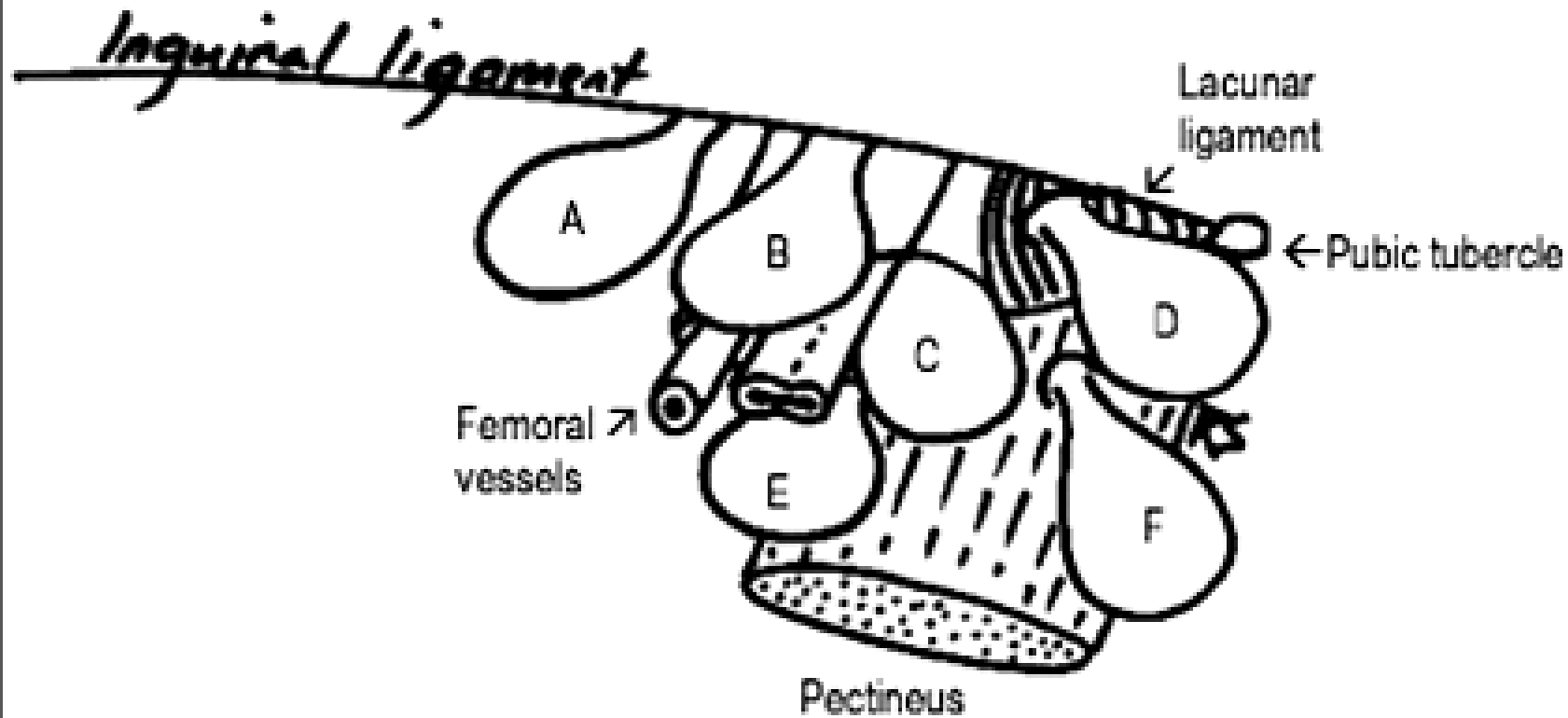
- **Herniation through femoral canal**
- **Appears below and lateral to pubic tubercle**
- **Relatively uncommon**
- **Commoner in females**
- **Contains omentum or small intestine**
- **High risk of strangulation**

Femoral Hernia



1. Pupart ligament
2. Cooper or pectineal ligament
3. Gimbernat or lacunas ligament
4. Femoral vein

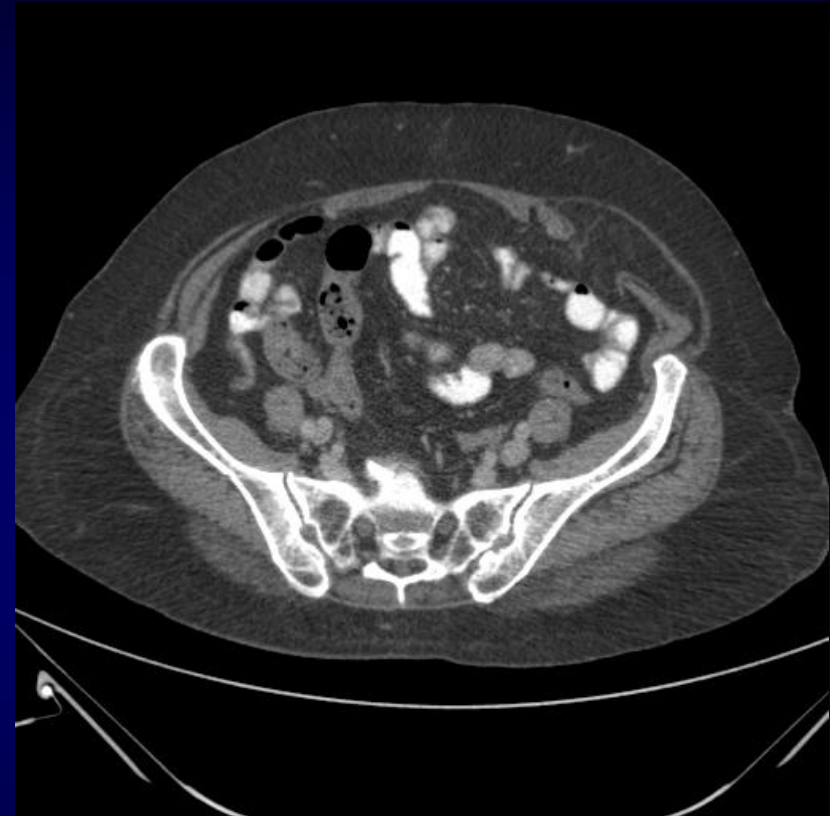
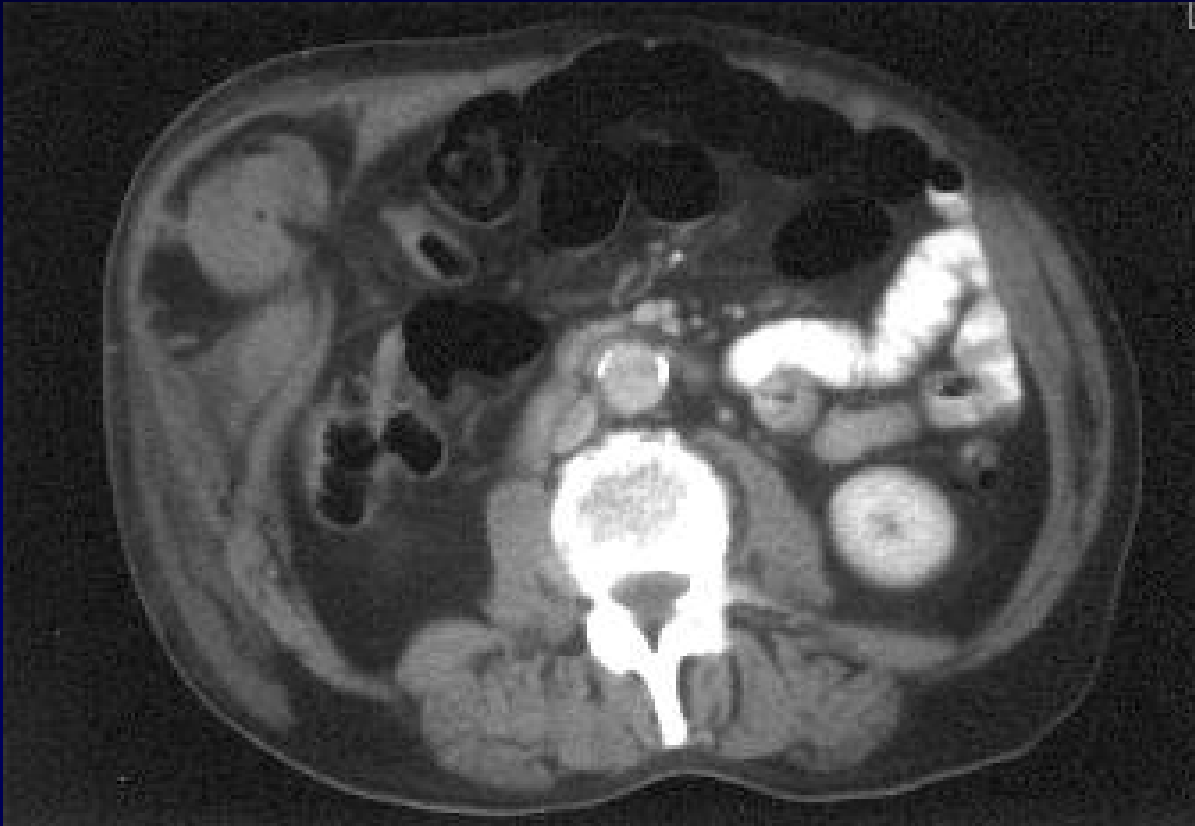Femoral Hernia



Schematic view of right femoral region

- | | |
|-----------------------------------|--------------------------------------|
| A. Hesselbach's hernia | D. Laugier's hernia |
| B. Velpeau's hernia (prevascular) | E. Serafini's hernia (retrovascular) |
| C. Femoral hernia | F. Cloquet's hernia |

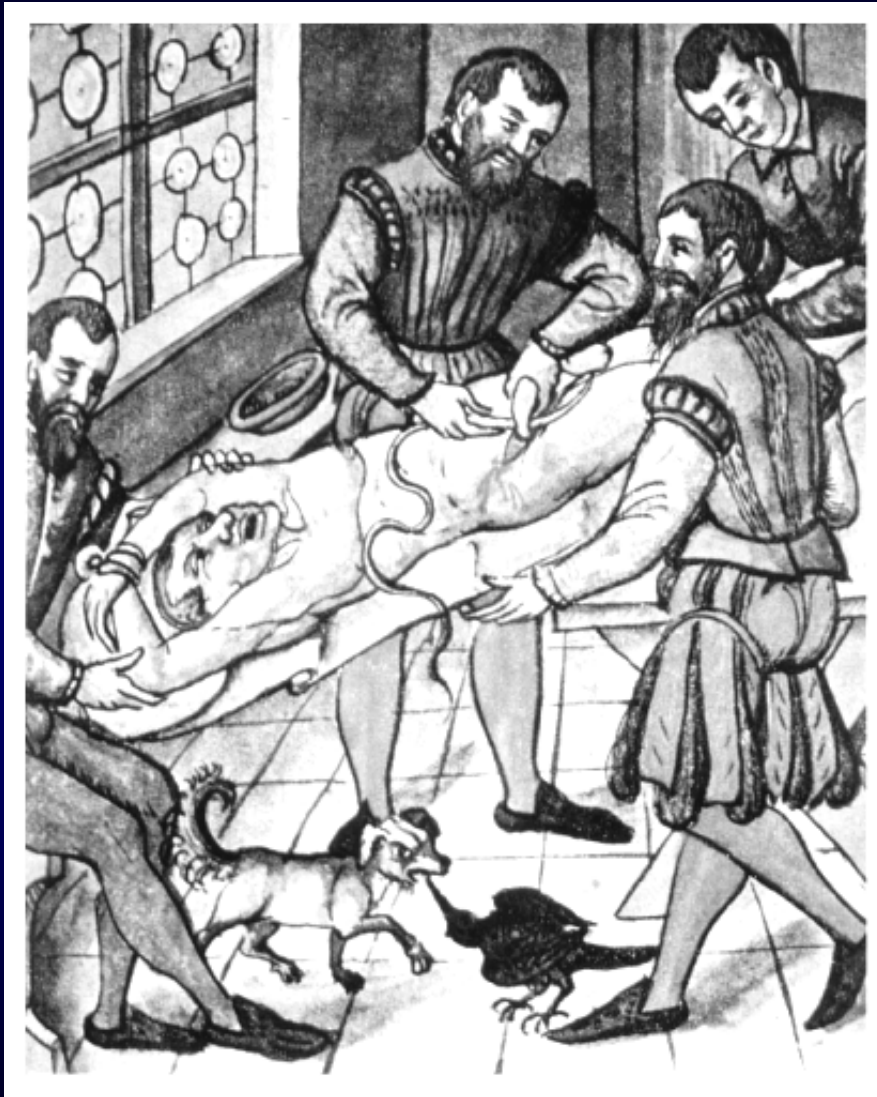
Spigelian hernia



In 1764, Klinkosch first reported hernias through this area and named them “Spigelian line hernias.”

These hernias constitute from 0.12% to 2% of abdominal wall hernias

Surgical Treatment



Eduardo Bassini
1844 – 1924

Indications for open hernia repair

Classically, the existence of an inguinal hernia has been reason enough for operative intervention. However, recent studies have shown that the presence of a reducible hernia is not, in itself, an indication for surgery and that the risk of incarceration is less than 1%.

Symptomatic patients (with pain or discomfort) should undergo repair; however, up to one third of patients with inguinal hernias are asymptomatic. The question of observation versus surgical intervention in this asymptomatic or minimally symptomatic population was recently addressed in 2 randomized clinical trials. The trials found similar results, namely that after long-term follow-up, no significant difference in hernia-related symptomology was noted, and that watchful waiting did not increase the complication rate.

O'Dwyer PJ, Norrie J, Alani A, Walker A, Duffy F, Horgan P. Observation or operation for patients with an asymptomatic inguinal hernia: a randomized clinical trial. *Ann Surg.* Aug 2006;244(2):167-73.

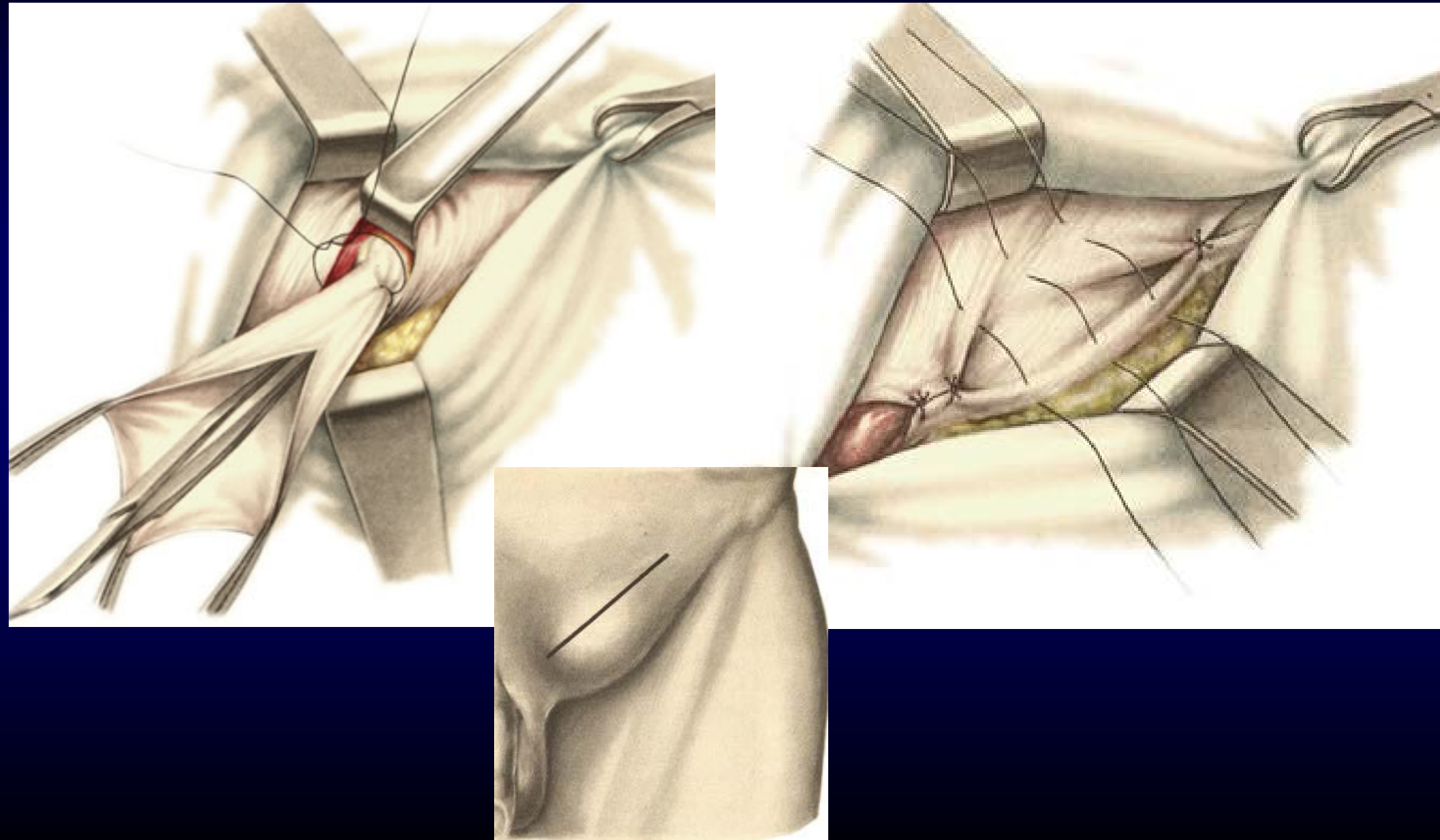
Contrindications

Inguinal hernia repair has no absolute contraindications. Just as in any other elective surgical procedure, the patient must be medically optimized. Any medical issues, whether acute (eg, upper respiratory tract or skin infection) or exacerbations of underlying medical conditions (eg, poorly controlled diabetes mellitus), should be fully addressed and the surgery delayed accordingly.

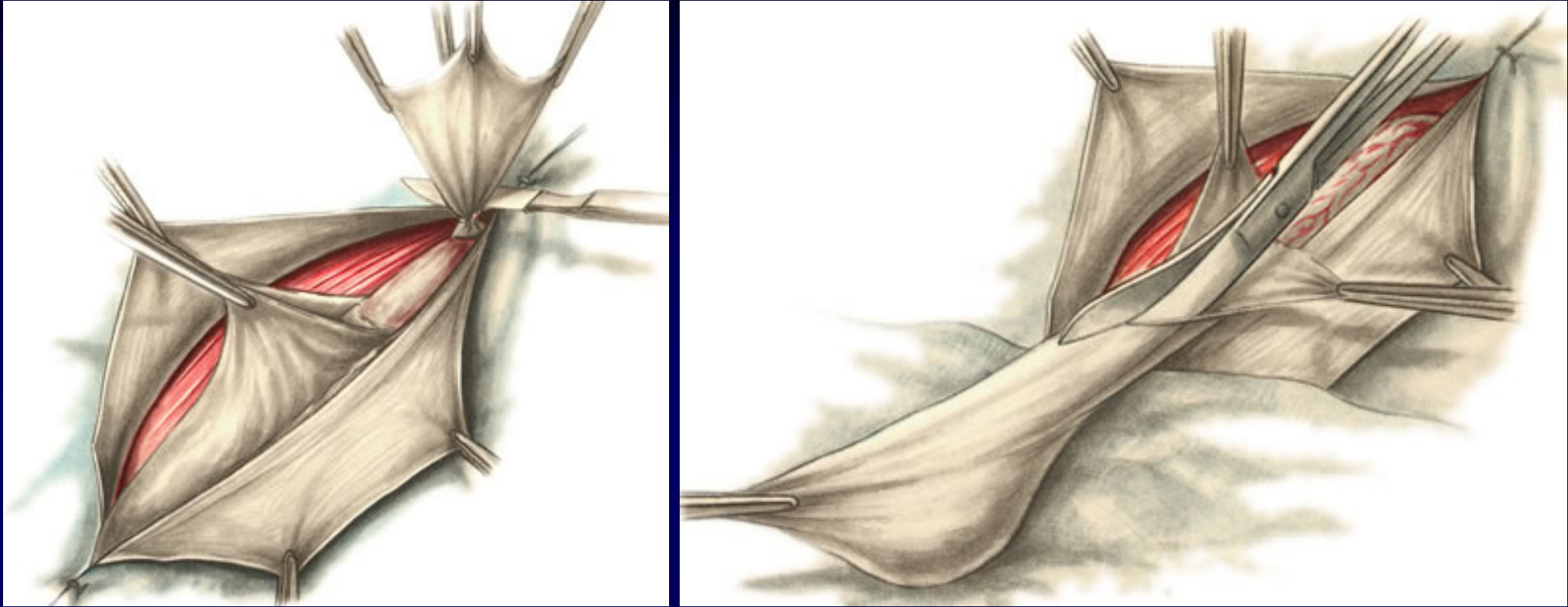
Patients with elevated American Society of Anesthesiologists (ASA) scores and high operative risk should undergo a full preoperative workup and determination of the risk-to-benefit ratio.

Congenital Hernia Repair

Roux procedure

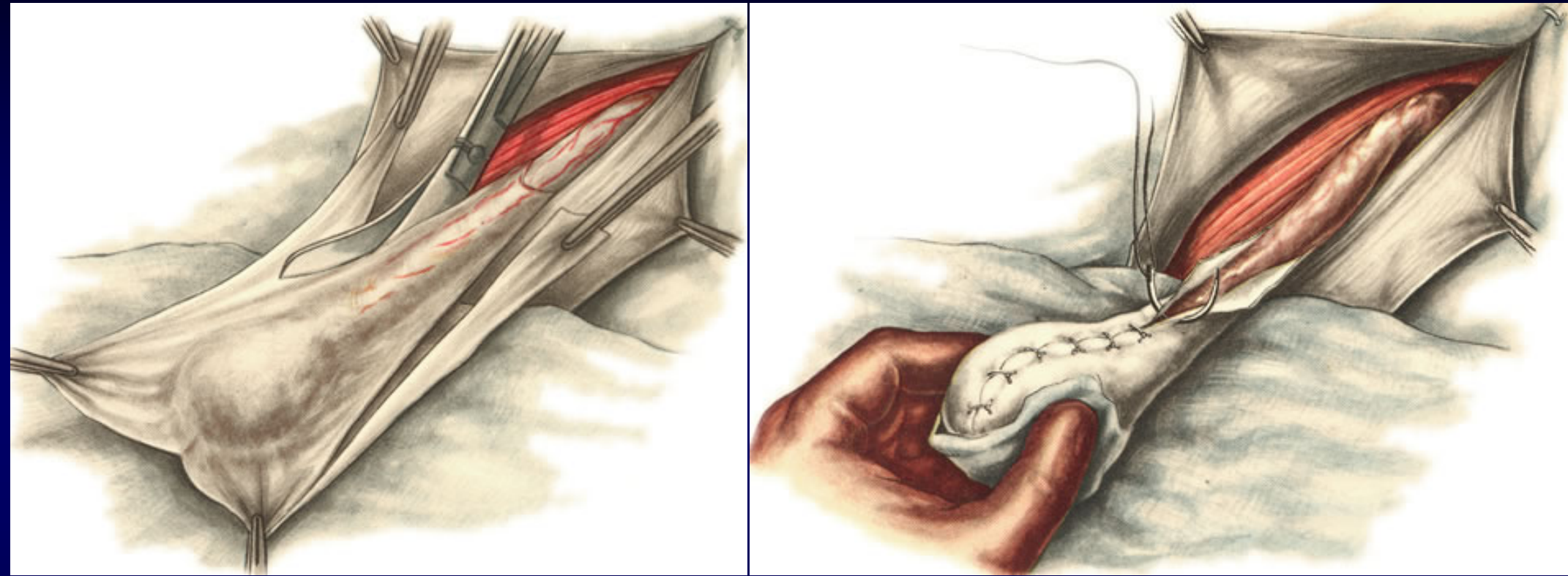


Congenital hernia repair



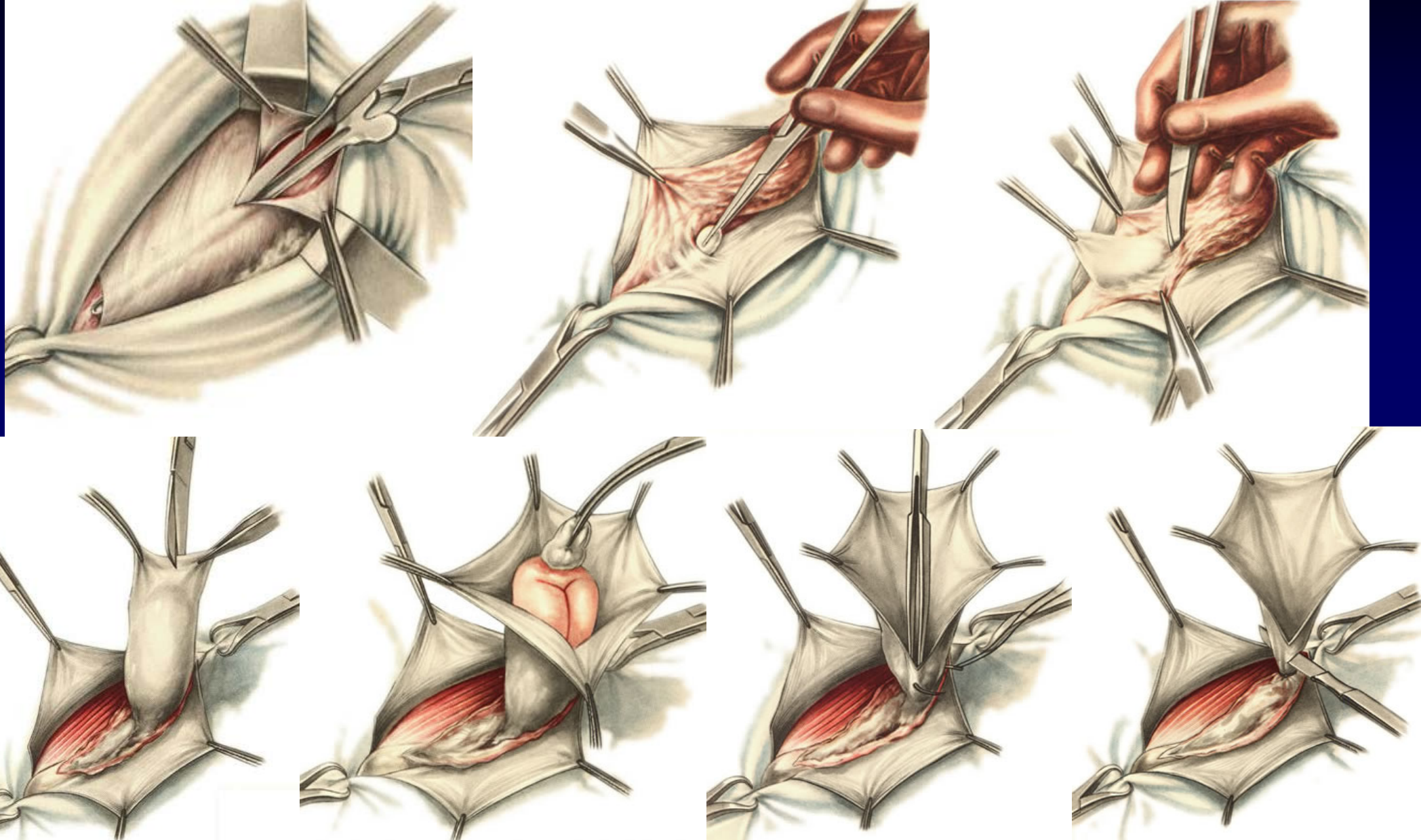
Vinkelman procedure in congenital inguinal hernia

Congenital hernia repair

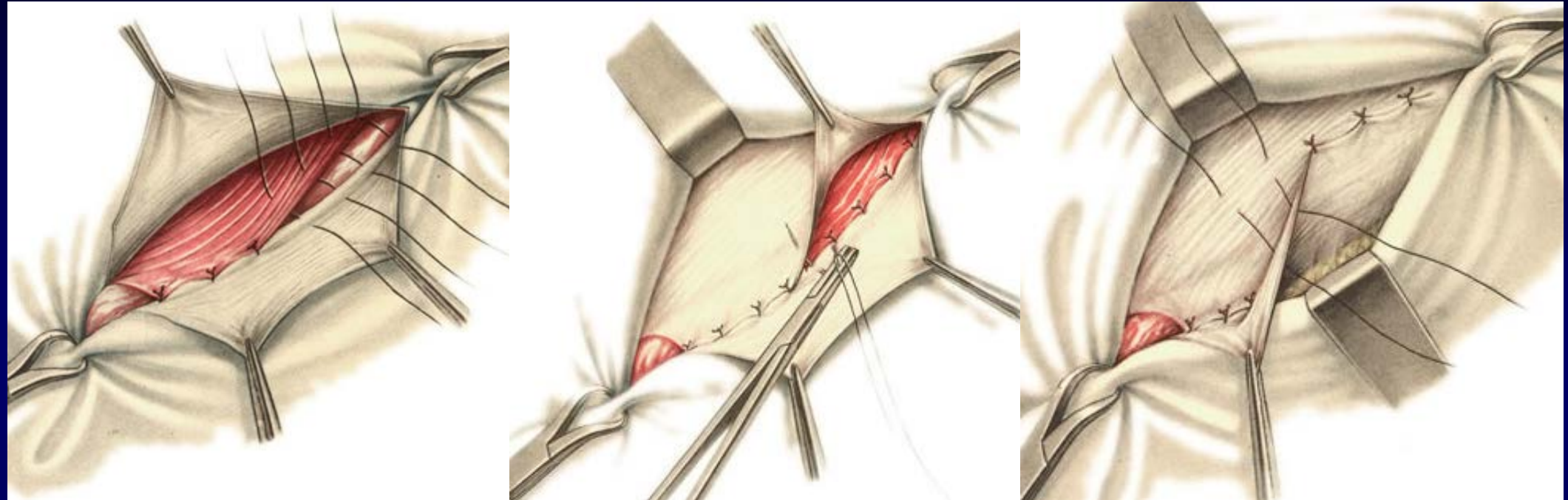


Vinkelman procedure in congenital inguinal hernia

Herniotomy

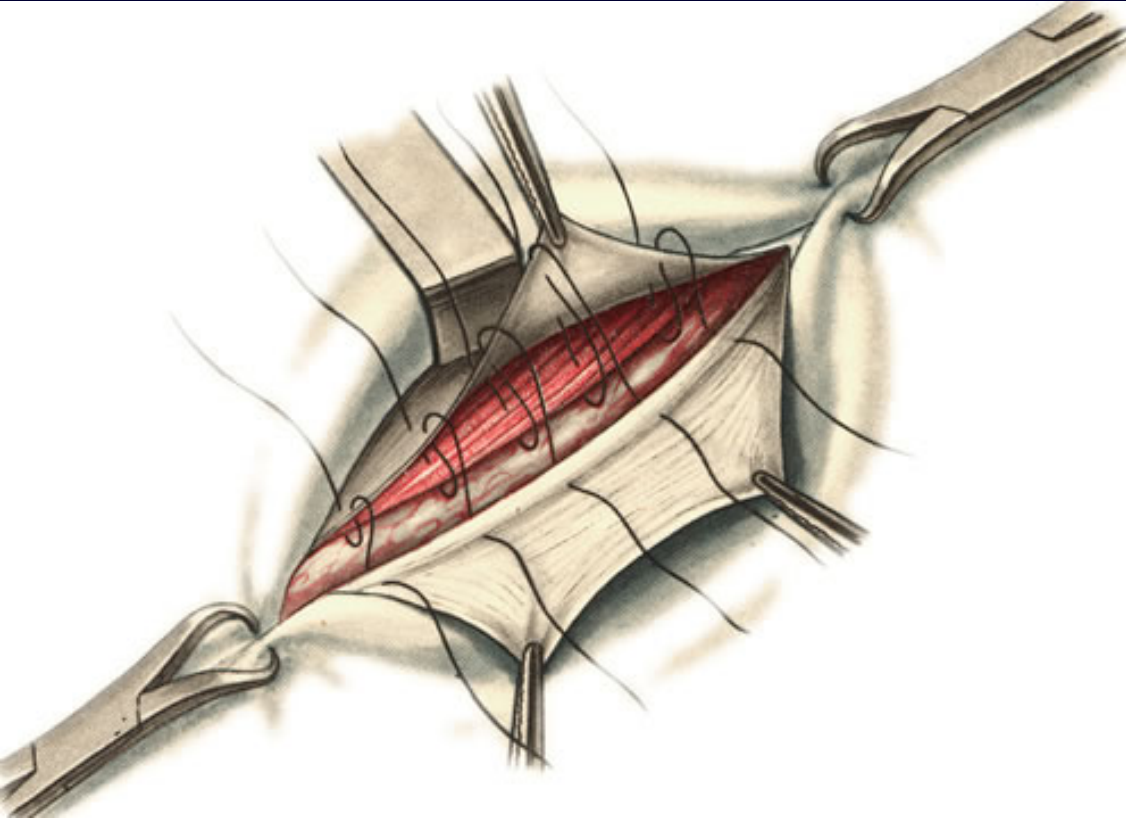


Girard-Spasokukotsky procedure

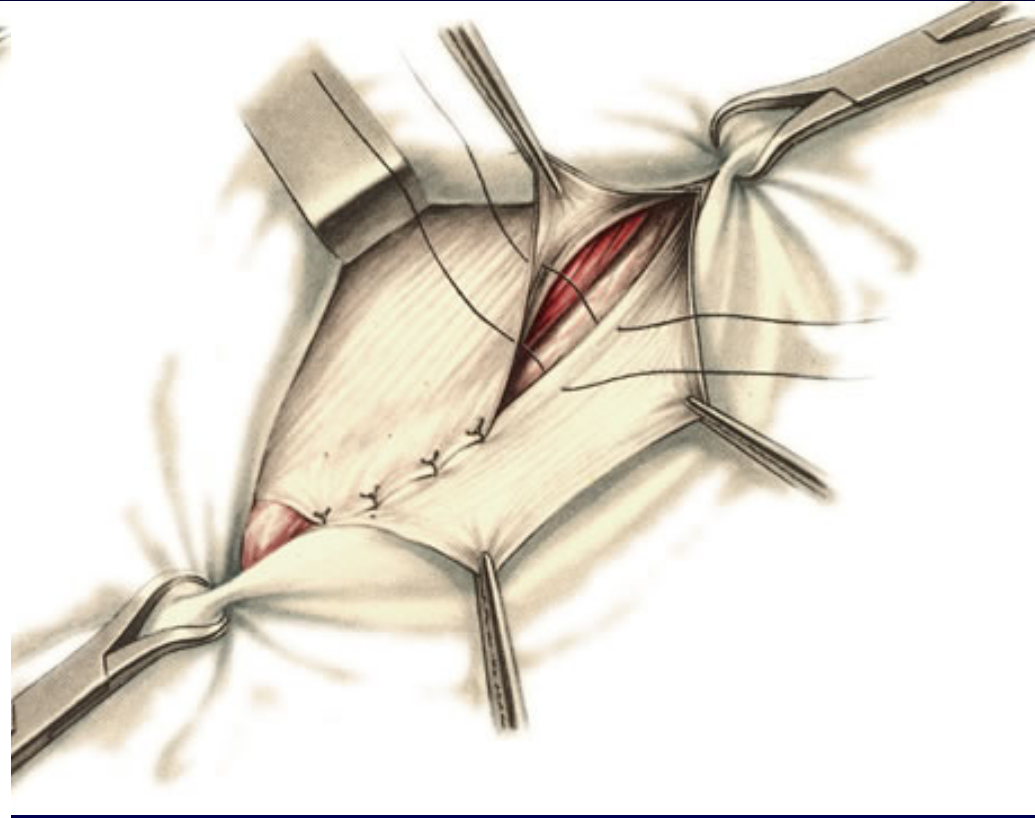


- Transversal muscle and internal oblique muscle are approximated to Poupart ligament
- Duplication of the aponeurosis of external oblique muscle

Kimbarowsky procedure



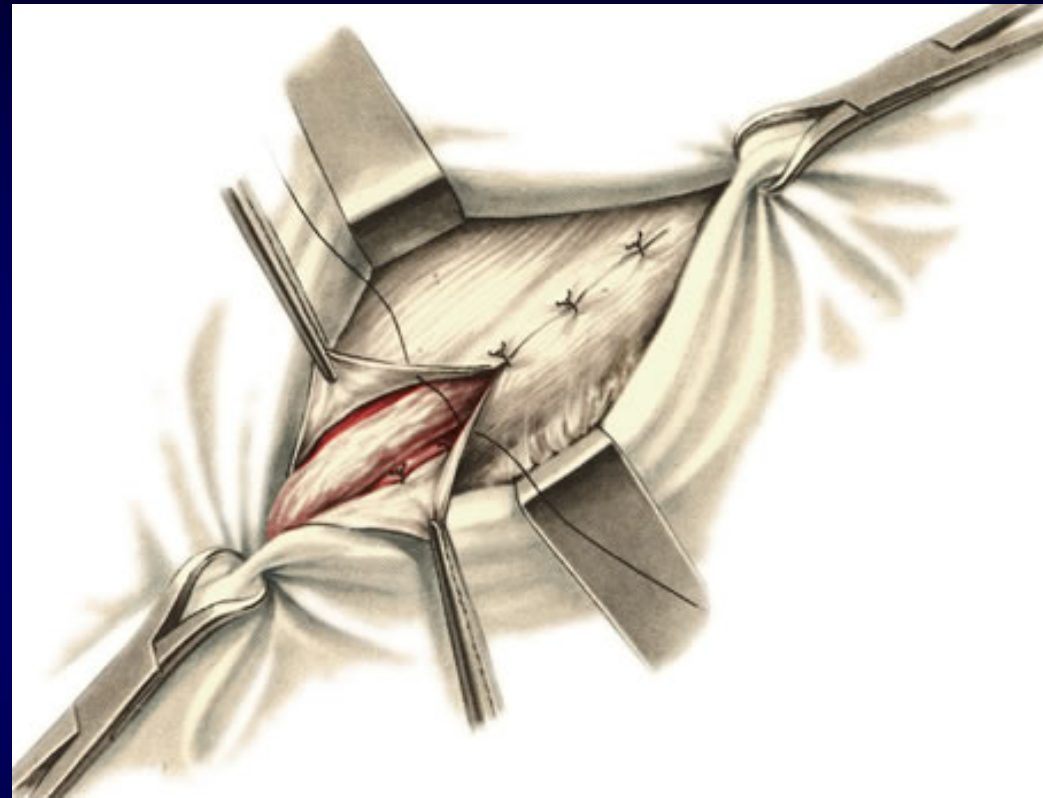
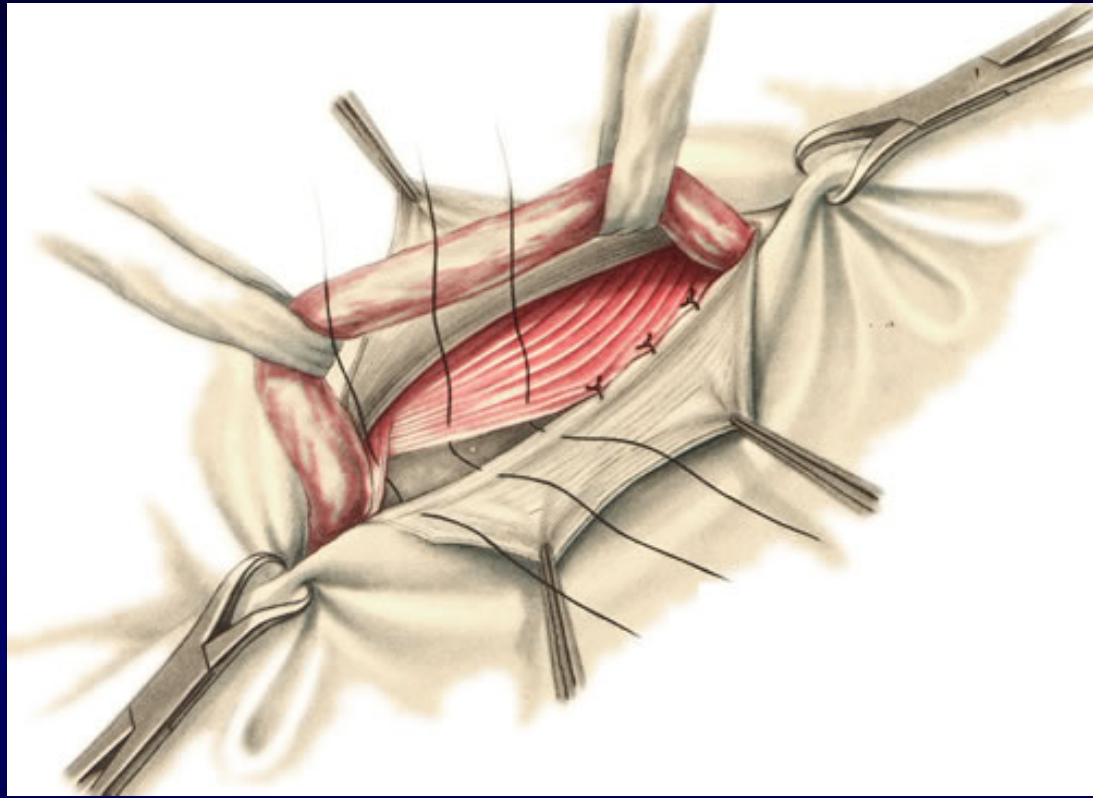
Martinov procedure



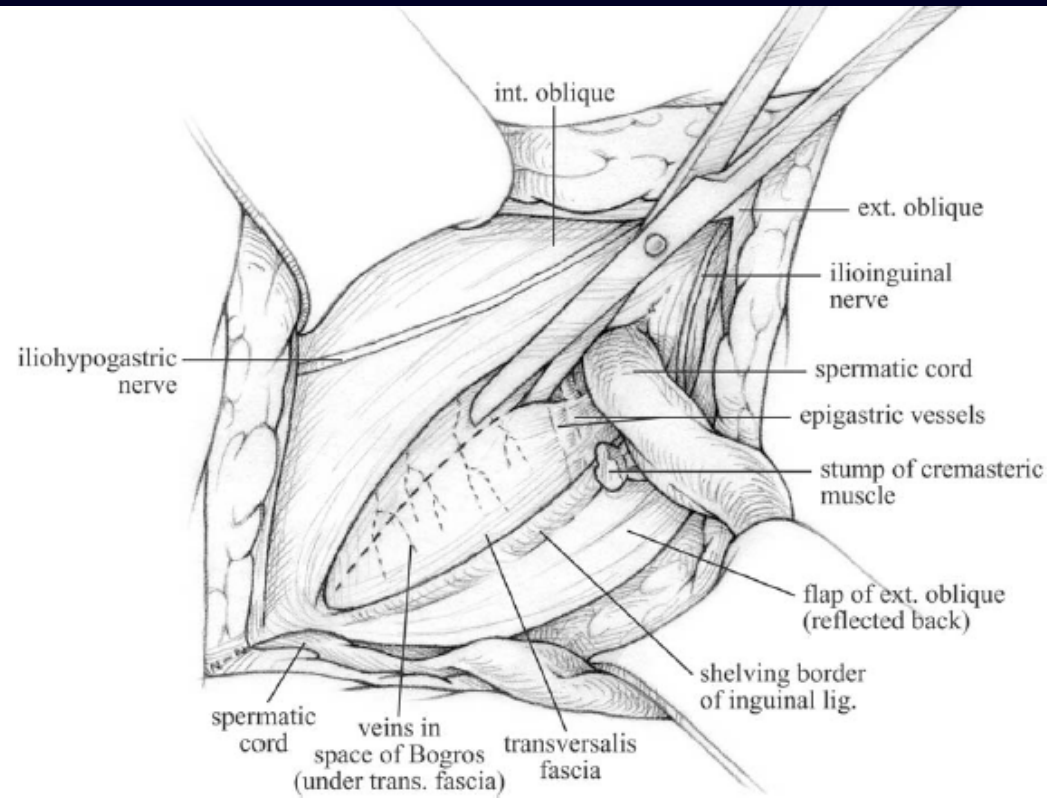
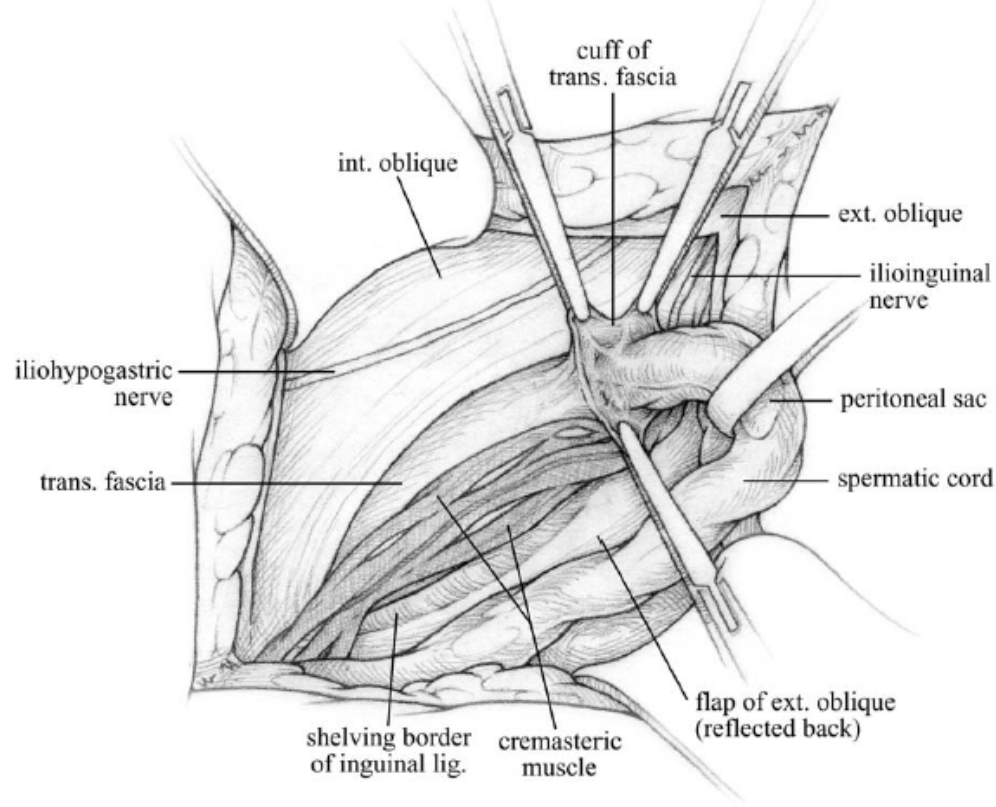
Application of sutures type “U”
during Girard-Spasokukotsky
procedure

Duplication of the aponeurosis of
external oblique muscle

Bassini Procedure



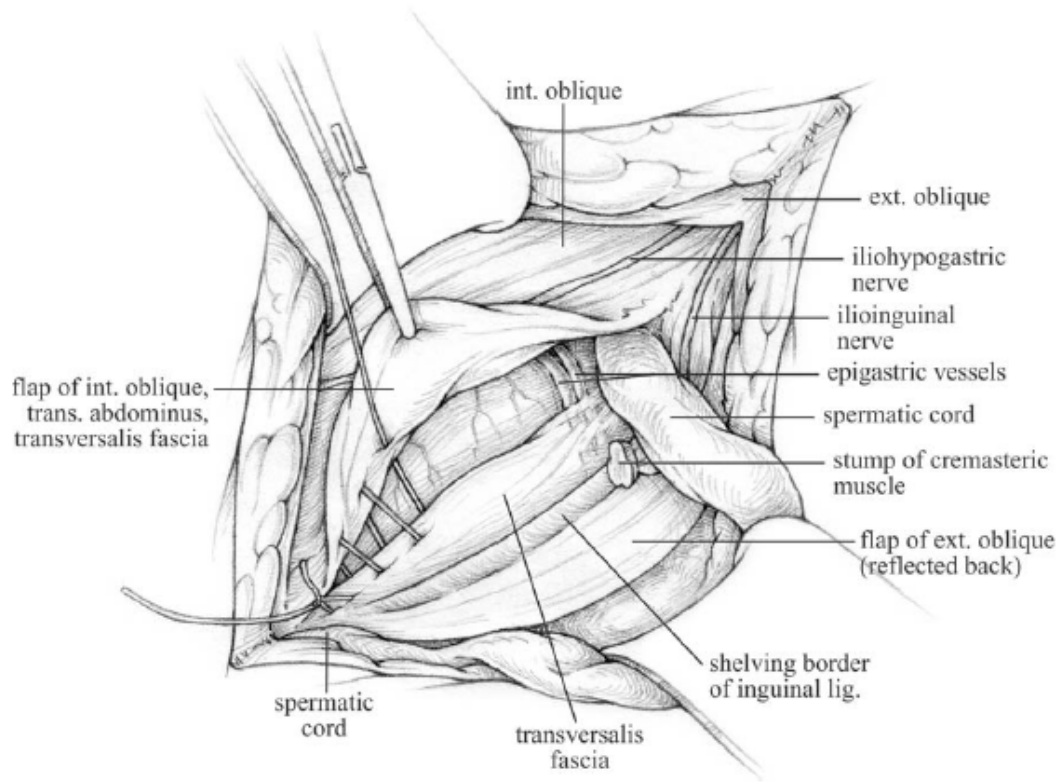
The Shouldice repair for groin hernias



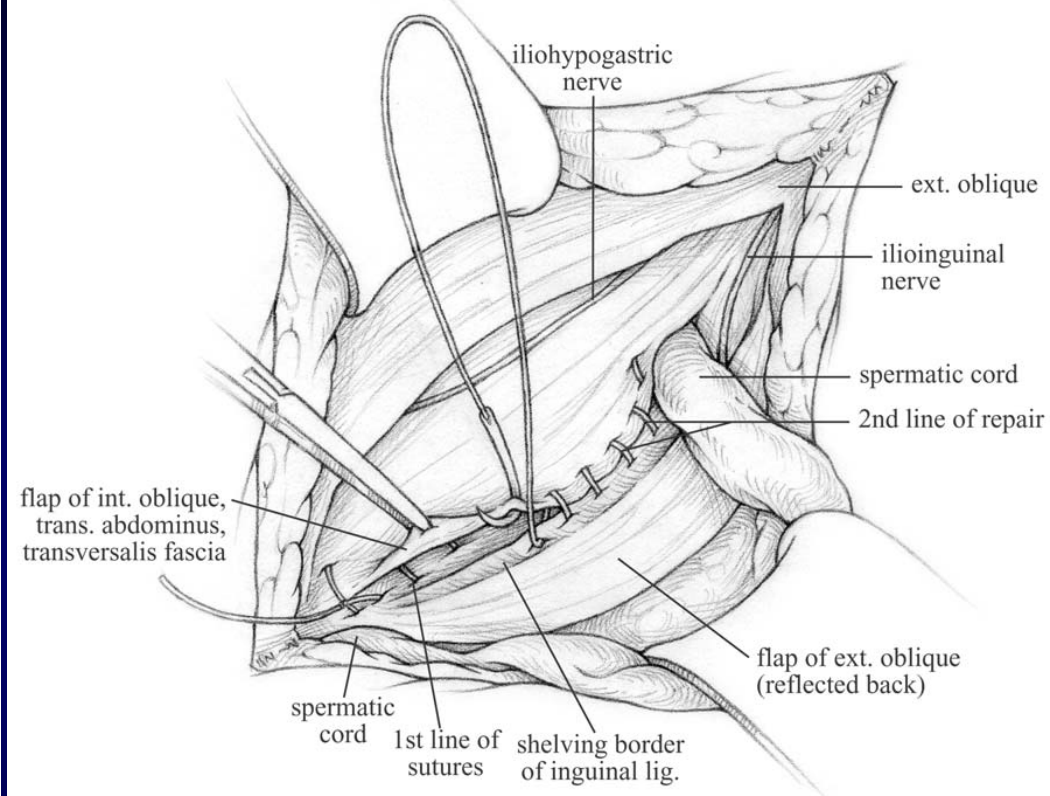
Freeing the cuff of transversalis fascia from the spermatic cord at the internal ring. Note the cremasteric tissue lies intact on the canal floor but is being freed at the internal ring.

Splitting of the transversalis fascia from the internal ring to the pubic crest as far as desired.

The Shouldice repair for groin hernias

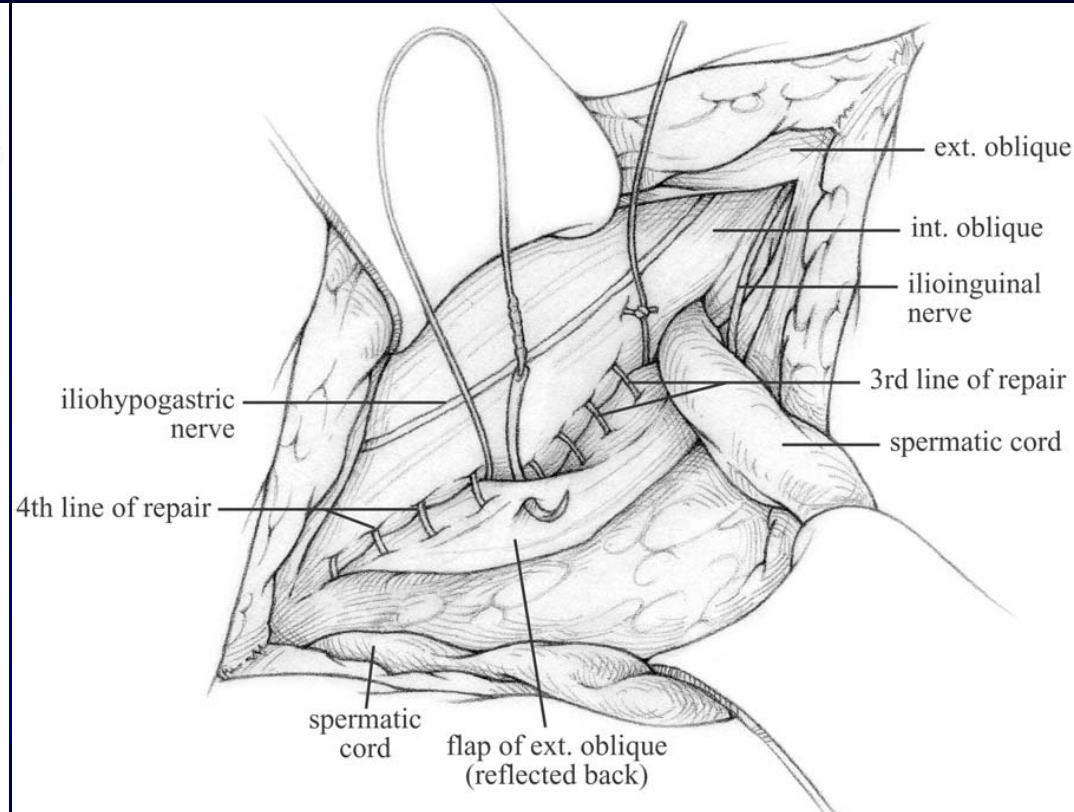
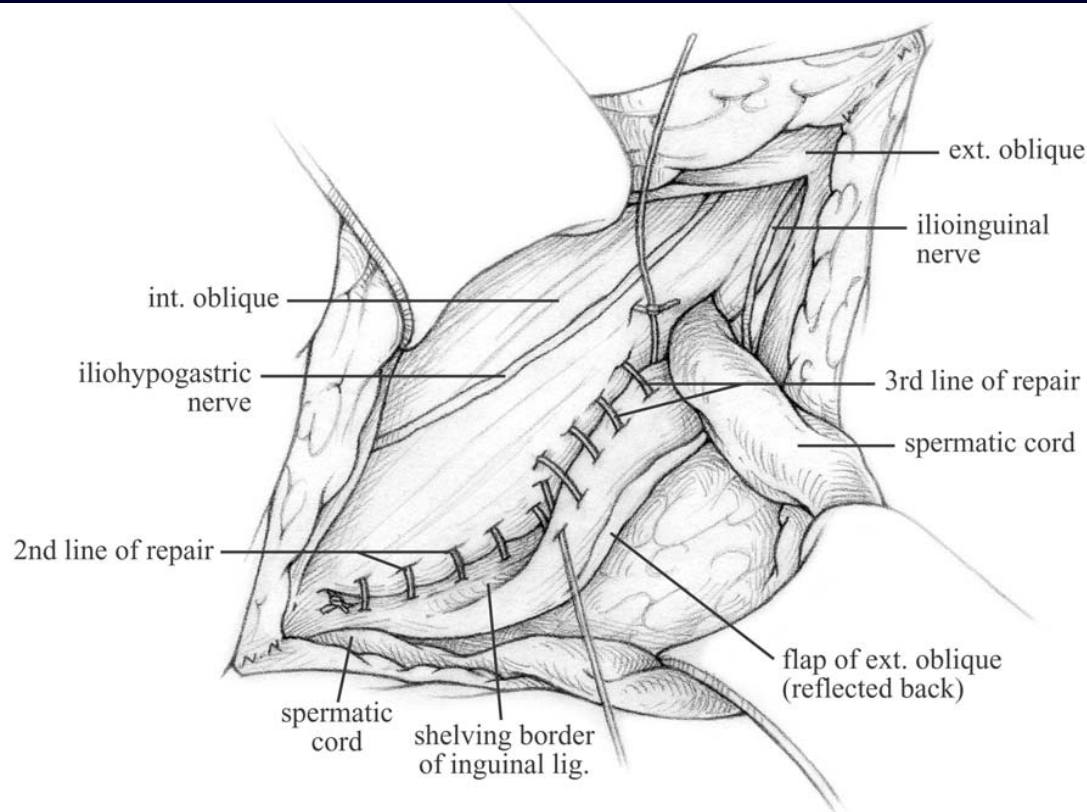


First suture line continues to tack the lateral flap of transversalis fascia to the transversalis fascia lying medially beneath the rectus, transversus abdominis, and internal oblique muscles.




Second suture line “carrying” the previous established medial flap of tissue to the curved or shelving edge of the inguinal ligament.

The Shouldice repair for groin hernias



The undersurface of the external oblique close to inguinal ligament is now in this third line of sutures being tacked over the internal oblique.

Classification of prosthetic materials by P.K.Amid (1997)



Type I

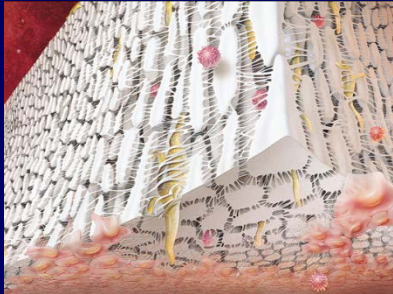


Totally macroporous prostheses (>75 μ m)

„Marlex” (monofilament polypropylene)

„Prolene”(double filament polypropylene)

„Atrium”(monofilament Polypropylene)



Type II



Totally microporous prostheses (<10 μ m)

„Gore-tex”(expanded PTFE)



Type III



Mix-prostheses (macroporous with multifilamentous or microporous components)

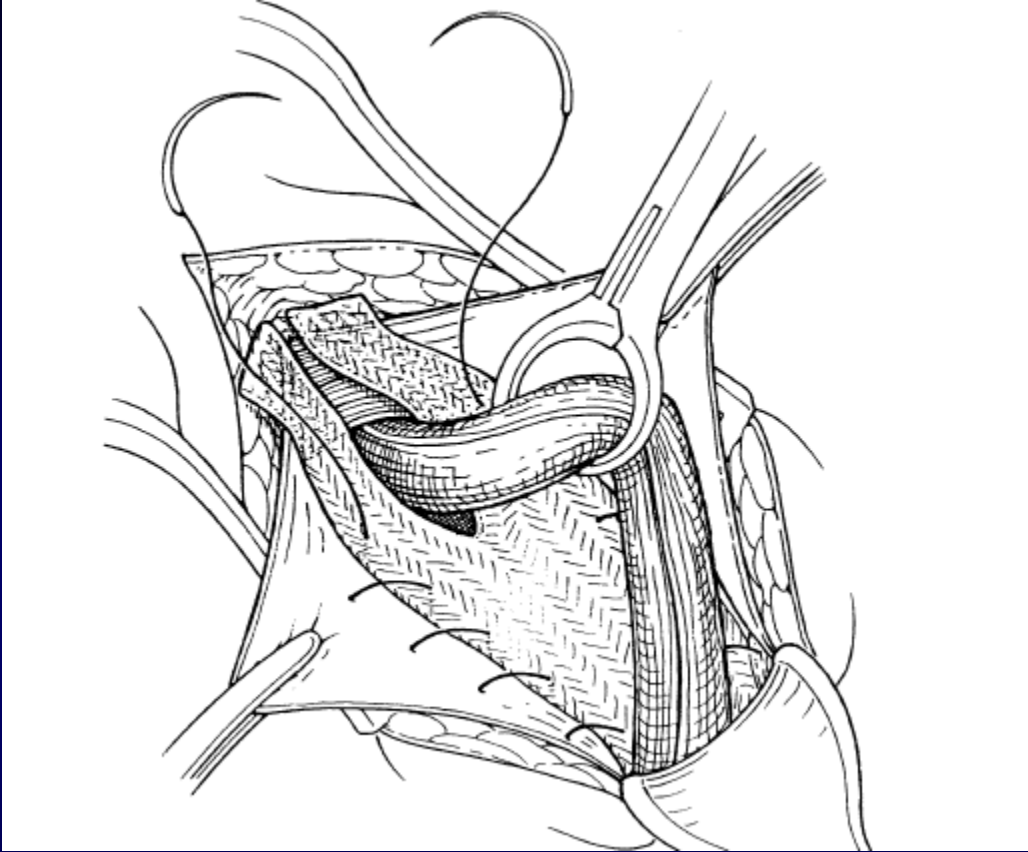
„Teflon” (PTFE mesh)

„Mersilene”(braided dacron mesh)

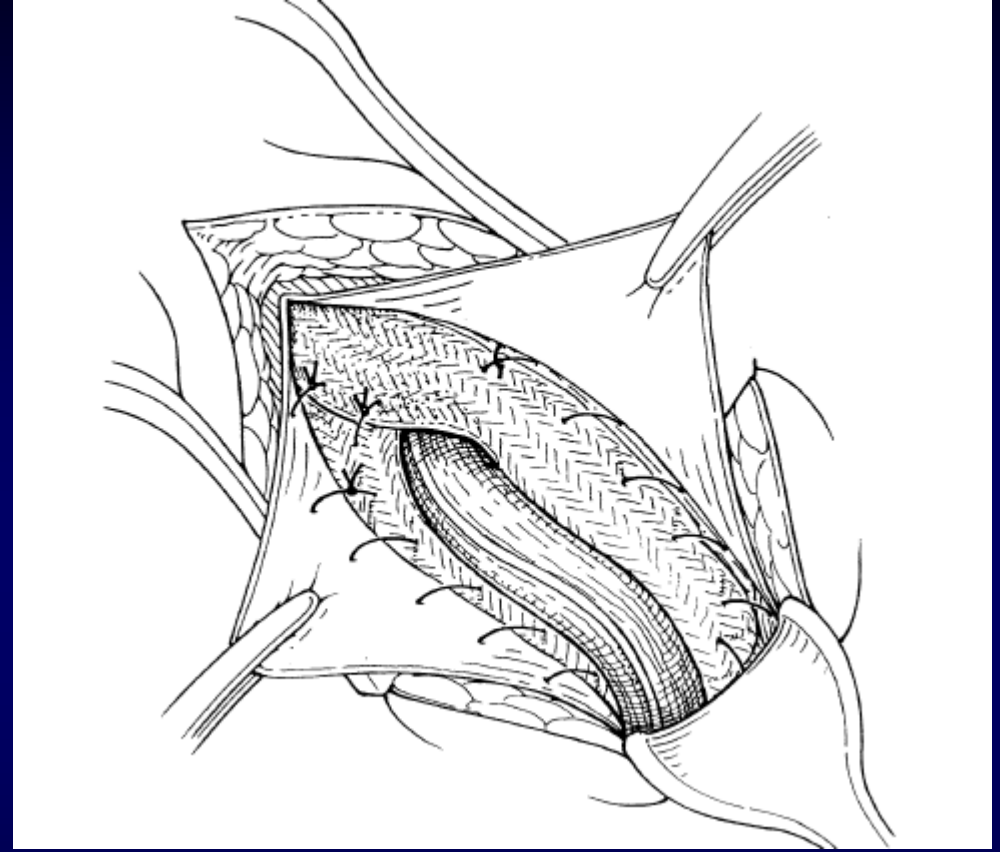
„Surgipro”(braided polypropylene mesh)

„Micromesh”(perforated PTFE patch)

Lichtenstein procedure



Mesh placement and attachment. The infero-medial corner of the mesh (not shown) is secured to the soft tissues overlying the pubic tubercle with a 2- or 3-cm overlap.



Tails of the mesh encircling the spermatic cord. One or two sutures are placed where the tails of the mesh cross lateral to the cord to ensure a snug fit.

SAFESTITCH
MEDICAL

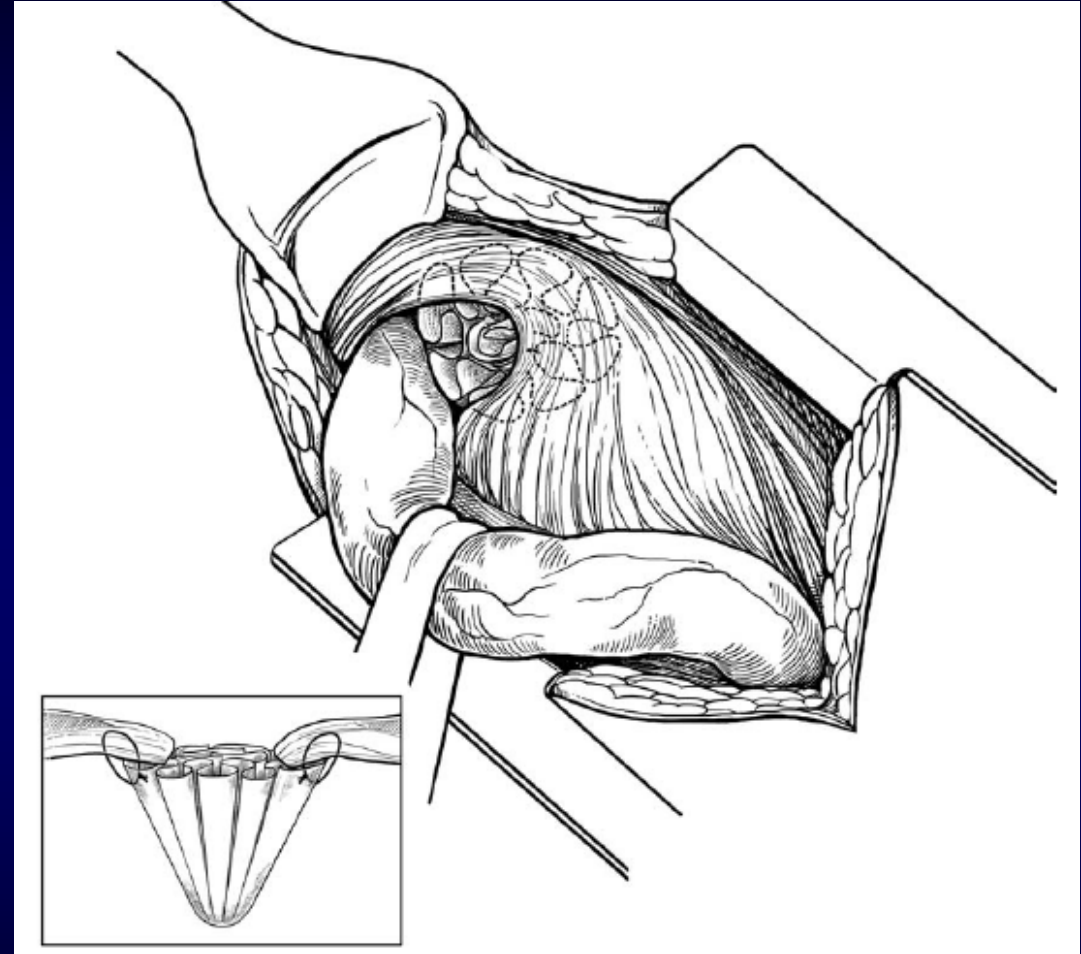

The Amid Stapler®
Instructional Animation

Where Safety Meets Innovation

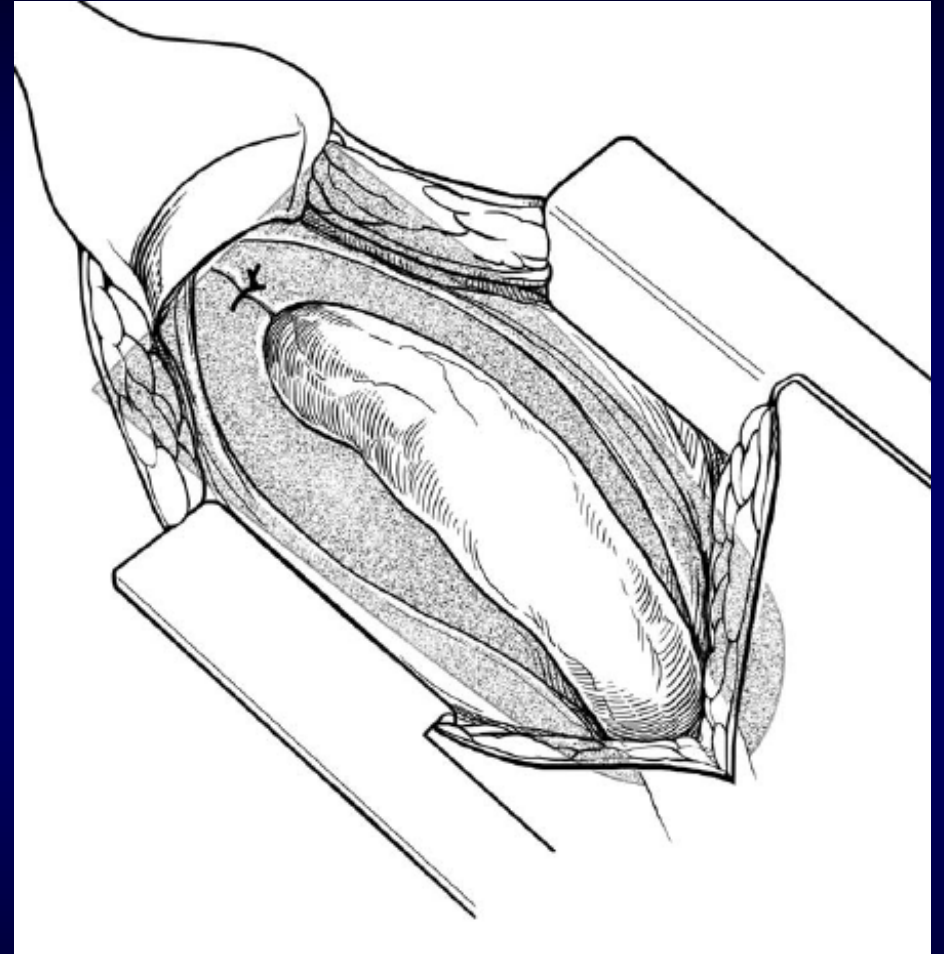
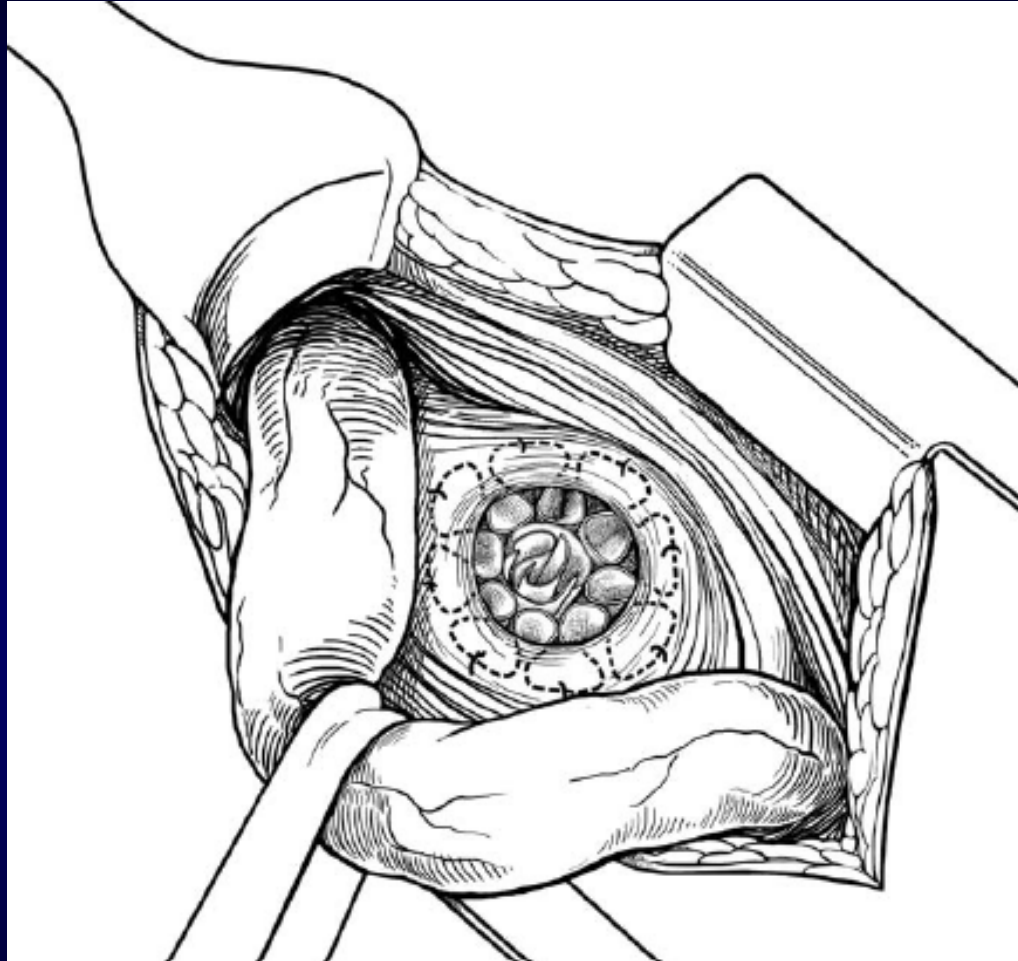
www.SafeStitch.com



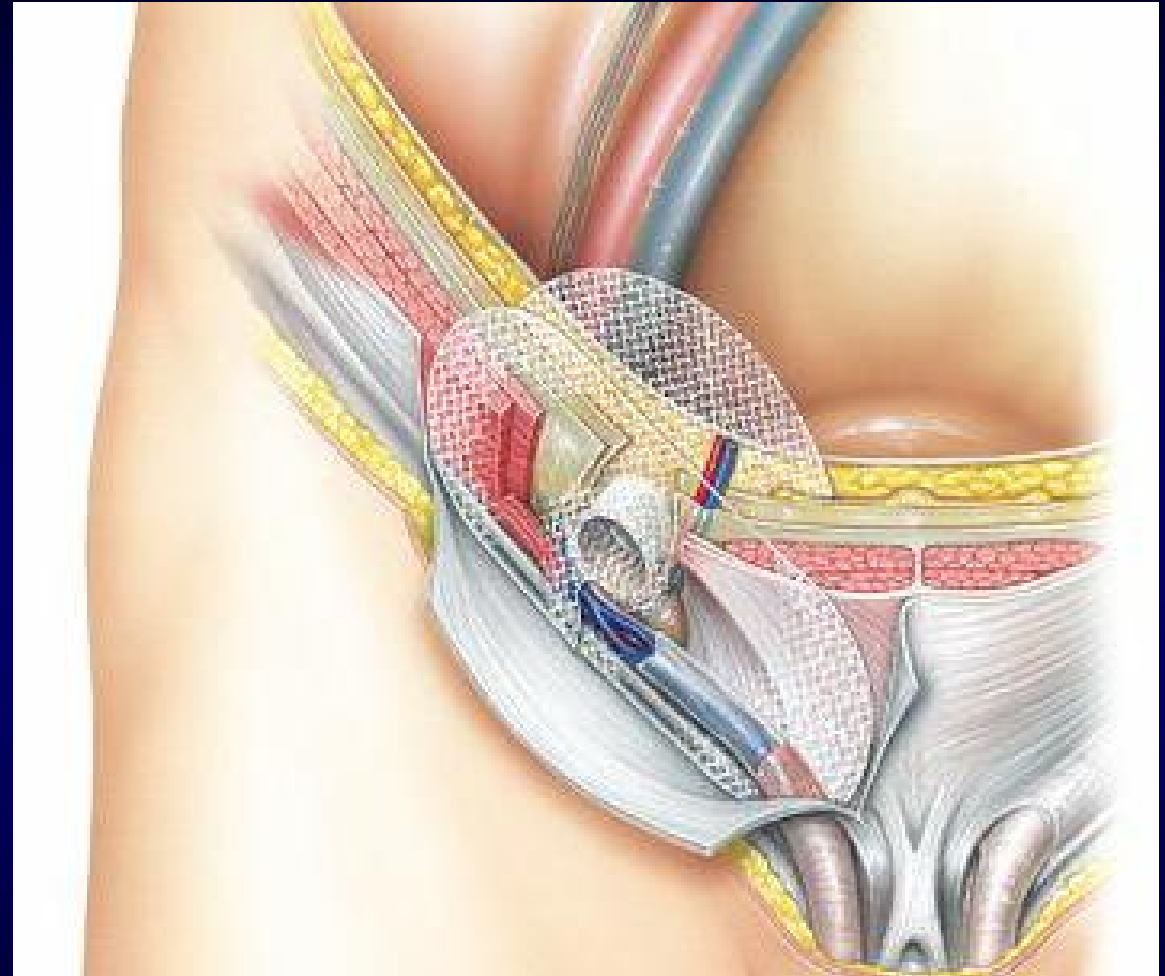
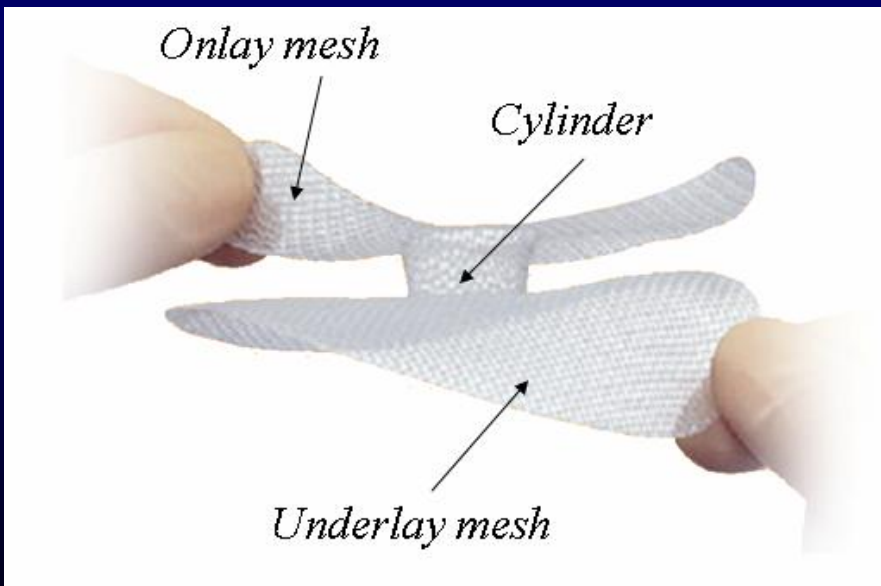
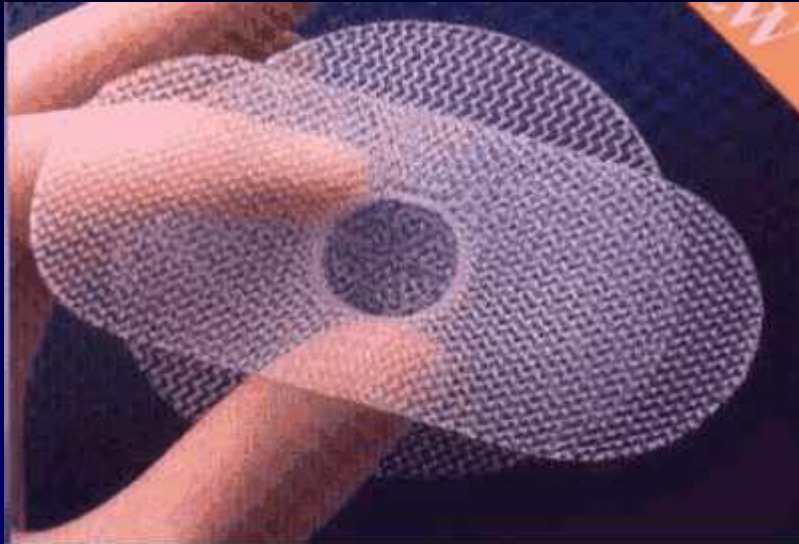
Rutkow-Robbins procedure (mesh-plug repair)



Rutkow-Robbins procedure (mesh-plug repair)



PROLENE Hernia System (PHS)



Plastica di

ernia

inguinale

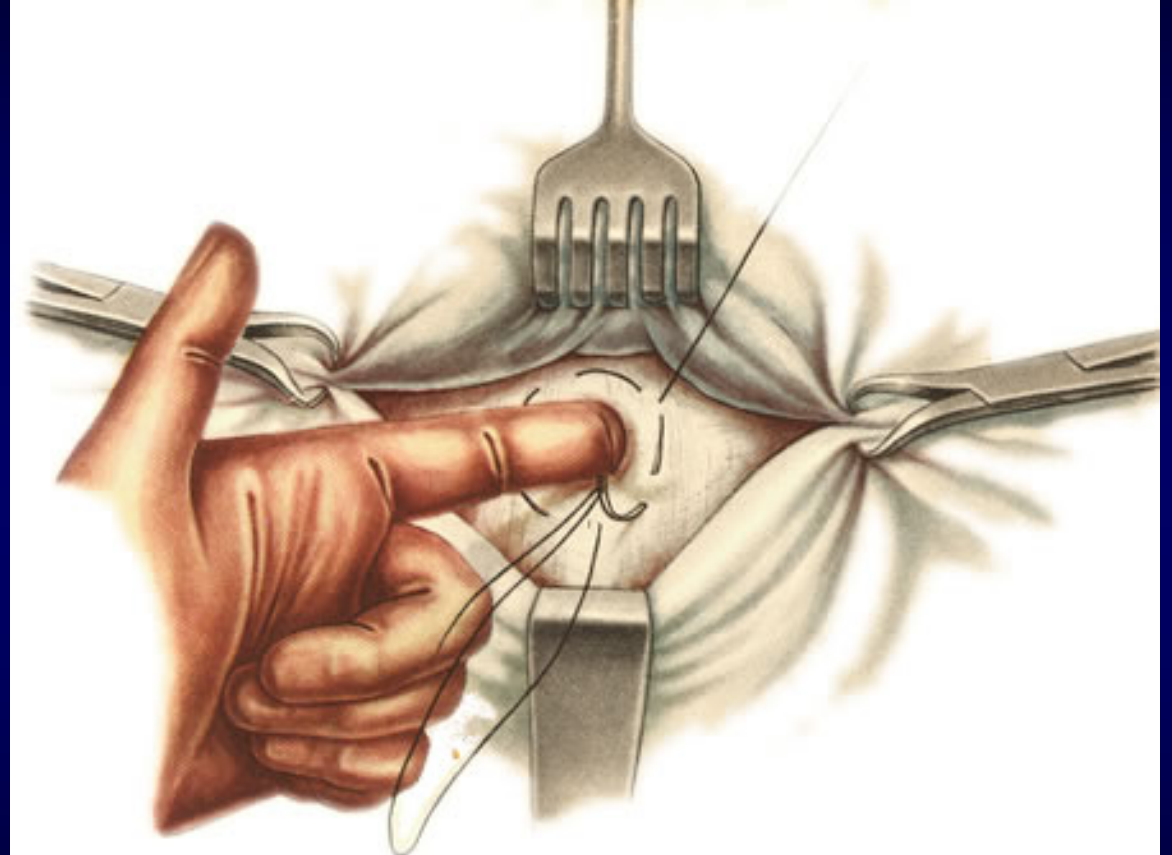
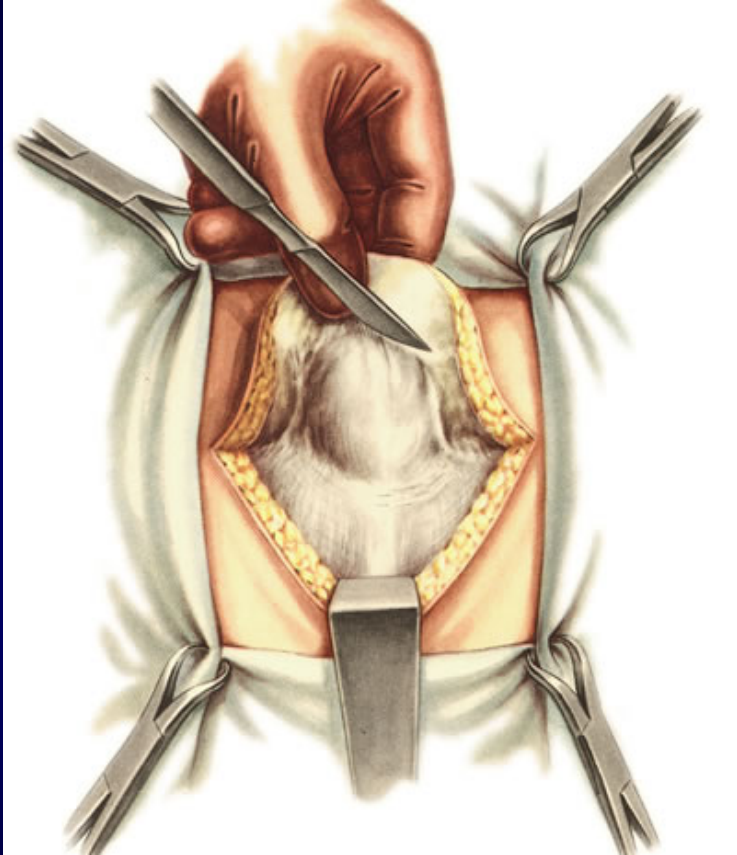
indiretta

(Gilbert II-III)

con protesi PHSe

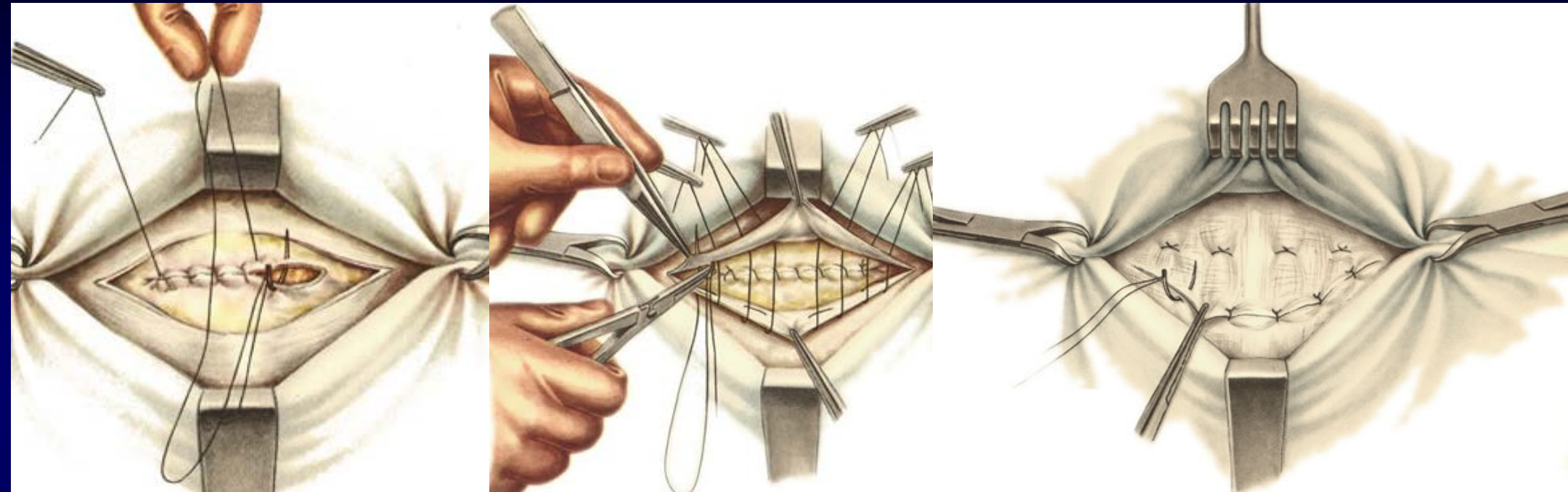
Umbilical Hernia

Lexer procedure



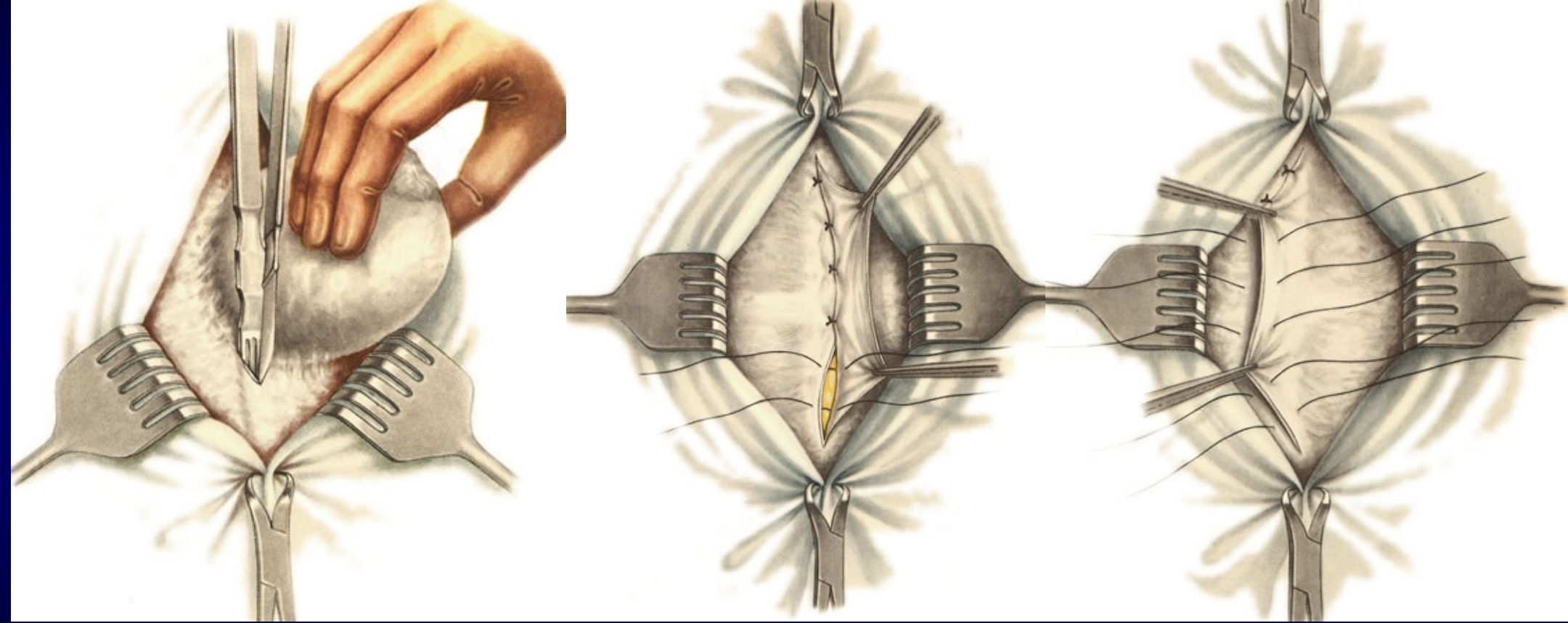
Circle-suture around umbilicus

Mayo procedure



Horizontal fascial duplication

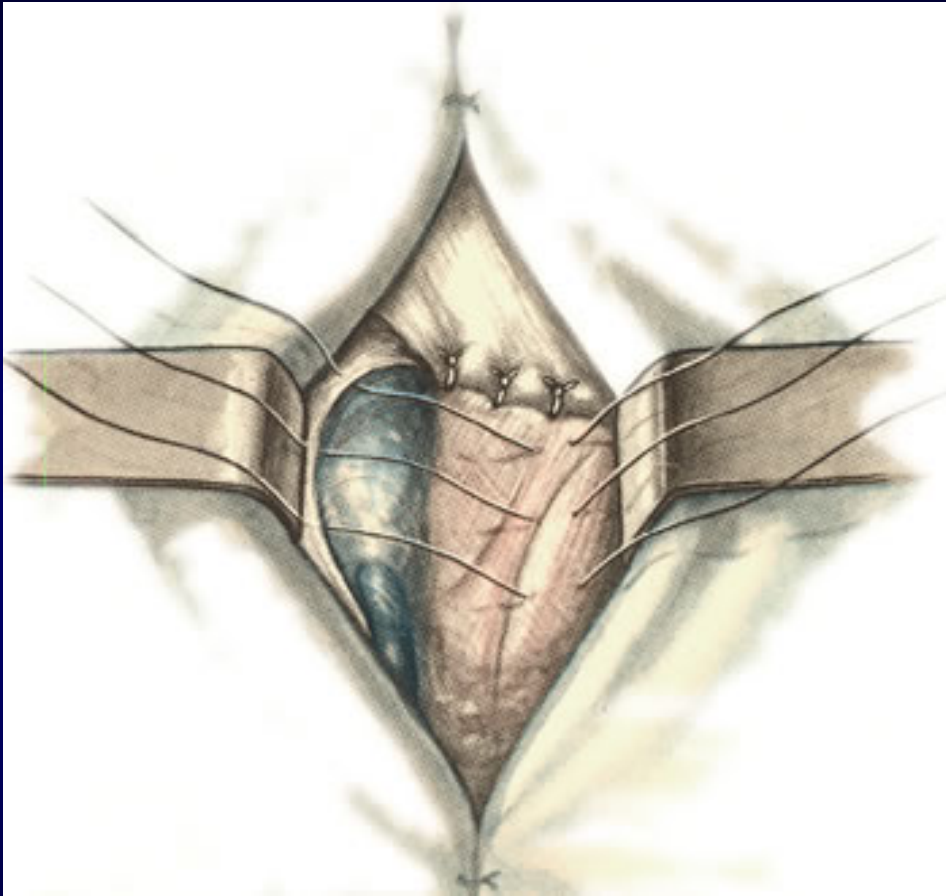
Sapejko procedure



Vertical fascial duplication

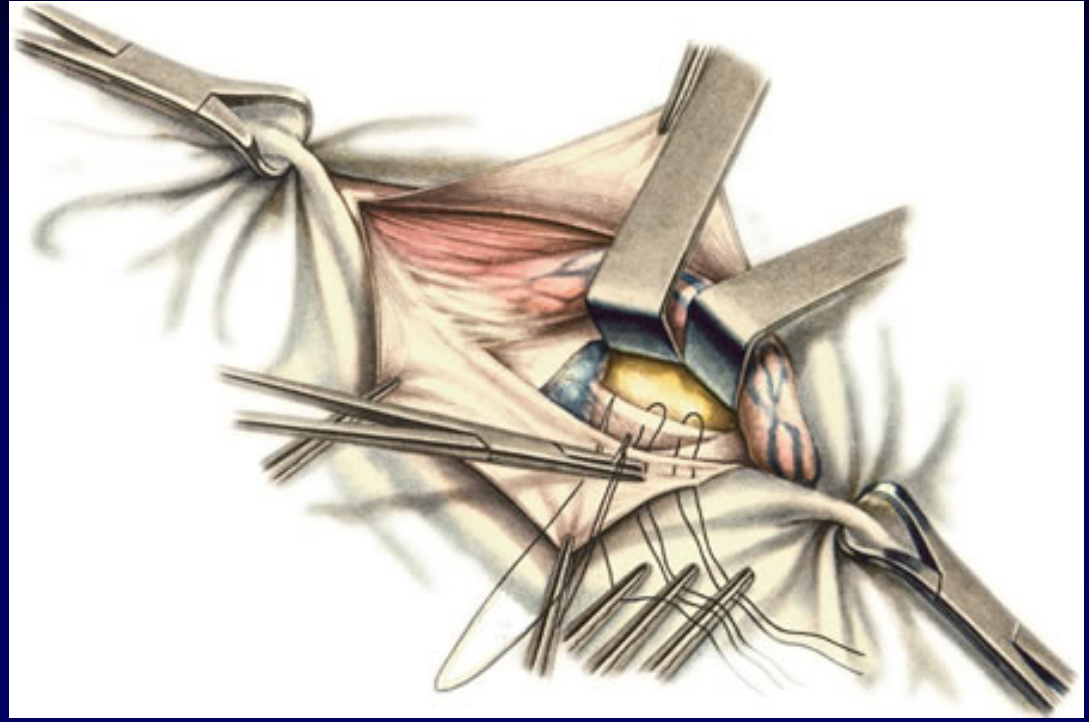
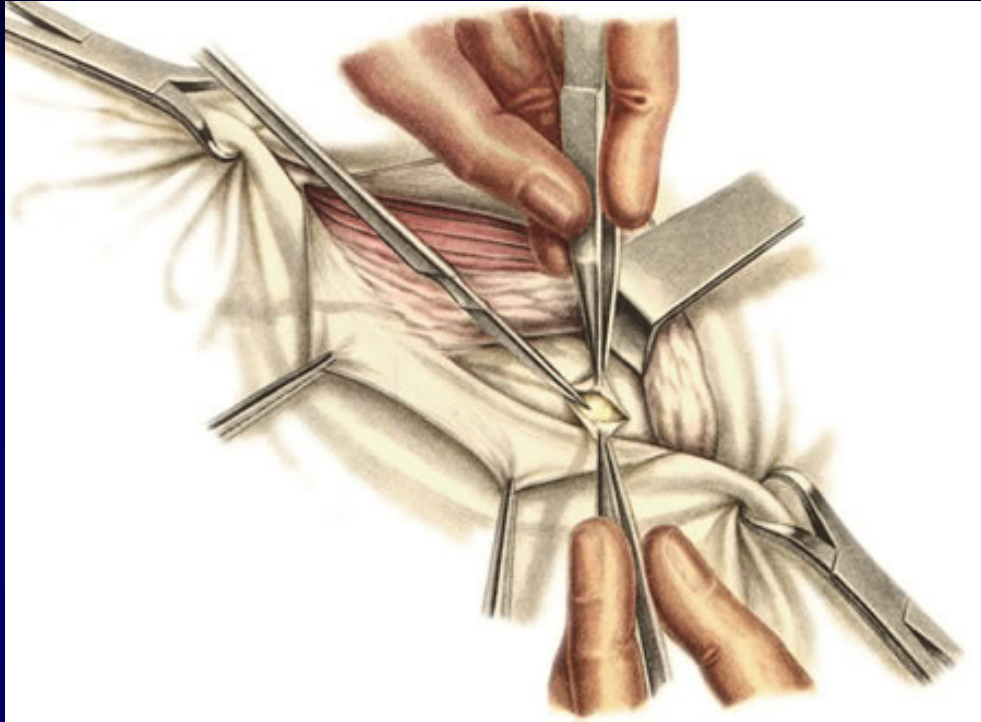
Femoral Hernia Repair

Bassini procedure



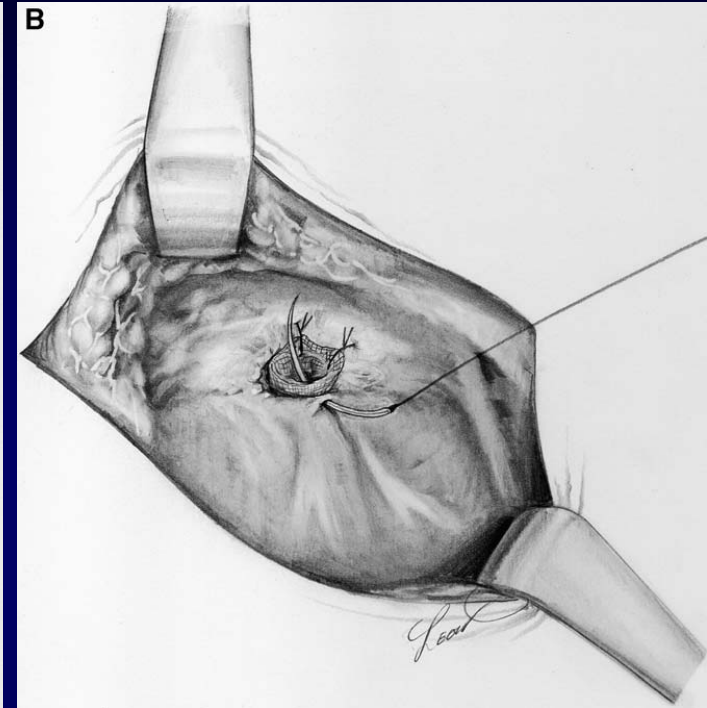
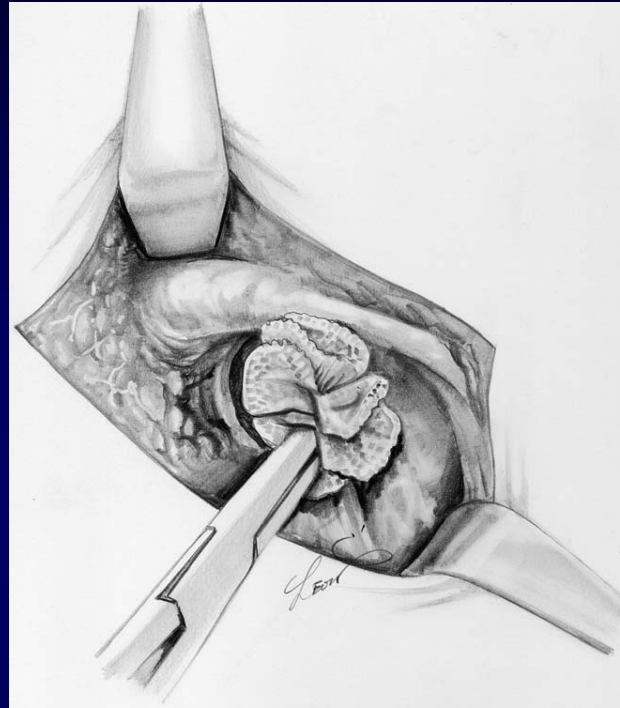
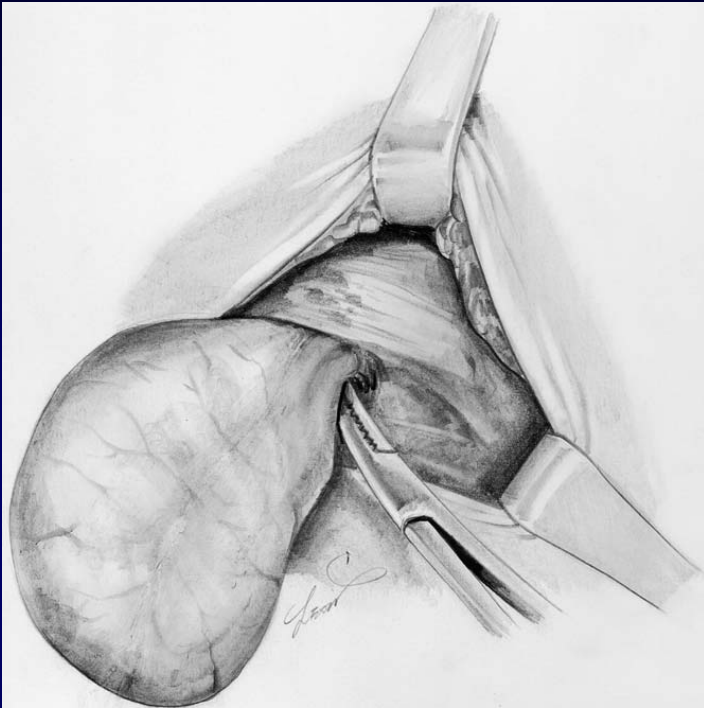
- Approximation of conjoint tendon and Cooper ligament
- and more superficial suture – approximation of Poupart and Cooper ligaments

Ruggi procedure

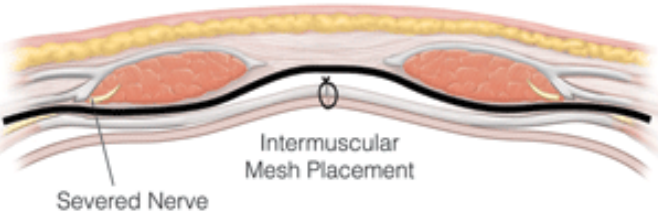
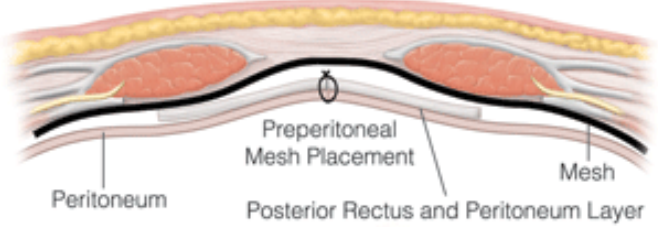
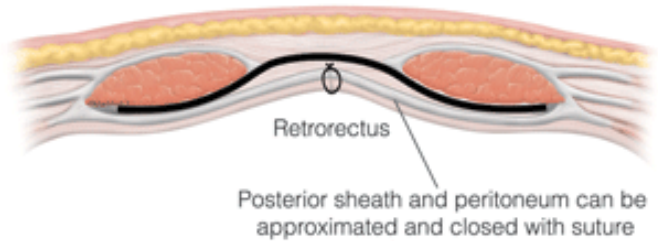
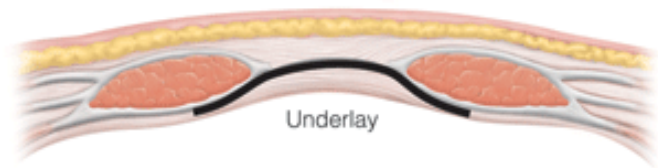
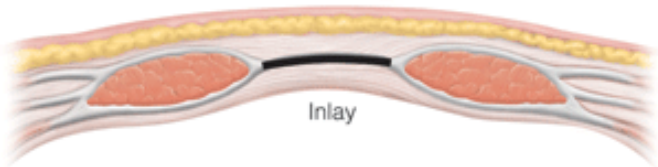
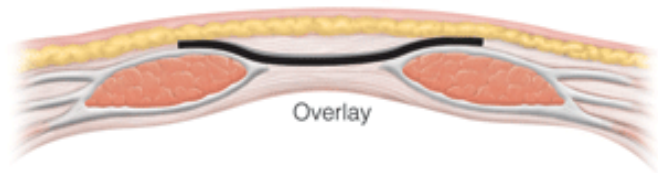


- inguinal approach
- approximation of Poupart and Cooper ligaments

Femoral hernia repair: Mesh plug

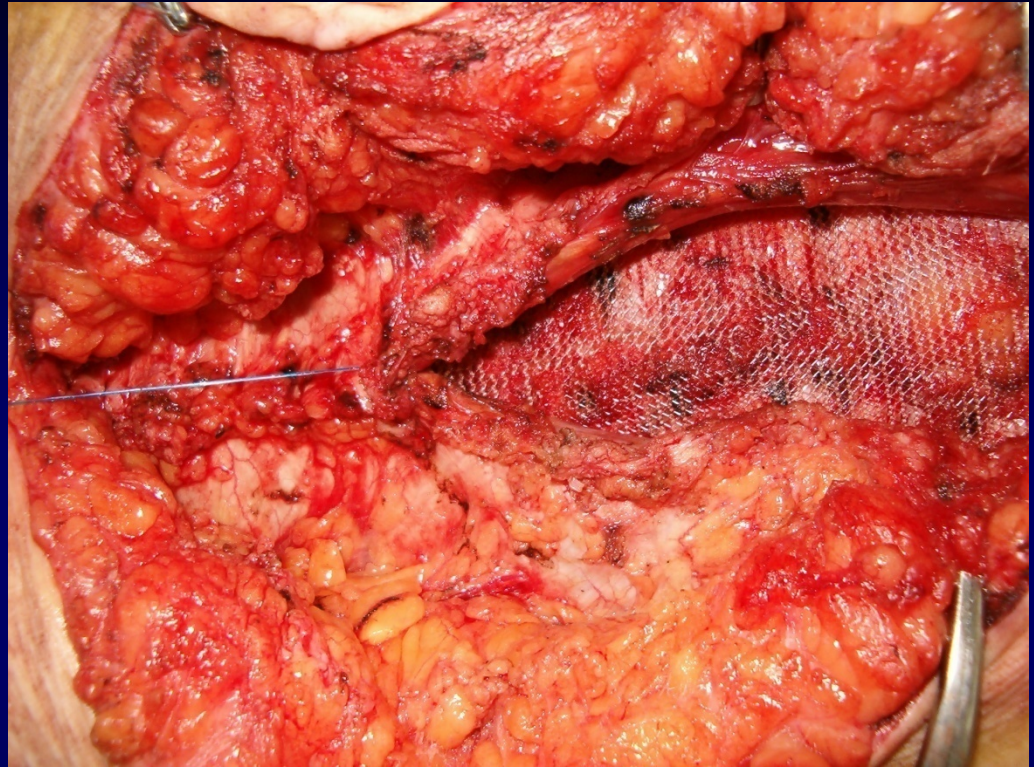
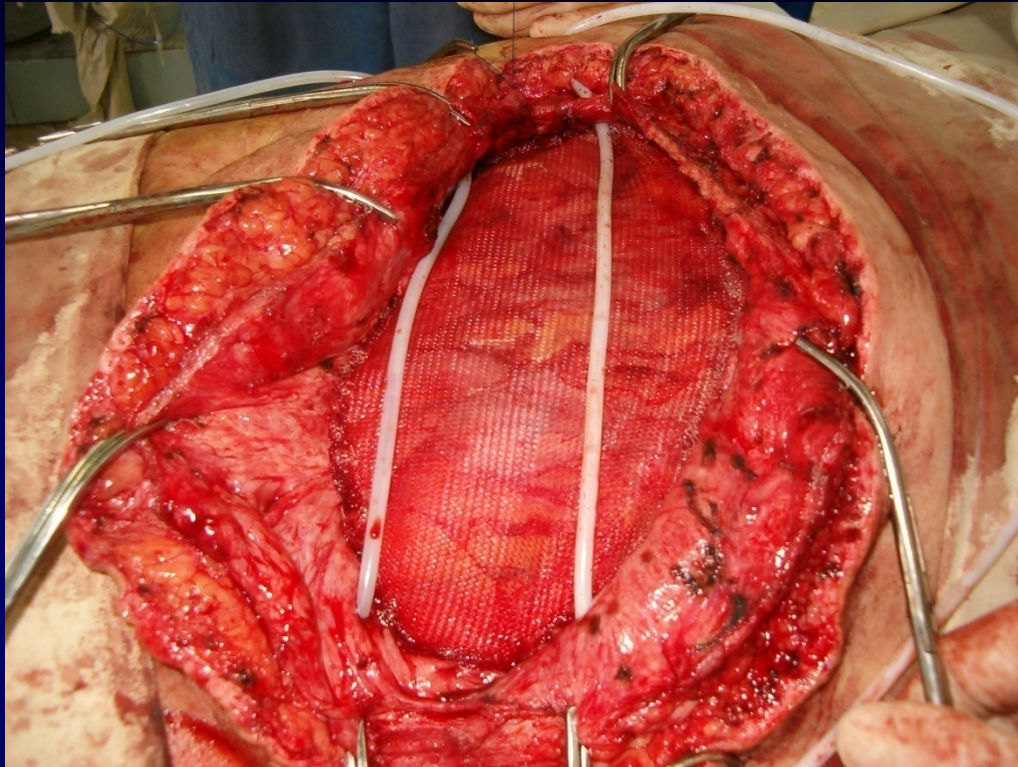


1. The hernia sac is dissected gently with complete hemostasis to the femoral orifice.
2. The plug is inserted into the femoral canal through the femoral orifice.
3. The plug is fixed with absorbable interrupted sutures to the inguinal ligament , the lacunar ligament and the pectineal fascia (B).

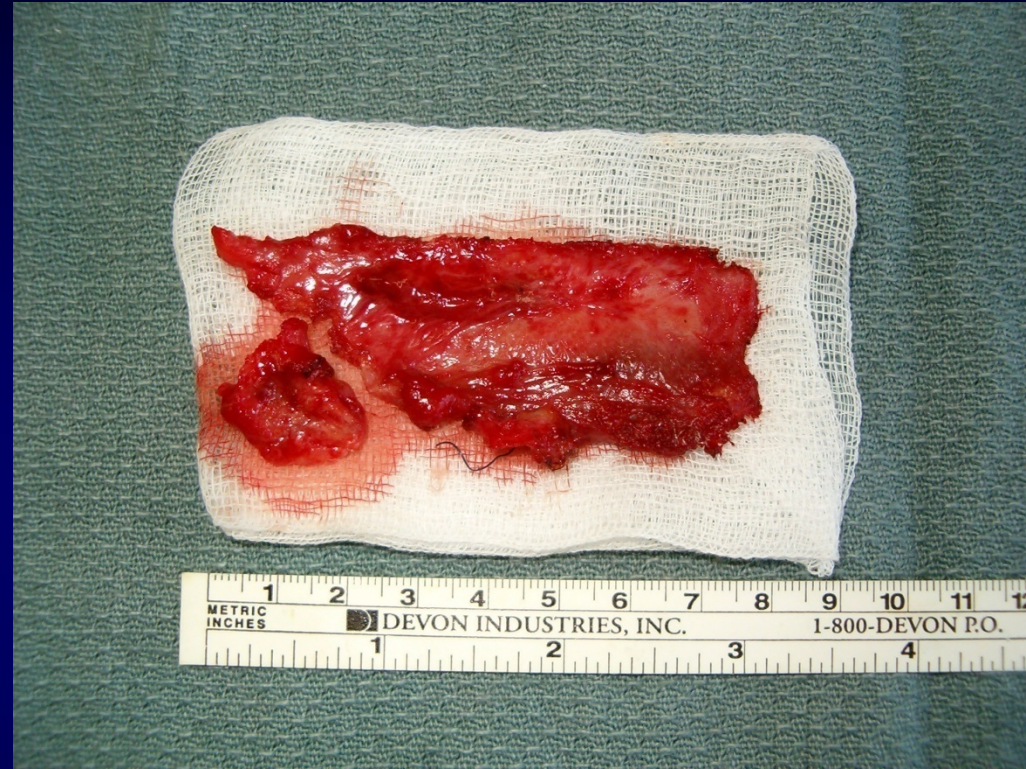
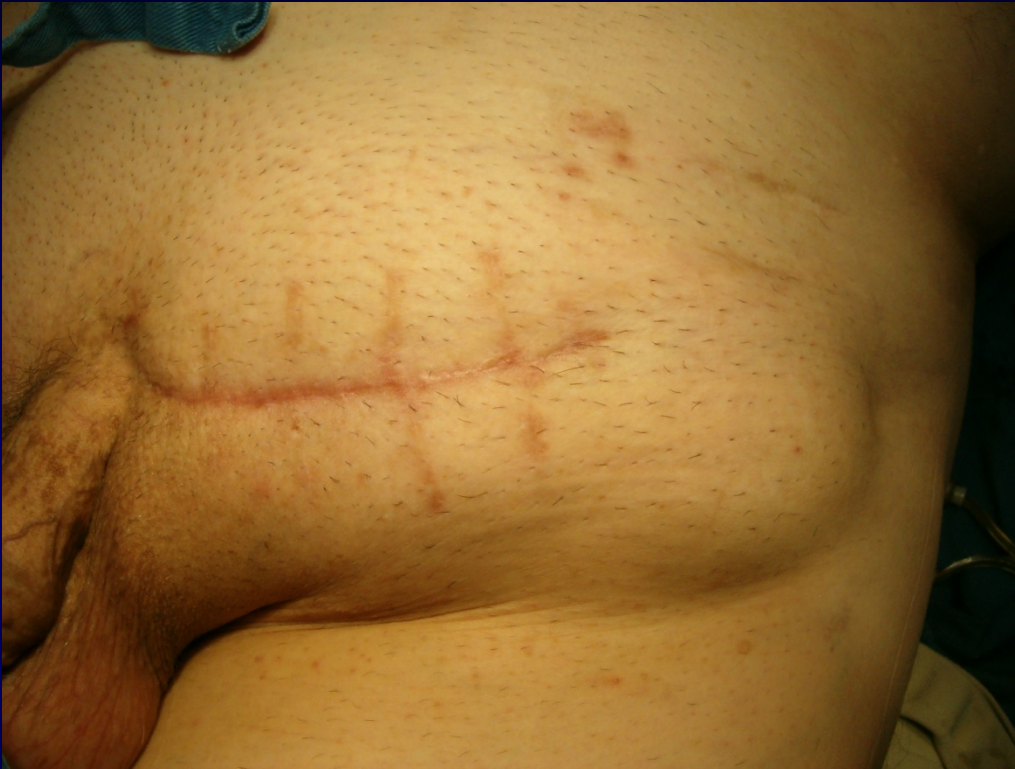

Incisional Hernia Repair: Positions for Placement of a Prosthesis

Incision Hernia: Rives procedure

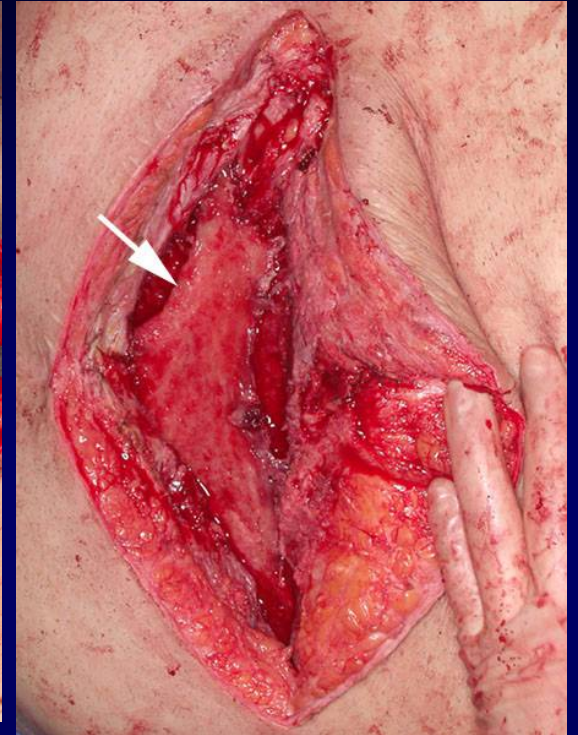
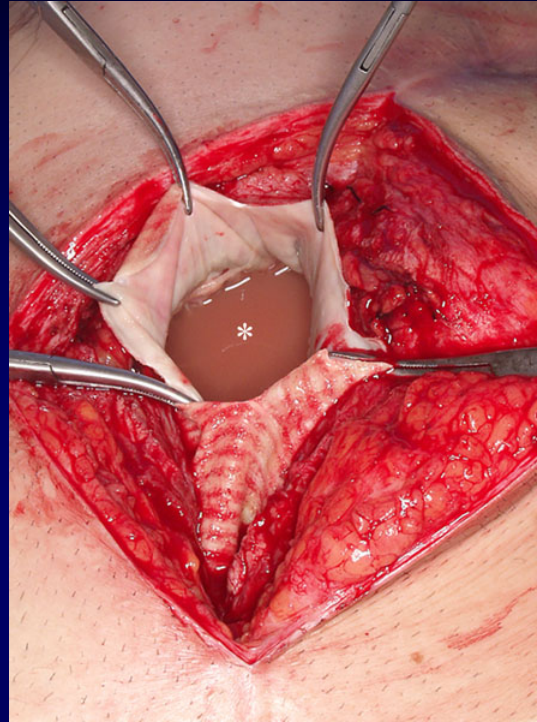
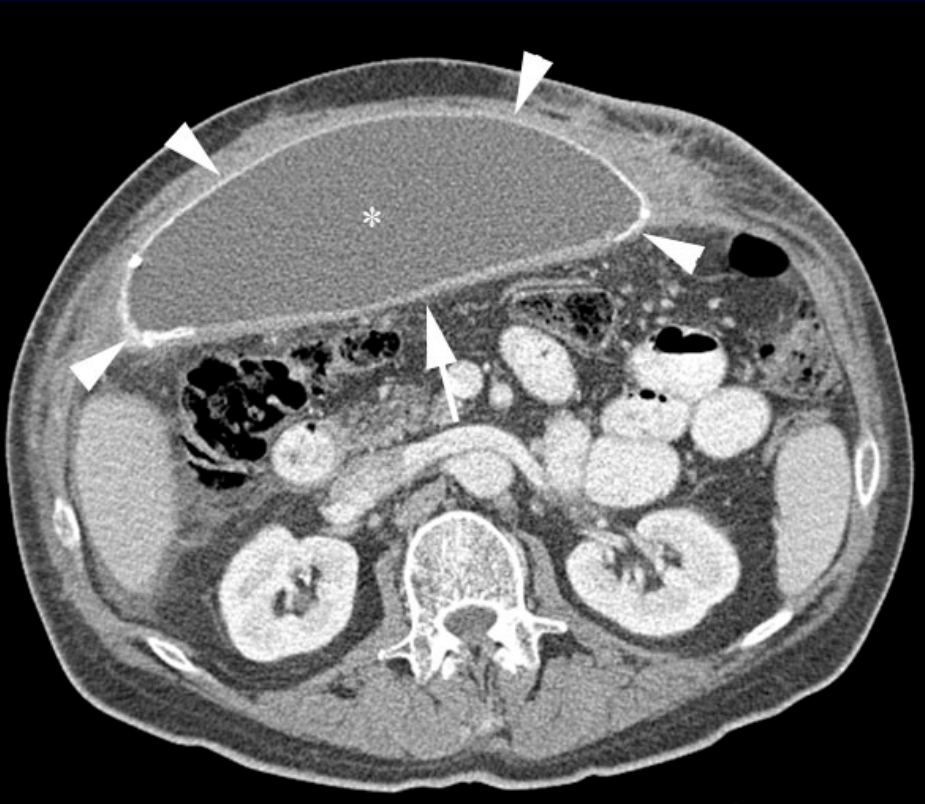


Infection



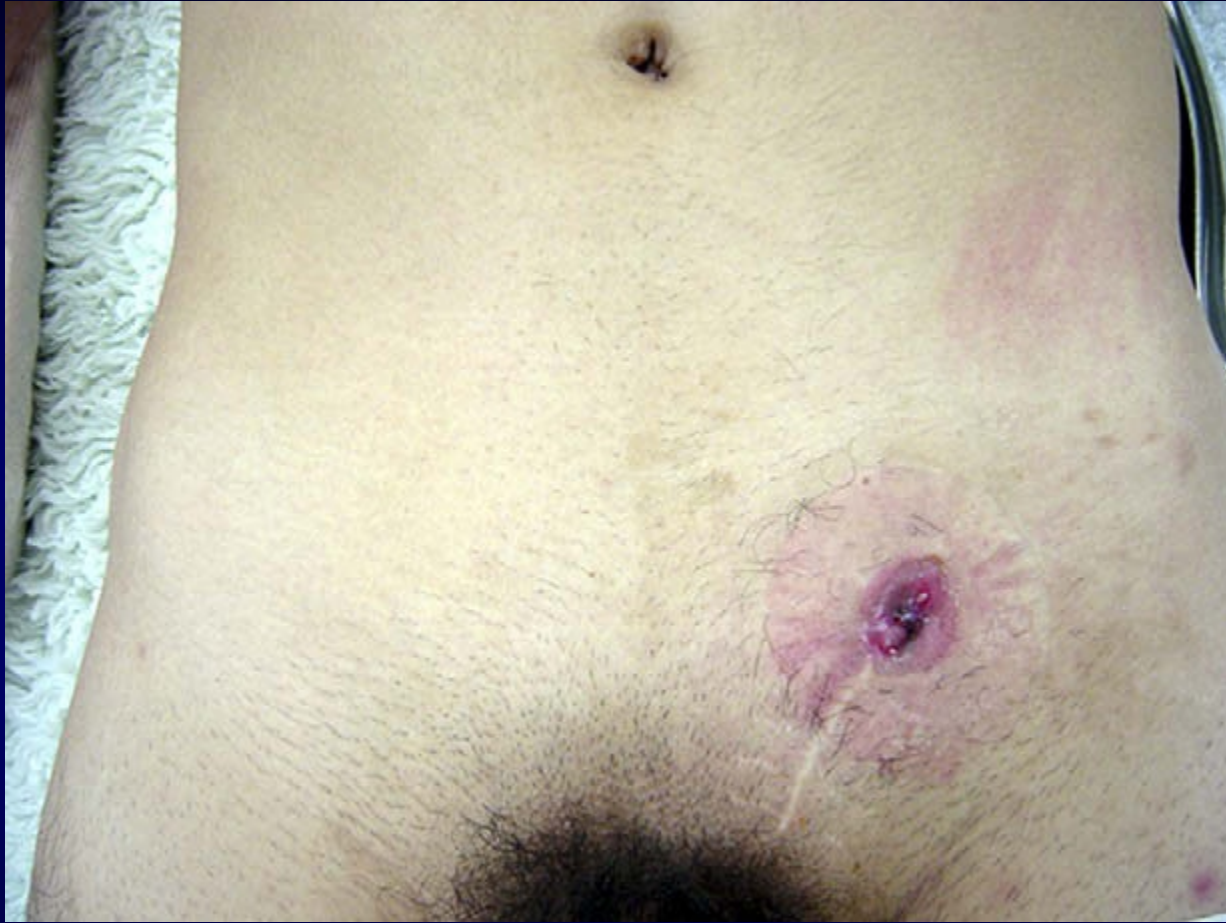Infection is the most serious complication of mesh hernia repairs occurring in up to 5 percent of patients. Fluid collections can become infected as well as the mesh material.

Postoperative Seroma Deep to Mesh

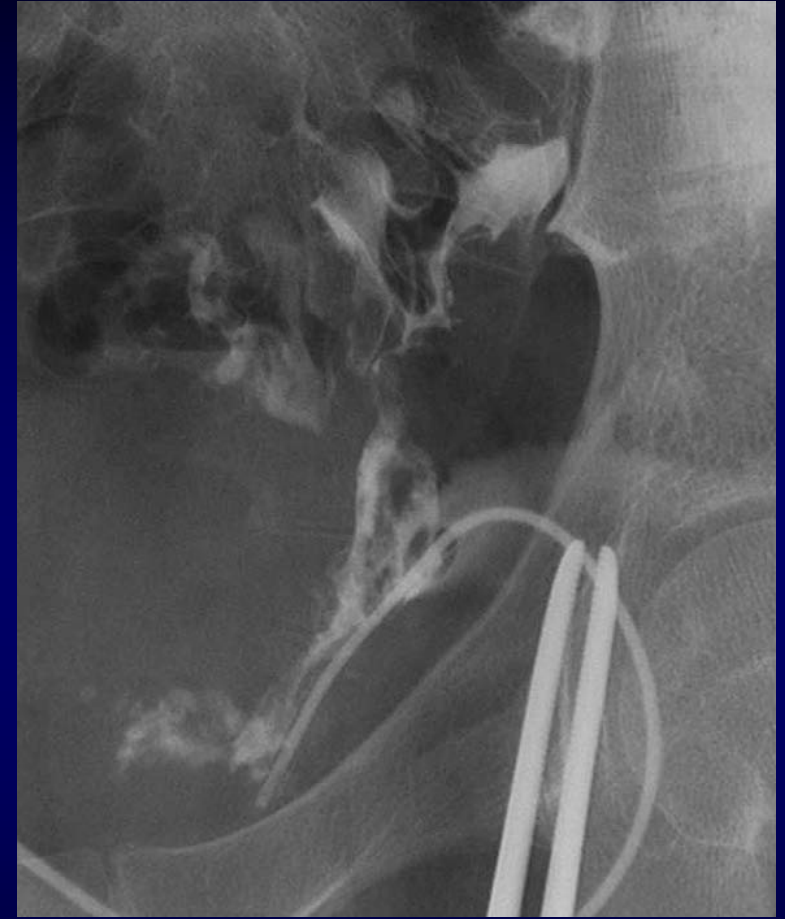

Initial treatment is with intravenous antibiotics. Often drainage of the infection is required with removal of the mesh material required in some cases. Infection is a major risk factor for hernia recurrence.

Colocutaneous fistula



A yellow-green discharge was observed at the lateral edge of the previous operative scar. Erythema of the skin is located around the wound.



Mesh plug and sigmoid colon were visible with the flow of contrast material.

